

An Update on Thyroid Disease

Elizabeth Buschur, MD
Assistant Professor of Medicine
Department of Internal Medicine
Division of Endocrinology, Diabetes & Metabolism
The Ohio State University Wexner Medical Center

Disclosures

- None

Outline

- Laboratory data
- Screening for thyroid dysfunction
- Hypothyroidism
- Hyperthyroidism
- Postpartum thyroiditis
- Thyroid nodules and cancer

Thyroid function

Thyroid Status	Serum TSH	Serum free T4	Serum free T3
Primary hypothyroidism	Elevated	Low	Normal or low
Subclinical hypothyroidism	Elevated	Normal	Normal
Euthyroid	Normal	Normal	Normal
Hyperthyroidism	Low	High or normal	High
Subclinical hyperthyroidism	Low	Normal	Normal

Adapted from ACOG Practice Bulletin 148. Thyroid Disease in Pregnancy. 2015.

Screening for thyroid dysfunction

- Universal screening not recommended

Screening for hypothyroidism

- Screen those at risk for hypothyroidism:
 - personal history of autoimmune disease (T1DM or other)
 - family history of thyroid disease
 - history of neck radiation
 - history of thyroid surgery
 - Consideration for age ≥ 60 years

Garber JR, Cobin RH, Gharib et al. Clinical practice guidelines for hypothyroidism in adults: cosponsored by the American Association of Clinical Endocrinologists and the American Thyroid Association. *Thyroid*. 2012;22(12):1200.

Hypothyroidism: etiology

- More common in women than in men
- 5% of the population
 - 0.1-2% overt hypothyroidism
 - 4.3% subclinical hypothyroidism

Hypothyroidism: etiology

- Most common cause worldwide is iodine deficiency
- Most common cause in US is autoimmune (Hashimoto's thyroiditis)
- Post-operative (thyroidectomy)
- Post-ablative (RAIA for treatment of hyperthyroidism)

Less common causes of hypothyroidism

- Thyroiditis
- Pituitary dysfunction (secondary hypothyroidism)
- Hypothalamic dysfunction (tertiary hypothyroidism)
- Medications: methimazole, propylthiouracil, lithium, potassium iodide, Lugol's solution

Hypothyroidism: signs & symptoms

- Fatigue
- Cold intolerance
- Weight gain
- Cool or dry skin
- Hair loss
- Brittle nails
- Delayed relaxation of DTRs
- Bradycardia

Hypothyroidism: diagnosis

- Best test is TSH
- If normal and high suspicion of hypothyroidism, also check free T4

Hypothyroidism: diagnosis

	TSH	Free T4
Subclinical hypothyroidism	High	Normal
Primary (overt) hypothyroidism	High	Low
Secondary (central) hypothyroidism	Low or normal	Low

Management of hypothyroidism

- Usually treatment is life-long
- Levothyroxine (T4) preferred over other thyroid hormone replacement options
 - Long half life
 - Once daily oral dosing
 - Take on an empty stomach apart from other medications and food
 - Generics available

Management: starting dose

- Young and middle aged healthy adults: start at predicted final dose
- Starting dose: 1.6-1.8 mcg/kg/day levothyroxine
- Older adults or adults with history of CAD or arrhythmia: “start low and go slow”
- Goal: normalization of TSH and resolution of patient’s symptoms

Monitoring T4 therapy

- Repeat TSH 4-6 weeks after starting levothyroxine
- TSH goal 0.5-3.5 or 4 mIU/L uIU/mL in the nonpregnant adult
 - Consider higher TSH goal for patients >70
- TSH goal for pregnant woman is within trimester-specific reference range

Hypothyroidism: monitoring

- Check TSH annually if stable
- Check TSH sooner if:
 - Any symptoms of over- or under-replacement
 - More than 10% change in body weight
 - Change in estrogen status (starting or discontinuation of OCP or HRT, postpartum, pregnancy, etc) or androgen status (starting/stopping testosterone replacement, etc)

Case 1

40 year old woman previously healthy presents with fatigue x 4 months. + dry hair and brittle nails.

TSH 12 (0.55-4.78 uIU/L), free T4 0.7 (0.89-1.76 ng/dL).

What is the next best step?

- A) Repeat labs in 3 months.
- B) Start levothyroxine 100 mcg daily.
- C) Start levothyroxine 25 mcg daily.
- D) Order a thyroid ultrasound.

Answer B

- Start levothyroxine 100 mcg daily
- Assess dose adequacy with repeat TSH in 4-6 weeks with goal of normalization of TSH and resolution of symptoms

Subclinical hypothyroidism

- Elevated TSH and normal T4
- Most have TSH <10 uIU/mL
- Prevalence 4-15%
- Many have positive anti-TPO Ab
- Most patients are asymptomatic
- Some have vague symptoms suggestive of hypothyroidism

JCEM. 2002;87(2):489

To treat or not?

- Most groups recommend treatment if TSH ≥ 10 uIU/mL (even if T4 is normal)
- Treatment of those with TSH 4.5-10 uIU/mL is controversial
- For preconception and during pregnancy, recommend treatment with goal TSH (<2.5 or 3 uIU/mL depending on preconception or trimester of pregnancy)

Hyperthyroidism: etiology

- 5 times more common in women than men
- Prevalence is 1.3% overall
 - 4-5% in older women (>50 years)
- More common in smokers
- Graves' disease is more often in young adults
- Toxic multinodular goiter is more common in older adults

Hyperthyroidism: causes

- Graves' disease
- Toxic adenoma and toxic multinodular goiter
- Thyroiditis
- Iodine induced hyperthyroidism
- Trophoblastic disease and germ cell tumors
- TSH-mediated hyperthyroidism
- Factitious ingestion of thyroid hormone

Hyperthyroidism: diagnosis

	TSH	Free T4	Total T3
Subclinical hyperthyroidism	Low	Normal	Normal
Overt hyperthyroidism	Low or undetectable	High or rarely normal	Normal or high
Central hyperthyroidism	Normal or high	High	High

Hyperthyroidism: signs & symptoms

- Fatigue
- Weight loss
- Anxiety
- Tachycardia
- Increased sweating
- Goiter
- Irregular menses
- Tremor
- Hyperdefecation
- Heat intolerance
- Eye findings

Hyperthyroidism: determining etiology

- Thyrotropin receptor antibody (TRAb or TSI)
- Radioactive iodine uptake and scan
- Thyroid blood flow on US

Hyperthyroidism: management

- Antithyroid medications (thionamides):
 - Methimazole
 - Propylthiouracil (PTU)
- Beta blockers
- Radioactive iodine ablation (RAIA)
- Thyroidectomy

Side effects of thionamides

- Agranulocytosis is rare: 0.1-0.5% prevalence
- Hepatotoxicity is rare: more common with PTU (1:10,000) than methimazole

Hyperthyroidism: monitoring

- Check labs every 4-6 weeks: TSH, free T4, and total T3
- CBC and liver panel at baseline and periodically
- Typically treat with anti-thyroid medication for 12-18 months

Definitive treatment

- RAI and surgery are the only definitive treatments for hyperthyroidism
- Often result in permanent hypothyroidism

Subclinical hyperthyroidism

- TSH low (<0.05 uIU/mL) but normal T4 and T3
- Prevalence varies 0.7-12.4%
- Most common cause is exogenous thyroid hormone
- Next most common cause is autonomously functioning thyroid adenoma or multinodular goiter

JCEM. 2002;87(2):489

To treat or not?

- Controversial
- Some studies show subclinical hyperthyroidism associated with low bone density
- Increased risk for atrial fibrillation and coronary heart disease events

Subclinical hyperthyroidism: treatment

- If TSH <0.1 uIU/mL, treat underlying cause
- If TSH 0.1-0.5 uIU/mL, consider treatment if low bone density, postmenopausal, age >65 , known heart disease or risk for arrhythmia

Surks et al. Subclinical thyroid disease: scientific review and guidelines for diagnosis and management. JAMA. 2004;291(2):228. 2016 American Thyroid Association Guidelines for Diagnosis and Management of Hyperthyroidism and Other Causes of Thyrotoxicosis. Thyroid. 2016;26(10):1343-1421.

Thyroiditis

- Painless thyroiditis:
 - Drugs: lithium, interferon- α , tyrosine kinase inhibitor therapy, amiodarone
 - Postpartum thyroiditis
- Subacute thyroiditis: viral infection, fever and thyroid pain

Postpartum thyroiditis

- Hyperthyroidism, hypothyroidism, and/or hyperthyroidism followed by hypothyroidism in the first year postpartum in women without thyroid disease history
- Often antibody positive
- Prevalence varies geographically
- Usually transient

Progression to hypothyroidism

- Women with a prior history of postpartum thyroiditis have a high risk of developing permanent hypothyroidism 5-10 years after the episode
- Recommend checking TSH annually

DeGroot et al 2012 JCEM 97: 2543-65

Thyroid nodules

Epidemiology of thyroid nodules

- Common disorder
- More frequent in women
- Increase in frequency with age
- More common in areas of low iodine intake

Mazzaferri. N Engl J Med. 1993 Feb 25;328(8):553-9

Management of thyroid nodules

- 2015 American Thyroid Association (ATA) Management Guidelines for Adult patients with Thyroid Nodules and Differentiated Thyroid Cancer

Case 2

- 35 year old woman is found to have a goiter. She is found to have a 1.5 x 1 x 0.9 cm hypoechoic thyroid nodule on thyroid ultrasound. TSH is 0.01 mIU/L (low).

What is the next best step?

- A. Biopsy of thyroid nodule
- B. Thyroid uptake and scan
- C. Thyroidectomy
- D. Repeat ultrasound in 6 months

Answer- B

- Measure serum TSH in the initial evaluation of a patient with a thyroid nodule
- If the serum TSH is suppressed (low), a radionuclide thyroid scan should be performed using either technetium ^{99m}Tc pertechnetate or ^{123}I to determine if nodule is “hot” or “cold”

Symptoms of a thyroid nodule

- Usually NONE!!
- Occasionally painful, quick onset (cyst)
- Difficulty swallowing
- Hoarseness OR change in voice
- Shortness of breath (or difficulty swallowing) usually while supine OR hands raised over head
- Choking sensation
- Symptoms of hypo- or hyperthyroidism

Risk of thyroid cancer

- Most thyroid cancers are:
 - slow-growing, well differentiated & have overall good prognosis
- Rule out thyroid cancer with:
 - Nodules ≥ 1 cm in size with high or intermediate suspicion sonographic pattern
 - Nodules ≥ 1.5 cm in size with low suspicion sonographic pattern
 - Nodules < 1 cm in size if high risk history

Risk factors for thyroid cancer

- History of thyroid cancer in first degree relative
- Head and neck irradiation
- Whole body irradiation for BMT

2015 American Thyroid Association (ATA) Management Guidelines for Adult patients with Thyroid Nodules and Differentiated Thyroid Cancer

Risk factors for thyroid cancer

- History of thyroid cancer in first degree relative
- Head and neck irradiation
- Whole body irradiation for BMT
- Prior hemithyroidectomy with discovery of thyroid cancer
- ^{18}F FDG avidity on PET scanning
- MEN2/FMTC-associated RET protooncogene mutation

2015 American Thyroid Association (ATA) Management Guidelines for Adult patients with Thyroid Nodules and Differentiated Thyroid Cancer

Clinical findings concerning for cancer

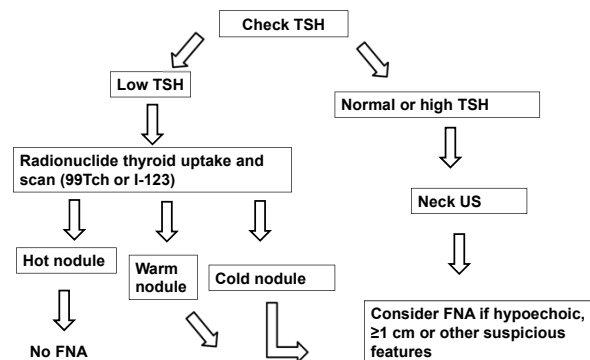
- Rapid growth of nodule
- Hoarseness or dysphagia
- Vocal cord paralysis
- Ipsilateral cervical node enlargement
- Fixation

Management of a Thyroid Nodule. From Pearls of Excellence from ACOG. Santoro N. 1/1/10, revised 3/15.

Suspicious ultrasound features

- Hypoechoic
- Irregular borders
- Microcalcifications
- Infiltrative margins
- Taller than wide shape on transverse view
- Suspicious cervical lymph nodes
- Vascularity
- PET positive thyroid nodules >1 cm

If you palpate a nodule



What about multiple nodules?

- Multinodular goiter
- Multiple nodules do not rule out malignancy
- Need to evaluate US characteristics of each nodule to decide which should be biopsied

Case 3

- A 30 yo woman presents for routine health maintenance exam.
- Exam is notable for tachycardia (HR 110 bpm) and enlarged thyroid with two palpable nodules about 1 cm each.

What is the next best step?

- A) Check TSH
- B) Radioactive iodine uptake and scan
- C) Obtain a detailed family history
- D) Counsel her on reducing caffeine intake

Answer - A

- Check TSH level in all patients with a thyroid nodule
- Determine next steps depending on TSH result

Conclusion

- TSH is the best screening test for thyroid dysfunction

Conclusion

- TSH is the best screening test for thyroid dysfunction
- Treat hypothyroidism with levothyroxine

Conclusion

- **TSH is the best screening test for thyroid dysfunction**
- **Treat hypothyroidism with levothyroxine**
- **Etiology of hyperthyroidism should be determined for best treatment**

Conclusion

- **TSH is the best screening test for thyroid dysfunction**
- **Treat hypothyroidism with levothyroxine**
- **Etiology of hyperthyroidism should be determined for best treatment**
- **Any palpable nodule should be evaluated with a TSH and ultrasound**