

Guidelines for the Sidelines: Common Musculoskeletal Injuries in Sports

Shoulder Dislocations and AC joint injuries

Timothy L. Miller, MD, FAAOS
Assistant Professor of Orthopaedics
and Sports Medicine
Team Physician
Ohio State University Athletics, Capital University
and Granville High School
The Ohio State University Wexner Medical Center



Guidelines for the Sidelines

Common Musculoskeletal Injuries in Sports

- Acromioclavicular Joint Injuries
- Glenohumeral Joint Dislocations
- Patellar Dislocations
- ACL Tears
- Leg Pain in Running Athletes



AC Joint Injuries

Anatomy

Static stabilizers

AC ligaments

-Anteroposterior stability

CC ligaments

-Conoid, Trapezoid

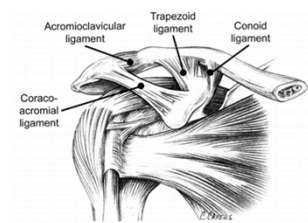
-Superior/ Inferior stability

CA ligament

AC joint capsule

Dynamic stabilizers

Deltoid, trapezius muscles

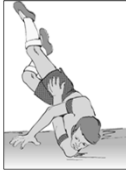

AC Joint Injuries

Mechanism of Injury

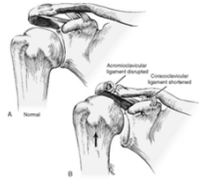
Direct

- Fall onto lateral aspect of Shoulder
- Inferior displacement of the Scapula
- AC and CC ligament disruption



Indirect

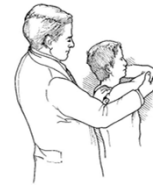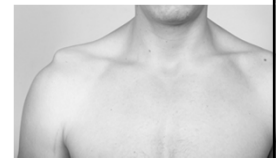
- Fall onto elbow
- Proximal humerus driven into acromion
- Often spares the CC ligaments



AC Joint Injuries

Physical Examination

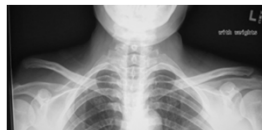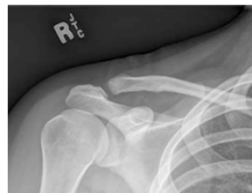- Inspection: Visible deformity
- Deformity reducible with proximal force on humerus
- Triad
 - 1) Direct TTP
 - 2) Pain with cross body adduction
 - 3) Relief with Lidocaine injection



AC Joint Injuries

Radiographic Evaluation

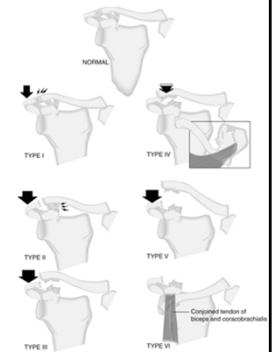
- Complete Shoulder Series
 - AP/ Grashey- overpenetrates AC joint.
 - Scapular Y
 - Axillary
 - A/P translation (Type IV)
- Zanca View
 - 10 deg cephalad tilt, 50% penetration
- Stress View
 - Type II vs Type III



AC Joint Injuries

Grading of Severity

- Radiographic Evaluation
- Rockwood Classification
 - Types I-VI
 - (Rockwood et al. 1984)
- Sequential Injury
 - AC ligaments
 - CC ligaments
 - Deltotrapezial Fascia



AC Joint Injuries

Treatment Recommendations

Initial Treatment:

- Sling, ice, NSAID's, physical therapy
- Consider Lido/Corticosteroid Injection

Definitive Treatment

- Nonoperative

Type I-II (incomplete AC joint disruption)

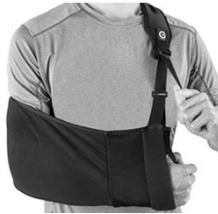Type III controversial

- Surgery for elite throwing athletes.
- Otherwise return to play in 2-6 weeks

- Operative

Type IV-VI (complete AC joint disruption)

(Bishop et al., Sports Med Arth, 2006)



AC Joint Injuries

Type III Treatment Algorithm

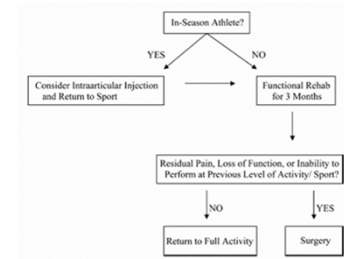
Surgery may be indicated for:

- Residual Instability
- Decreased Strength
- AC Joint Pain

Deciding Factors for Type III's

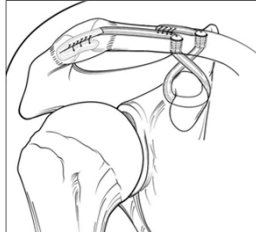
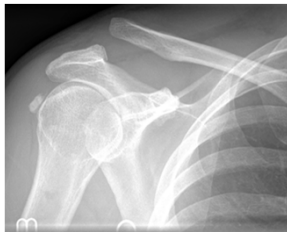- Type of Sport
- Timing of Injury relative to athletic season
- Throwing demands
- Hand dominance

Beitzel et al. Arthroscopy, 2013.



AC Joint Injuries

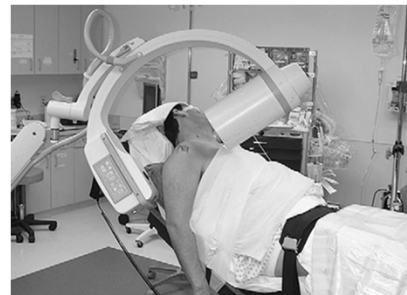Surgical Reconstruction Technique



- Division II collegiate quarterback with Grade III AC joint dislocation
- Initially treated with PT/ rehab and injections.
- Underwent AC and CC ligament reconstruction with hamstring allograft

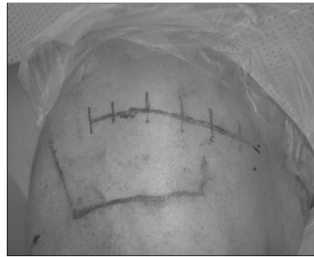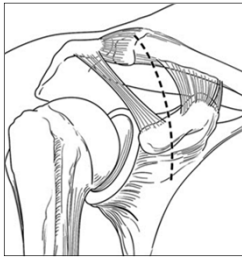
AC Joint Injuries

Surgical Technique- Beach Chair Position



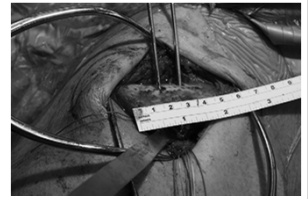
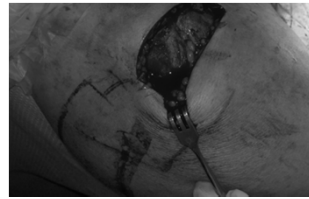
AC Joint Injuries

Surgical Technique- Saber Approach



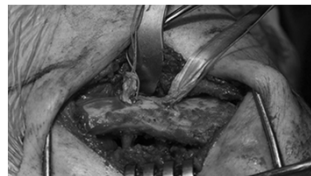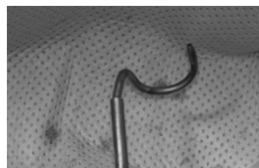
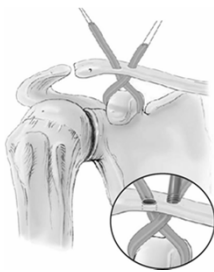
AC Joint Injuries

Surgical Technique



AC Joint Injuries

Surgical Technique



Glenohumeral Joint Dislocations

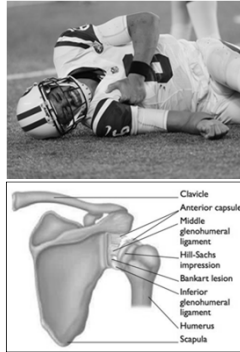


Glenohumeral Joint Dislocations

History

- Anterior is most common direction.
- Due to fall or hit with the shoulder abducted and externally rotated.
- May be recurrent due to ligamentous laxity or glenoid bone loss from previous dislocations.
- Injures the AIGHL.

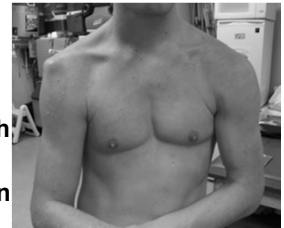Griffin et al., Clin Sports Med, 2013.



Glenohumeral Joint Dislocations

Physical Exam

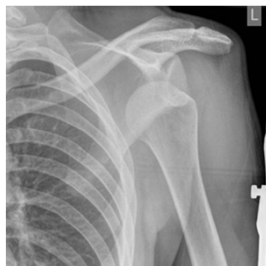- Pain with ROM
- Arm held in adduction and internal rotation
- Asymmetric contour with prominent humeral head
- Block to external rotation
- Loss of axillary nerve sensation.
- Hegedus et al., BJSM, 2008.



Glenohumeral Joint Dislocations

Radiographic Evaluation

- Not required prior to reduction.
- Useful to rule out fracture
- Confirms anatomic reduction
- 3 Views:
 - Grashey
 - Scapular Y
 - Axillary or Equivalent!

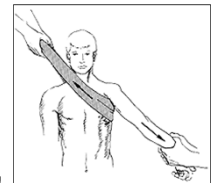


Glenohumeral Joint Dislocations

Initial Treatment

- Removal from game or practice
- Closed reduction on field/sideline or locker room
- Confirm neurovascular status!
- Sling immobilization
- Ice and NSAID's
- Begin PT/ rehab within 1 week.

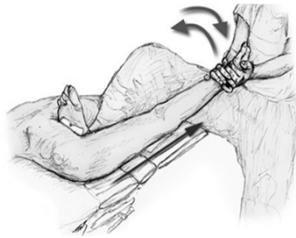
Kuhn et al., Sports Med Arth, 2006.
Owens et al., JAAOS, 2012.



Glenohumeral Joint Dislocations

Reduction Techniques

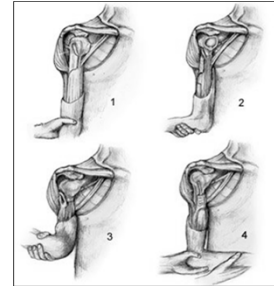
- *Hippocratic*
- *Kocher/ External Rotation*
- *Milch*
- *Stimson*
- *Traction/ Counter Traction*



Glenohumeral Joint Dislocations

Reduction Techniques

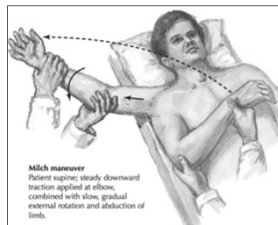
- *Hippocratic*
- *Kocher/ External Rotation*
- *Milch*
- *Stimson*
- *Traction/ Counter Traction*



Glenohumeral Joint Dislocations

Reduction Techniques

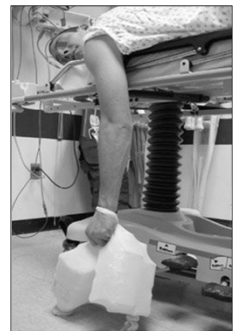- *Hippocratic*
- *Kocher/ External Rotation*
- *Milch*
- *Stimson*
- *Traction/ Counter Traction*



Glenohumeral Joint Dislocations

Reduction Techniques

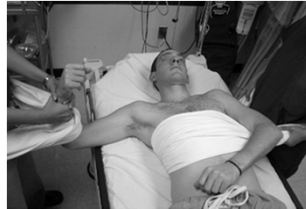- *Hippocratic*
- *Kocher/ External Rotation*
- *Milch*
- *Stimson*
- *Traction/ Counter Traction*



Glenohumeral Joint Dislocations

Reduction Techniques

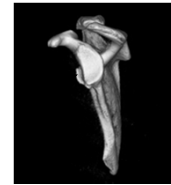
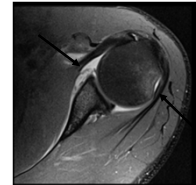
- Hippocratic
- Kocher/ External Rotation
- Milch
- Stimson
- *Traction/ Counter Traction*



Glenohumeral Joint Dislocations

Advanced Imaging

- MRI
 - Labral tears
 - Cartilage injury
 - Loose fragments
 - Rotator cuff injuries
- CT Scan
 - Glenoid bone loss
 - Hill-Sachs lesions

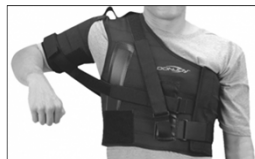

Ward et al. Clin Sports Med, 2013.

Glenohumeral Joint Dislocations

Decision Points

- Return to Play
 - Sport
 - Position
 - Bracing
 - Risk Factors
- Surgery vs Rehab
- Timing of Surgery
- Type of Procedure

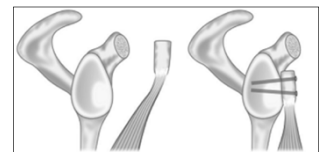
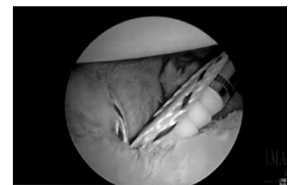


Owens et al., JAAOS, 2012.
Dickens et al, AJSM, 2014.

Glenohumeral Joint Dislocations

Surgical Options

- Bankart Repair/ Capsulorrhaphy
 - Arthroscopic
 - Open
- Latarjet Procedure



Brophy RH Clin Sports Med, 2013.
Owens et al. OJSM, 2015.

Shoulder Injuries in Athletes

Key Points

- Shoulder injuries are extremely common in contact sports.
(Football, wrestling, hockey, and lacrosse)
- AC sprains can be very painful but rarely require surgery.
- Type III AC injuries may require surgery in a throwing athlete's dominant shoulder.
- Closed reduction of a glenohumeral dislocation can be performed prior to obtaining radiographs.
- Always get post-reduction radiographs including an axillary view or equivalent. (Velpeau view or CT scan)
- Athletes can return to play in the same season following glenohumeral dislocation or AC joint sprain.

Guidelines for the Sidelines: Common Musculoskeletal Injuries in Sports

Knee Injuries

Timothy L. Miller, MD, FAAOS
Assistant Professor of Orthopaedics
and Sports Medicine
Team Physician
Ohio State University Athletics, Capital University
and Granville High School
The Ohio State University Wexner Medical Center

Patellar Dislocations

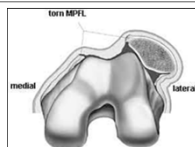
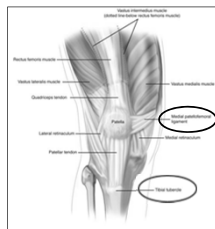
Anatomy

Bone:

- Patella Height
- Depth of the Trochlea
- Tibial Tubercle Position

Soft tissues:

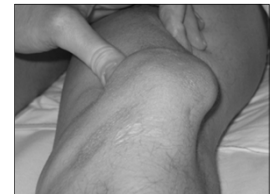- Medial Patellofemoral Ligament (MPFL)
- Lateral Patellar Retinaculum



Patellar Dislocations

Risk Factors

- Generalized Ligamentous Laxity
- Trochlear dysplasia
- Patella alta
- Previous traumatic dislocation
- Early age at 1st subluxation
- Lateral Tibial Tubercle (TT/TG Index >20mm)
- Excessive valgus alignment
- Decrease quadriceps function
- ↑ Q angle

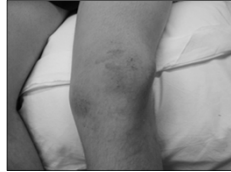


Redziniak et al., JBJS 2009.

Patellar Dislocations

Presentation

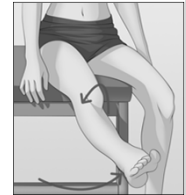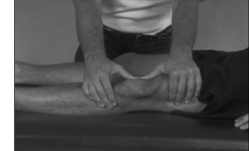- Acute anterior/ medial knee pain and swelling.
- Feeling of a pop or shift at the patella.
- Lateral patella deformity.
- “My knee (cap) dislocated.”
- May self-reduce.
- Difficulty extending knee.
- Difficulty bearing weight.
- History of prior patella instability episodes.



Patellar Dislocations

Physical Examination

- Deformity
- Neurovascular exam
- Able to bear weight?
- Swelling/ hemarthrosis (May develop over hours.)
- Medial sided tenderness
- Patellar apprehension
- Increased lateral patellar translation.
- Confirm cruciate and collateral ligaments are stable.
- Confirm extensor mechanism is intact.



Patellar Dislocations

Initial Sideline Treatment

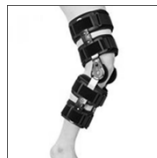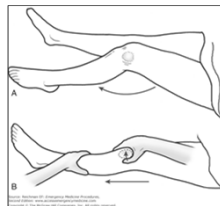
RICE it!

Reduction, Remove from play, and Rest

Ice, Immobilize with brace

Compression Wrap, Crutches, and Consider Aspiration

Elevate, ED for xrays

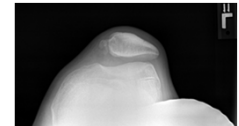
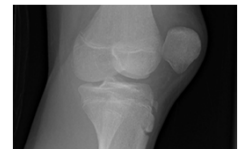

Patellar Dislocations

Imaging Evaluation

Radiographs:

- Direction of dislocation
- Rule out fracture or loose body
- Evaluate overall lower extremity alignment
- Trochlear dysplasia
- Supratrochlear spur
- Patella height

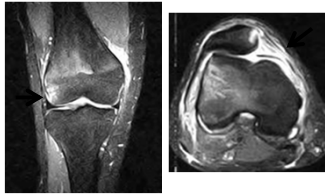


Patellar Dislocations

Imaging Evaluation

MRI Scan:

- Bone bruises at medial patella and lateral femoral condyle
- MPFL tear
- Cartilage injuries
- Loose fragments



Patellar Dislocations

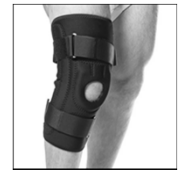Non Surgical Treatment

Non-Operative Treatment

- 1st line treatment
- Physical Therapy
 - Quad/ VMO Strengthening
- IT Band and Lateral retinaculum stretching
- Patellar Stabilization bracing
- Patellofemoral taping

50% recurrence rate

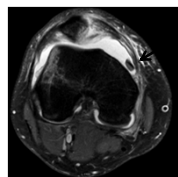
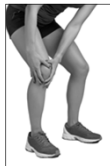- Most significant risk factor is previous instability episode.



Patellar Dislocations

Indications for Surgical Treatment

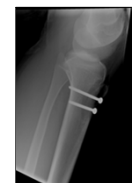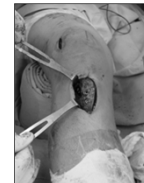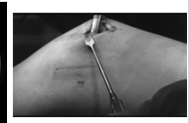
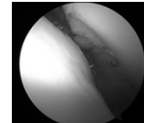
- Failed non-operative treatment
- Recurrent patellofemoral instability
- Incompetent medial checkrein ligaments (MPFL)
- Osteochondral fragments



Patellar Dislocations

Surgical Treatment Options

- Primary Medial Retinacular Repair
- MPFL Reconstruction (Auto or Allograft)
- Distal Realignment/ Tibial Tubercle Osteotomy



Patellar Dislocations

Return to Play Decision Making.

- Acute 1st time dislocation
 - Unlikely to return to play same day.
- Recurrent instability
 - Possible if braced and pain allows.
- Knee must be fully rehabilitated with physical therapy and bracing.
 - Full ROM
 - Near full quadriceps strength
- Surgery is commonly required for recurrent instability and for loose fragments.
- Time to return to sports after surgery
 - 3-6 months.

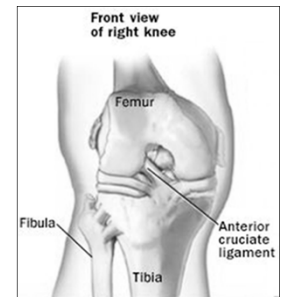


ACL Tears

Anatomy

The ACL takes origin on the lateral wall of the femoral notch and inserts onto the central, anterior portion of the tibial plateau

Two functional bundles – anteromedial (AM) and posterolateral (PL) have been described



ACL Tears

Ligament Function

The primary function:

- Prevent anterior translation of the tibia relative to the femur

Secondary functions include:

- Prevention of knee hyperextension
- Resisting varus/valgus angulation
 - Particularly if the collaterals are injured
- Resisting internal tibial rotation relative to the femur near extension

ACL Tears

Epidemiology

- The ACL is the most commonly reconstructed knee ligament – up to 200,000 per year in the US as of 2002
- Females are more commonly affected
 - ✓ 2-8 x risk of males
- Those involved in cutting and pivoting sports are at highest risk
- Downhill skiing also a high risk activity
- Approx 70-75% are noncontact injuries

ACL Tears

Presentation

- Noncontact, deceleration/ cutting move
- Feeling and/ or hearing a "Pop"
- Unable to continue playing or bear weight
- Immediate swelling



ACL Tears

Patient History

History of knee problems pre-injury?
Injury

- Mechanism – Contact?
- Pop?
- Swelling – Immediate? How large?
- Acute hemarthrosis in o/w healthy knee – think ACL

Post-injury

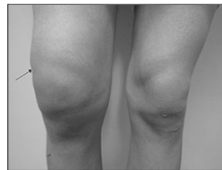
- Mechanical symptoms – locking, catching?
- Feelings of instability?

ACL Tears

Physical Examination

Complete lower extremity exam

- Strength, ROM, neurovascular, gait
- Beware of patella dislocation, can have similar clinical presentation



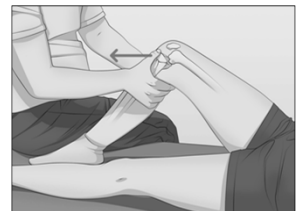Ligamentous Exam

- ACL-Specific tests
- PCL, MCL, LCL, PLC

ACL Tears

Anterior Drawer Test

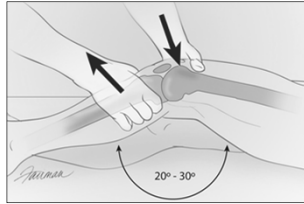
- Knee flexed 90 degrees
- Pull forward on the proximal tibia
- Always compare to uninjured knee.
- Not as sensitive as Lachman test
- Much more useful for posterior instability (PCL injury)



ACL Tears

Lachman Test

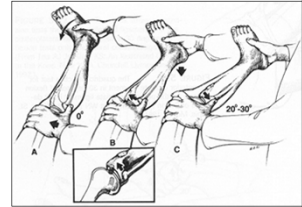
- Knee flexed 20-30°
- Hamstrings relaxed
- Stabilize femur, pull anteriorly on proximal tibia
- Evaluate Anterior Excursion / Endpoint
- Most sensitive exam for ACL tears



ACL Tears

Pivot Shift Test

- Knee extended, valgus
Internal rotation
- With flexion, subluxated tibia reduces
- Graded: 0-3 (none, glide, shift, clunk)
- Difficult to elicit if hamstring spasm while patient is awake

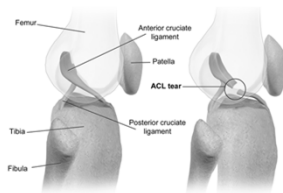


ACL Tears

Injury Mechanism

Contact Injuries:

- 25% of injuries
- Result from a direct blow to the knee or leg
- Concurrent injuries frequent



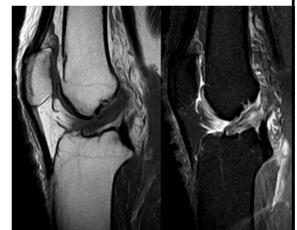
Author: BruceBlaus
(CC BY-SA 4.0)

ACL Tears

Injury Mechanism

Non-Contact Injuries:

- 75% of injuries
- No direct trauma to the knee
- Typically during deceleration move: stop, cut, or landing
- Many factors contribute



Author: Hellerhoff
CC BY-SA 3.0

ACL Tears

Non-Contact Injuries

Multiple proposed mechanisms

- Quadriceps contraction/decreased relative hamstring strength
- Axial Compression
- Knee abduction (valgus)
- All generally work to increase tibial internal rotation and anterior translation, loading the ACL beyond its capacity

ACL Tears

Risk Factors

Anatomic

- Decreased notch width
- Increased tibial slope
- Increased Q angle

Female gender

Biomechanical/neuromuscular

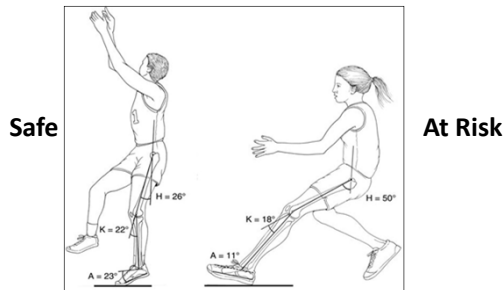
- Increased knee abduction (Valgus)
- Landing with decreased knee flexion and increased hip flexion
- Landing with foot dorsiflexed

Boden et al, JAAOS, 2010

Griffin et al, JAAOS 2000

ACL Tears

Risk Factors



Boden et al, JAAOS, 2010

Griffin et al, JAAOS 2000

ACL Tears

Associated Injuries

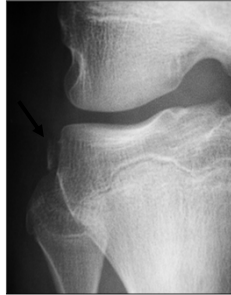
- **Bone bruises**
 - Lateral femoral condyle terminal sulcus
 - Posterior lateral tibial plateau
 - May have medial bruising as well
- **Meniscus tear**
 - 40% of index ACL injuries
 - Lateral meniscus more common in acute injuries
 - Medial meniscus in chronic injuries
- **MCL**
 - Common, usually grade 1 or 2

ACL Tears

Imaging Evaluation

Radiographs

- Critical to rule out other injuries (fractures/dislocations)
- May see tibial tubercle avulsions in the skeletally immature
- Second Fracture
 - Pathognomonic for ACL tear

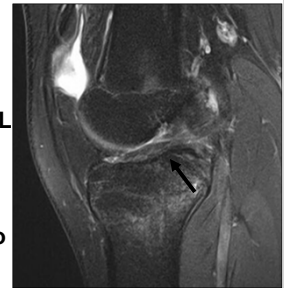


ACL Tears

Imaging Evaluation

MRI Scan:

- Most sensitive and specific test for evaluation of the ACL
- High T2 signal in intra-articular notch
- Discontinuity and inability to visualize remaining fibers

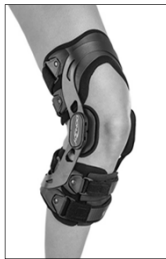

ACL Tears

Treatment Options

Non-Surgical Treatment:

- Includes PT and bracing
- Good option in some patients not wanting to return to cutting/pivoting sports
- Some "copers" may do well without an ACL in all activities
- Prolonged ACL deficiency is associated with increased risk of meniscus tear and osteoarthritis.



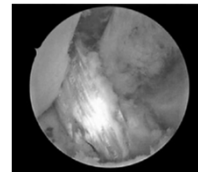
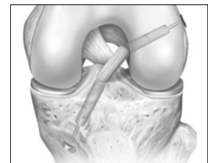Eastlack et al, MSSE, 1999
Oiestad et al, AJSM, 2009
Neyret et al, RCO, 1988

ACL Tears

Treatment Options

Surgical Treatment:

- Recommended in the majority of athletes wishing to return to cutting/pivoting sports
- Timing
 - Usually 2-3 weeks post-injury
 - Pre-hab important to regain quadriceps strength.
- Graft choice
 - Patellar tendon
 - Hamstrings
 - Quadriceps tendon
 - Allograft



ACL Tears

Return to Play Decision Making

- No return to play same day!
- Vast majority require surgical reconstruction to regain stability for cutting sports.
- Knee must be fully rehabilitated with physical therapy.
 - Full ROM
 - Near full quadriceps strength
- Time to return to sports after surgery:
 - 6-12 months.



ACL Tears

Injury Prevention

Braces

- No data that braces are effective in prevention of ACL tears
 - May prevent MCL injuries
 - Possibly helpful for downhill skiing
- #### **Neuromuscular training programs**
- Can reduce at risk positions
 - Have been shown to reduce ACL injury risk in females to that of males

Griffin et al, JAAOS, 2000
Hewett et al, J Knee Surg, 2005

Knee Injuries in Sports

Key Points

- Patellar dislocations and ACL tears are both common in sports.
- ACL tear leads to immediate effusion; Patellar dislocation swelling may take several hours to develop.
- Both present with history of a feeling a pop and instability.
- Radiographic evaluation is important to rule out fracture or dislocation.
- Patella instability may be treated nonoperatively but has a high rate of recurrence.
- ACL tears are most commonly non-contact injuries.
- ACL tears nearly always require surgical reconstruction.

Guidelines for the Sidelines: Common Musculoskeletal Injuries in Sports

Leg Pain in the Running Athlete

Timothy L. Miller, MD, FAAOS
Assistant Professor of Orthopaedics
and Sports Medicine
Team Physician
Ohio State University Athletics, Capital University
and Granville High School
The Ohio State University Wexner Medical Center

Leg Pain in the Running Athlete

- Most Common Causes
- Presentation
- Diagnostic Tools
- Operative vs Nonoperative Treatment Options
- Return to Sports Decision Making



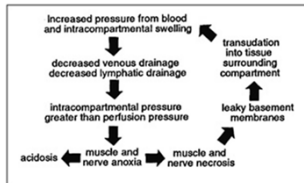
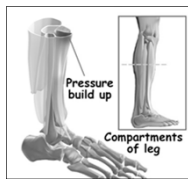
Leg Pain in the Running Athlete

Differential Diagnoses

- Chronic Exertional Compartment Syndrome
- Stress Fracture/ Stress Reaction
- Calf Strain
- Medial Tibial Stress Syndrome
- Tendonitis/Myositis/Cramps
- Sickle Cell Disease
- Tumor
- Popliteal Artery Entrapment Syndrome
- Radiculopathy/ Peripheral Nerve Entrapment

Exertional Compartment Syndrome

Etiology



- Increased pressures within muscle compartments due to due limited space within the fascial coating.
- Transient ischemia caused by insufficient perfusion of muscle tissue during exercise.
- When blood flow is insufficient to meet the requirements of the muscle, the patient experiences pain with continued activity. (Fraipoint et al. JAAOS, 2003.)

Exertional Compartment Syndrome

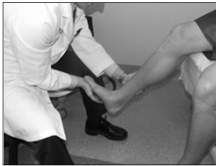Presentation



- Fullness or a cramp-like sensation in the affected compartment with exercise.
- Transient numbness, tingling, or weakness in the motor and sensory distributions of nerves within the involved compartments.
- Rest usually relieves pain, but takes minutes to hours for complete relief to occur, especially with severe CECS.
- Patients typically will not have persistent pain.

Exertional Compartment Syndrome

Physical Exam

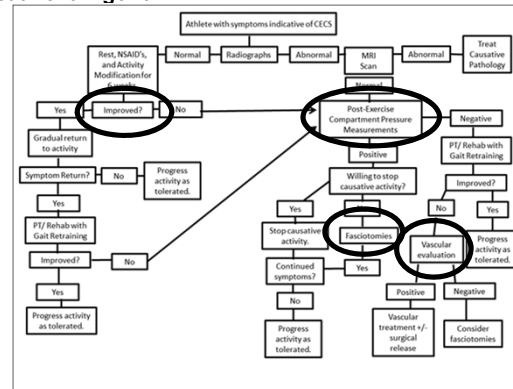


- Typically normal prior to exercise.
- Following exercise provocation, affected compartments may reveal tenderness and increased tension.
- Occasionally associated with decreased sensation or tingling in the distal leg or dorsal foot. (Superficial Peroneal Nerve)
- Loss of foot control/ transient foot drop ("clumsy foot").

Fraipoint et al. JAAOS, 2003.

Exertional Compartment Syndrome

Treatment Algorithm

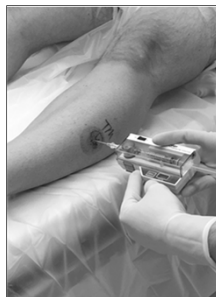

Miller et al., Sports Health, 2017.

Exertional Compartment Syndrome

Diagnostic Tools

- History and Physical Exam
- Intracompartmental Pressure Measurement
- Near Infrared Spectroscopy
- MRI ?



Packer et al., AJSM, 2013.

Van den Brand et al., AJSM, 2005.

Pedowitz et al., AJSM, 1990.

Exertional Compartment Syndrome

Pressure Measurements

- Post-exercise needle manometry
- 15-30-20 at rest, 1 and 5 minutes
- Pedowitz et al., AJSM, 1990.
- Reliability is questionable.
- 30 asymptomatic collegiate distance runners
- Bilateral 1-minute post-exercise pressure measurements of the anterior compartment.
- 11 runners met criteria for CECS in at least one leg. (5 bilateral)
- Miller, Early, Kaeding, 2018.



Exertional Compartment Syndrome

Nonoperative Treatment

Cessation of provocative activities temporarily or indefinitely.

Forefoot Running (*Diebal et al., IJSPT, 2011, Diebal et al AJSM, 2012*)

Alternative Training Surfaces

Deep Tissue Massage

PT/ Rehabilitation

- Stretching/ Strengthening/ Neuromuscular

Conditioning

-Therapeutic Modalities

Orthotic Shoe Inserts

NSAID's

Botox?

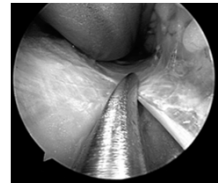
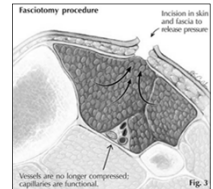
*Brennan et al., Current Sports Medicine Reports, 2003.
Miller et al. Physician and Sports Medicine, 2017.*

Exertional Compartment Syndrome

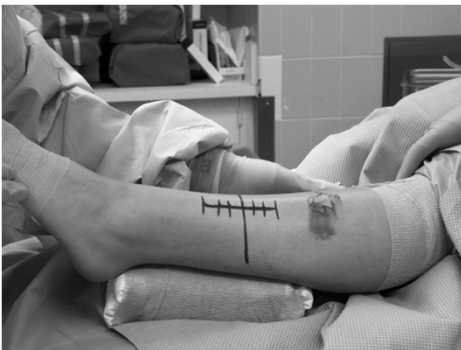Nonoperative Treatment

- Patients with clinical indications of CECS +/- abnormal post-exercise intracompartmental pressure measurements and are unwilling to stop the causative activity.
- Patients who have failed nonoperative treatment.
- Open subcutaneous fascial compartment release +/- partial fasciectomy (1,2 or 4 compartments).
- Endoscopic fascial compartment release.
- +/- Superficial Peroneal Neurolysis

*Packer et al., AJSM, 2013.
Schepers et al., AJSM, 1993.*

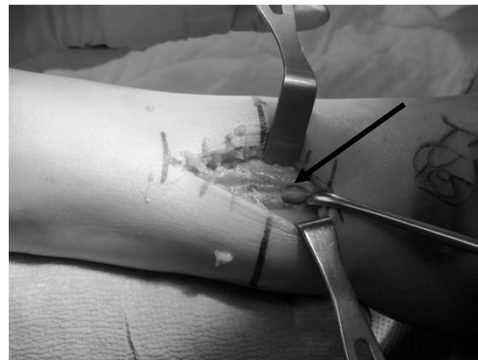

4 Compartment Fasciotomy Procedure



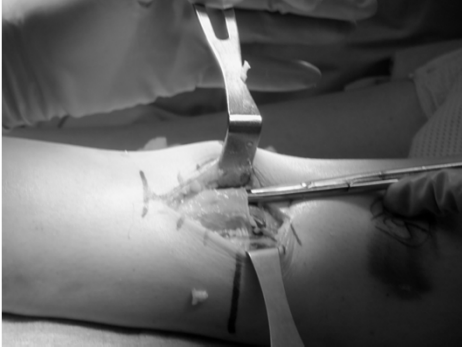Anterior and Lateral Fasciotomy Incision

4 Compartment Fasciotomy Procedure



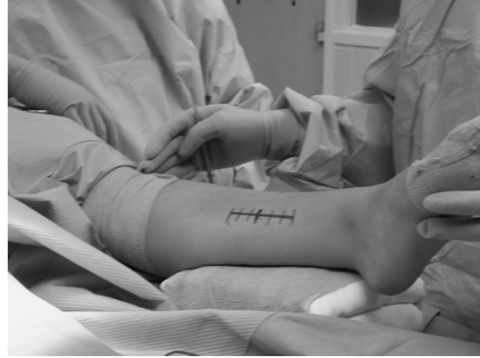Superficial Peroneal Nerve

4 Compartment Fasciotomy Procedure



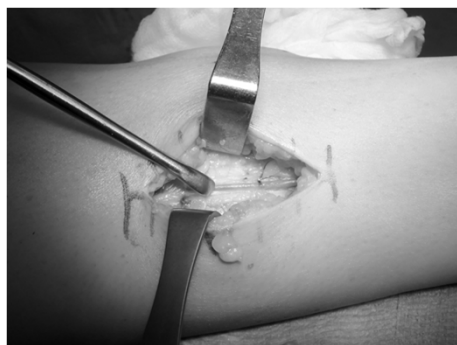Anterior and Lateral Compartment Fasciotomies

4 Compartment Fasciotomy Procedure



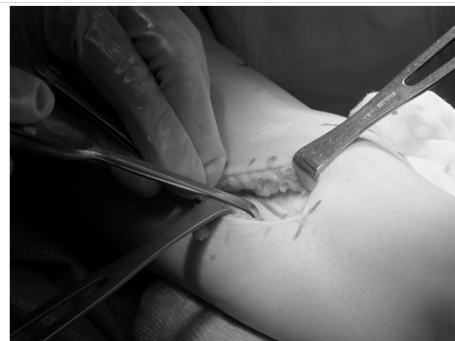Medial Incision for Posterior Fasciotomies

4 Compartment Fasciotomy Procedure



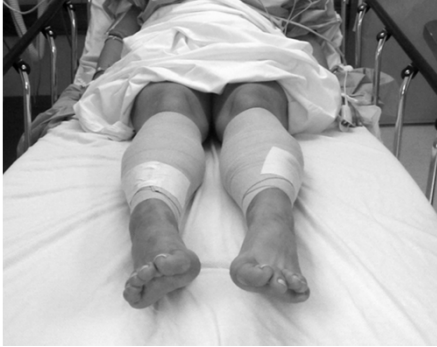Saphenous Vein and Nerve

4 Compartment Fasciotomy Procedure



Superficial and Deep Posterior Fasciotomies

4 Compartment Fasciotomy Procedure




Post-Op Dressing

Exertional Compartment Syndrome

Postop Rehabilitation

- Active range-of-motion exercises should be instituted soon as pain allows.
- Crutches are used for the first few postoperative days.
- Weight bearing as tolerated may begin immediately post-op.
- PT for knee and ankle ROM and strengthening begin 1 week post op.

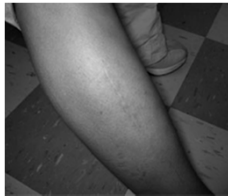


Schepesis, Surgical Techniques in Sports Medicine, 2006.
Miller et al. Sports Health, 2017.

Exertional Compartment Syndrome

Postop Rehabilitation


- The results of compartment releases indicate that most patients surgically treated for CECS in the leg experience pain relief and are satisfied from 81% to 100%. (A + L)
- Success of deep posterior compartment release of the lower extremity ranges from 50% to 65%.
- CECS in the deep posterior compartment is multifactorial, and a fasciotomy may not fully alleviate the cause of the pain.
- Packer et al., AJSM, 2013.
- Fraipont et al., JAAOS, 2003.



Exertional Compartment Syndrome

Return to Running

- Healed wound.
- Symptoms resolved.
- Minimal residual swelling.
- Completed PT program for ankle strengthening and proprioception.
- Typical timeframes:
 - 2 compartments → 6-8 weeks
 - 4 compartments → 8-12 weeks

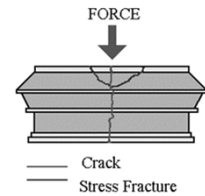


Schepesis, Surgical Techniques in Sports Medicine, 2006.
Miller et al., Sports Health, 2017.

Stress Fractures of the Tibia

Defining a Stress Fracture

- Fatigue failure of bone resulting from repetitive microtrauma.
- Microdamage accumulates at a higher rate than bone repair.
- Fatigue failure of bone has three stages:
 - 1) Crack initiation
 - 2) Crack propagation
 - 3) Complete fracture

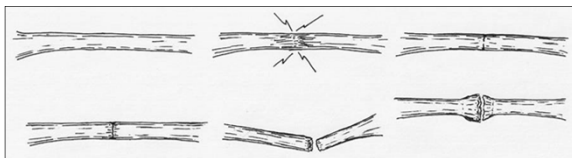


Korpelainen et al., 2001
Keaveny et al., 1993
Jones et al., 1989

“...Occurs when a bone breaks after being subjected to repeated tensile or compressive stresses, none of which, individually, would be large enough to cause a bone to fail in a person without underlying bone disease.”

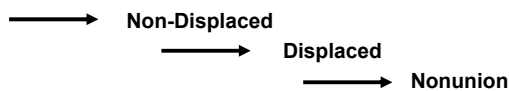
- J. Briethaupt, 1855
Zur pathologie des menschlichen fusses.
Med Z Beri. 1855

Defining a Stress Fracture



Continuum of Severity

Periosteal Reaction



Miller, Kaeding, *Fractures in Adults*, 9th Edition, 2018.

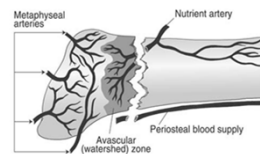
High vs. Low Risk

- High risk stress fractures occur where:

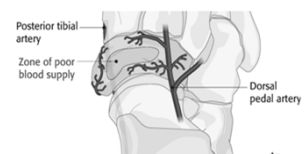“...Tensile forces and the relative avascularity at the site of a stress-induced fracture often lead to poor healing potential and increased likelihood of displacement and nonunion.

...Therefore, high-risk stress fractures require aggressive treatment.”

Boden, JAAOS 2000



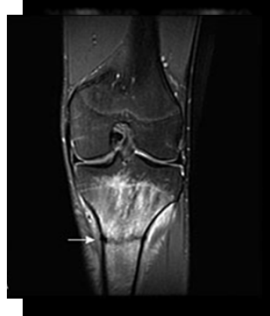
Proximal 5th Metatarsal



Dorsal Navicular

Imaging Evaluation

- Plain Radiographs- Rarely positive
- Bone Scintigraphy-
-Helpful for multiple sites
- Near 100% sensitivity
- 40-80 % specificity
- MRI- Gold standard
-Sensitivity- >90%
Specificity- 90%
-Most predictive of time lost from sport.



Bergman et al, Amer Journal of Roentgenology, 2004.

Stress Fracture Classification

The Comprehensive Description of Stress Fractures: A New Classification System

Christopher C. Kaeding, MD, and Timothy Miller, MD
Investigation performed at the OSU Sports Medicine Center, The Ohio State University, Columbus, Ohio

- Combined Clinical and Radiographic Classification System
- Applicable to all bones.
- Applicable to any imaging modality.
- High levels of inter and intra- observer reliability.

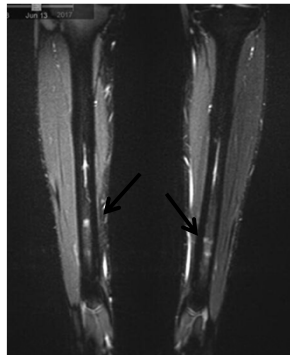
Kaeding, Miller, JBJS 2013.

Stress Fracture Classification

K-M Grades I and II

I- Subclinical, No Pain

II- Bony Edema,
No Fracture Line,
Pain Present

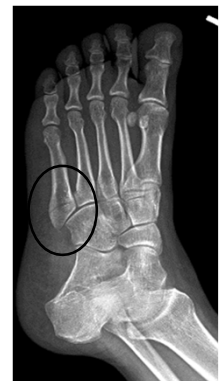

Stress Fracture Classification

K-M Grade III

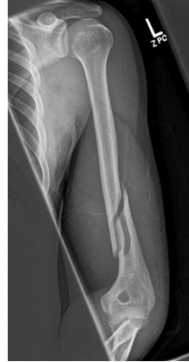Nondisplaced
Fracture Line

Pain present



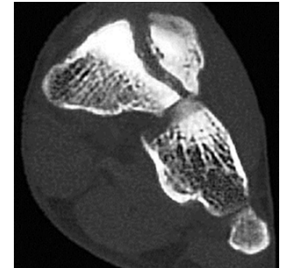
Stress Fracture Classification

K-M Grade IV
Displaced Fracture
(> 2 mm)



Stress Fracture Classification

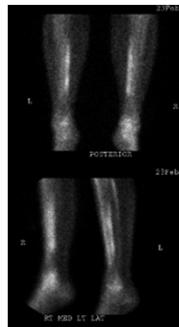
K-M Grade V
Nonunion



Medial Tibial Stress Syndrome

Traction periostitis of tibialis posterior and soleus.

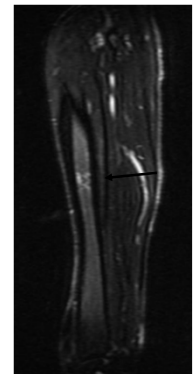
- Risk Factors:
 - Running on cement or uneven surfaces, improper running shoes
 - Sudden increase in training intensity and duration
 - Over-pronation or increase internal tibial torsion
 - Female Triad
- Physical exam
 - Tenderness along posteromedial border of tibia
 - 4 to 12 cm proximal to medial malleolus
- Imaging:
 - Diffuse bony edema on MRI or bone scan



R. Pell et al. Leg Pain in the Running Athlete, JAAOS, 2004.

Posteromedial Tibial Cortex Stress Fracture

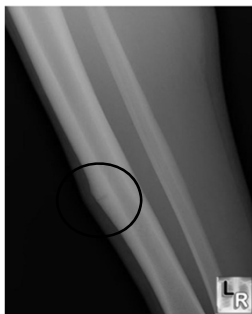- Sequelae of untreated Medial Tibial Stress Syndrome
- Most common site for tibial stress fracture.
- Low-Risk Site
- Compression Forces allow for reliable healing.
- Heals with rest and short term boot immobilization.



*Boden JAAOS, 2001.
Kaeding et al, AAOS ICL 2005.
Jamieson et al, COP, 2017.*

Anterior Tibial Cortex Stress Fracture

- High-Risk Site
- “Dreaded Black Line”
- High tensile forces increase risk of crack propagation.
- Requires prolonged immobilization and protected weight bearing until symptoms resolve.
- Intramedullary nailing when no healing is evident within 3-6 months.



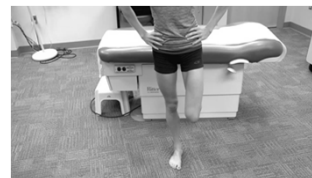
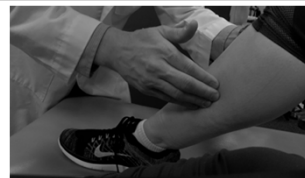Boden, JAAOS 2000

McInnis, Ramey, PMRJ, 2016

Anterior Tibial Cortex Stress Fracture

Physical Examination

- Pain on palpation typically central 1/3 of tibia
- Pain with weight bearing
- Pain with single leg hop
- Fulcrum Test
- Tuning fork test
 - Sensitivity and specificity of vibration testing is low and should not be relied upon for diagnosis

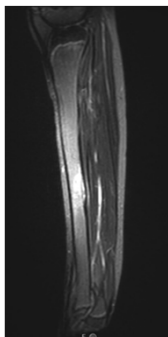


Lesho, Mil Med, 1997
McInnis, Ramey, PMRJ, 2016

Anterior Tibial Cortex Stress Fracture

Treatment options:

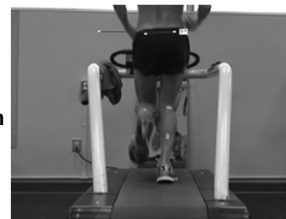- 3-6 months rest and NWB +/- immobilization
- Electrical stimulation (PEMF)
- IM rod
- Tension band plate
- Excision and bone grafting
- Consensus for competitive athlete is reamed IM rod or compression plate.



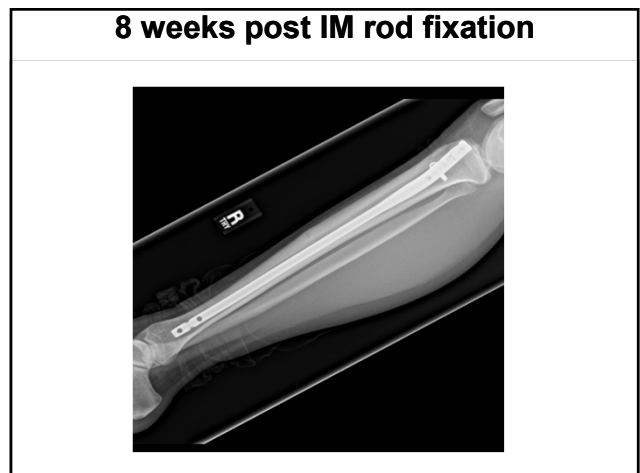
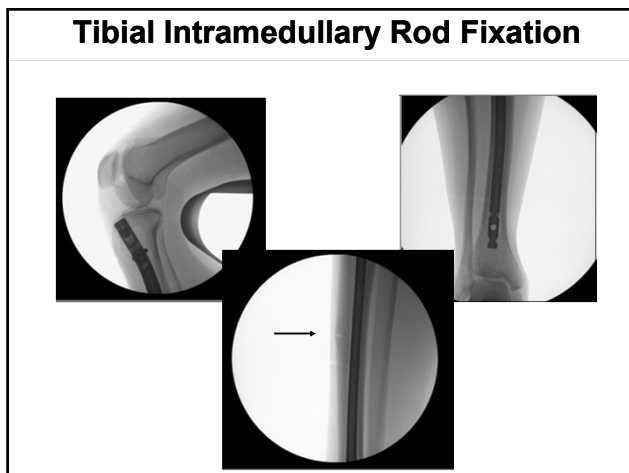
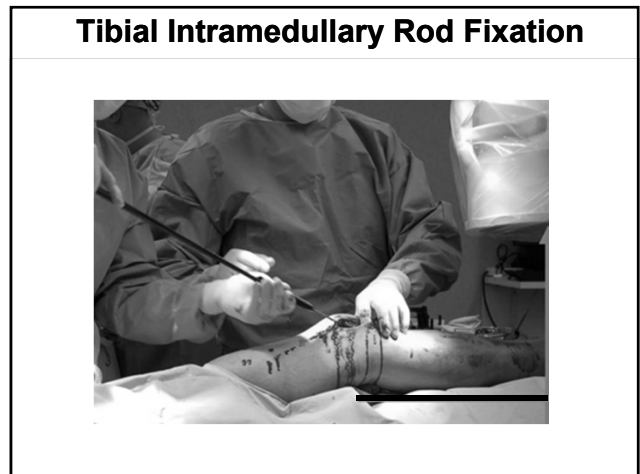
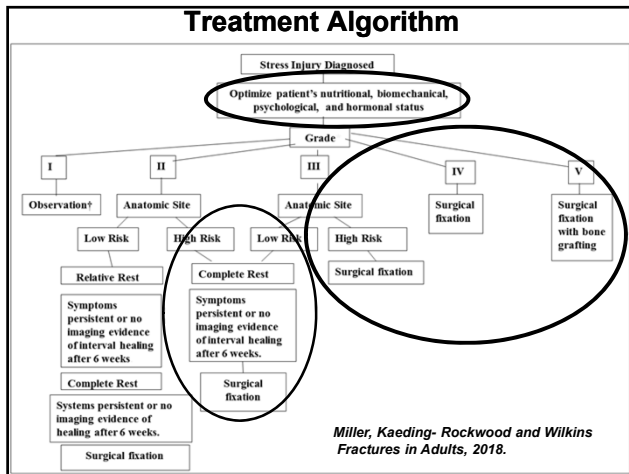
McInnis, Ramey, PMRJ, 2016

A Holistic Approach to Treatment

- Stop/ limit causative activity
- Protected weightbearing
- Avoid NSAID's
- Bone Density Evaluation
- Nutritional optimization
 - Vitamin D supplementation
 - Appropriate caloric intake
- Hormonal balance
- Running Gait Analysis



• Miller, Best, JORS, 2016.
• Miller et al, Sports Med, 2003.



RESIDENT RESEARCH AWARD

Time to return to running after tibial stress fracture
in female Division I collegiate track and field

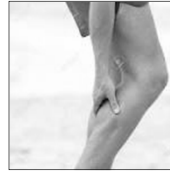Marissa Jamieson, MD, Allison Schroeder, MD, Jason Campbell, BS, Courtney Seigel, MS, ATC,
Sonshearae Everson, ATC, MS and Timothy L. Miller, MD

The Ohio State University Sports Medicine Center, Columbus, OH

- 24 Tibial Stress Fractures in T&F athletes collected from 2011 to 2015.
- Predictive of time to healing and time to return to sports in collegiate athletes.
- Higher the level of severity → Longer time to healing and return.
- Grade III's took avg 1 month longer than Grade II's.
- Grade V's took avg 10 weeks longer than Grade III's.
- **BMI 19 or less** → longer recovery and multiple SF's.

Jamieson et al. *Current Orthopedic Practice* 2017.

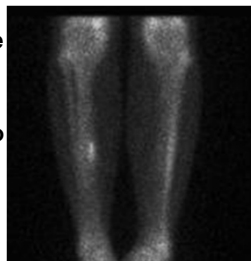
Key Points for Leg Pain in Runners



- Exertional compartment syndrome is a clinical diagnosis.
- Post-exercise pressure measurements are only part of the picture.
- If the diagnosis is correct, most patients do not respond to non-operative treatment.
- Fasciotomy produces high success rates when the diagnosis is correct.
- When fasciotomy fails, consider incomplete release or an alternative diagnosis.

Key Points for Leg Pain in Runners

- Not all bony stress injuries are equal.
- Radiographs are rarely positive unless injury is chronic or severe.
- Anterior tibial stress fractures require aggressive treatment to prevent displacement and delayed healing.
- Surgical stabilization is often required for the "Dreaded Black Line."
- BMI of 19 or less increases risk.
- Treatment requires a holistic approach to optimize healing.



Ohio State Sports Medicine

Thank you.