

Lung Diseases They Didn't Teach You About In Medical School

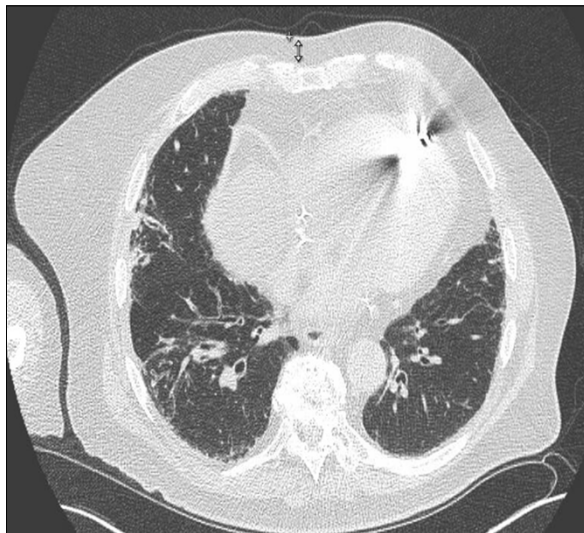
**Derrick Herman, MD
Assistant Professor
Department of Internal Medicine
Division of Pulmonary, Allergy, Critical Care
and Sleep Medicine
The Ohio State University Wexner Medical Center**

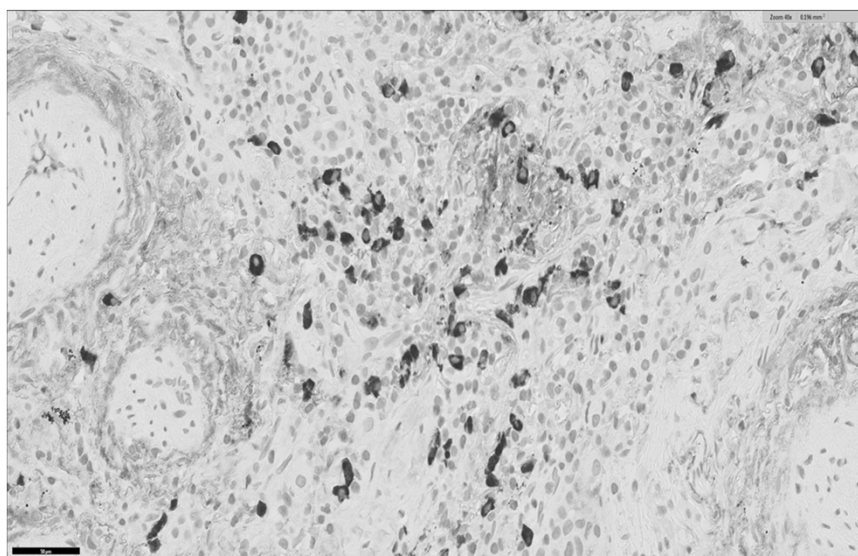
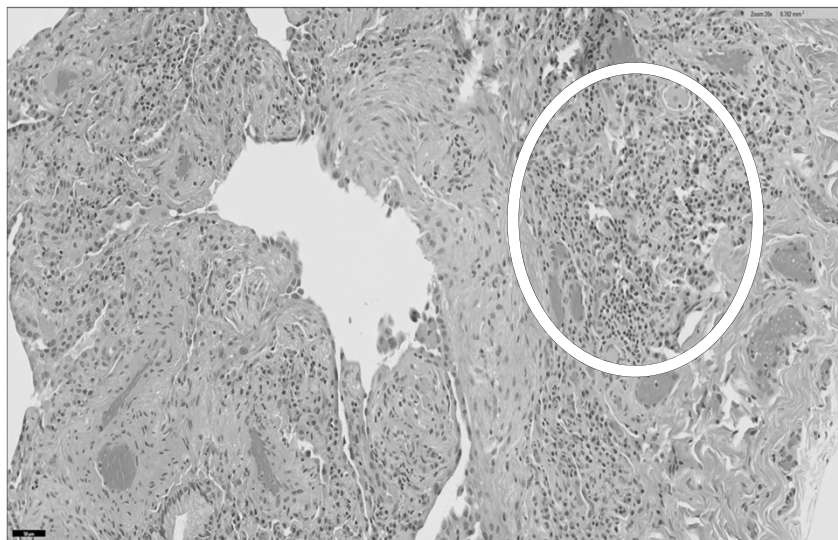
Case #1

- **76 year old man**
- **Dyspnea and cough for 5 years**
- **Past medical history: chronic pancreatitis**
- **Social history: former smoker**
- **Exam: bibasilar dry crackles**

Case #1 (continued)

- **Sed rate > 130**
- **C-reactive protein elevated at 13.9**
- **Atypical ANCA positive at 1:80**
- **SS-A antibody positive**
- **Eosinophil count elevated at 600**
- **Serum IgG4 749.0 (121 the upper limit of normal)**





IgG4 Stain

Diagnosis: IgG4 Disease

IgG4 Disease: Overview

- **Disease did not appear in medical publications until 2003**
- **Multi-organ immune related condition**
- **Mimics many malignant, infectious, and inflammatory disorders**

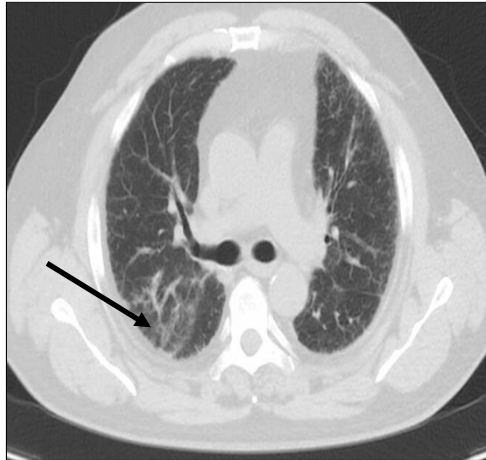
IgG4 Disease: Organs Affected

- Autoimmune pancreatitis
- Salivary/parotid gland enlargement
- Thyroiditis
- Sclerosing cholangitis
- Lymphadenopathy
- Retroperitoneal fibrosis
- Aortitis
- Tubulointerstitial nephritis
- Skin rash
- Interstitial lung disease

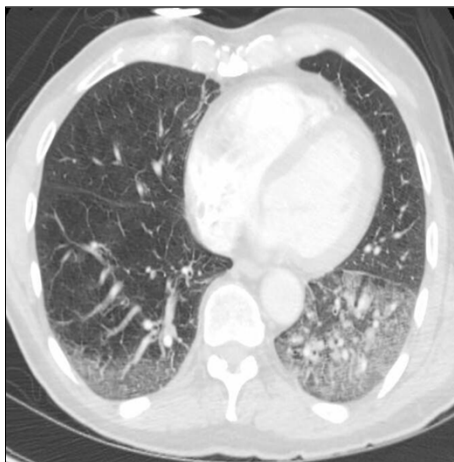IgG4 Disease: Pulmonary Manifestations

- Parenchymal
 - Nodules or masses
 - Ground glass infiltrates
 - Interstitial infiltrates
- Mediastinal adenopathy
- Bronchostenosis
- Pleural effusions

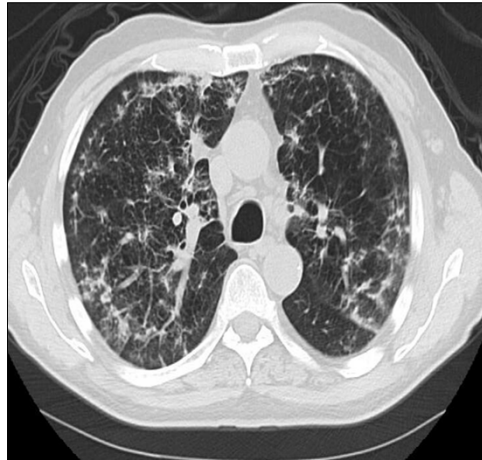
IgG4 Disease Presenting as Interstitial Lung Disease



IgG4 Disease Presenting with Consolidations



IgG4 Disease Presenting as Cryptogenic Organizing Pneumonia



IgG4 Disease: Diagnosis

- **Elevated serum IgG4**
- **Tissue biopsy**
 - **Dense lymphoplasmacytic infiltrates & storiform fibrosis**
 - **Increased IgG4-staining plasma cells**
 - **Increased eosinophils**

IgG4 Disease: Treatment

- **Corticosteroids**
- **Mycophenolate**
- **Azathioprine**
- **Rituximab**

Key Points About IgG4 Disease

- **Recently recognized multi-organ immune related condition**
- **Mimics malignant, infectious, and inflammatory disorders**
- **Diagnosed by an elevated serum IgG4 and biopsy**
- **Treatment is immunosuppression**

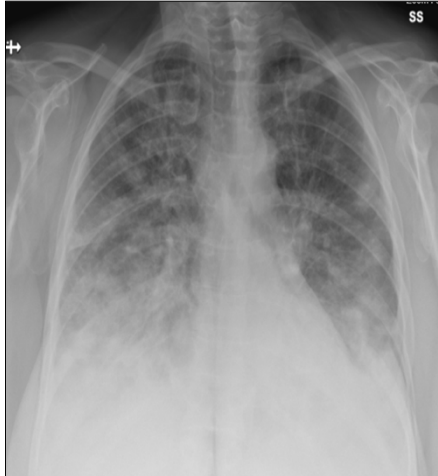Lung Diseases They Didn't Teach You About In Medical School

James Allen, MD
Medical Director, The Ohio State University Wexner
Medical Center East Hospital
Professor of Internal Medicine
Division of Pulmonary and Critical Care Medicine
The Ohio State University Wexner Medical Center

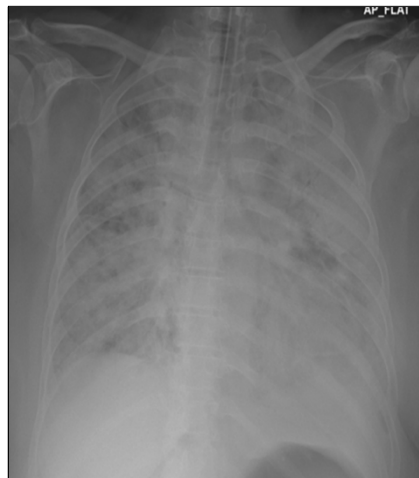Case #2

- **59-year old woman**
- **Unremarkable past medical history**
- **3-day history of cough and progressive dyspnea**
- **No improvement with outpatient antibiotic**
- **Exam: mild bibasilar crackles**
- **Lab: WBC = 16.3 with 1,200 eosinophils**

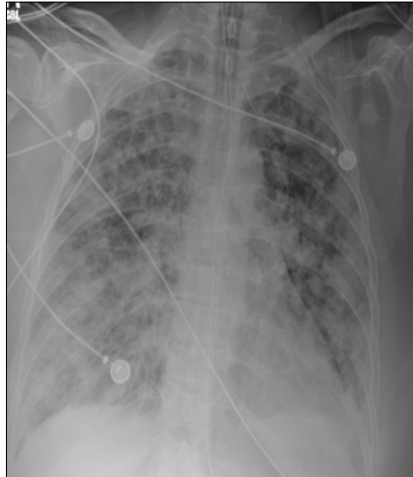
January 21, 2019 – emergency department



January 22, 2019 – intensive care unit



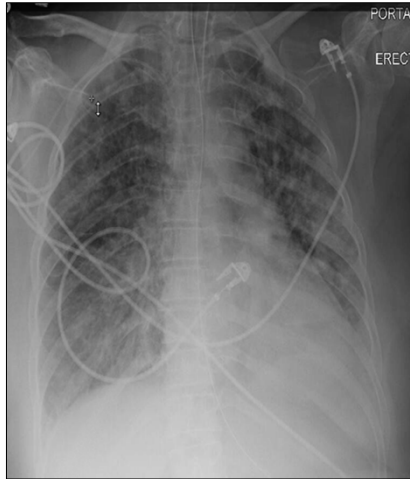
**January 23, 2019 – transferred
to Ohio State**



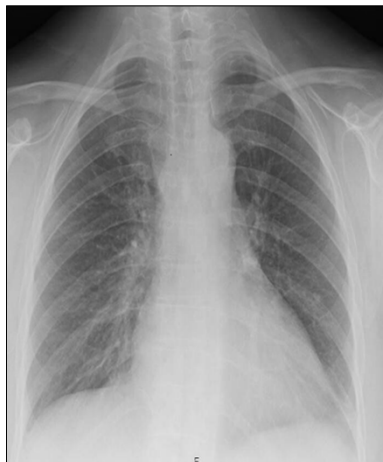Bronchoalveolar lavage

- **10% Alveolar macrophages**
- **2% Neutrophils**
- **3% Lymphocytes**
- **85% Eosinophils**

January 24, 2019



March 1, 2019



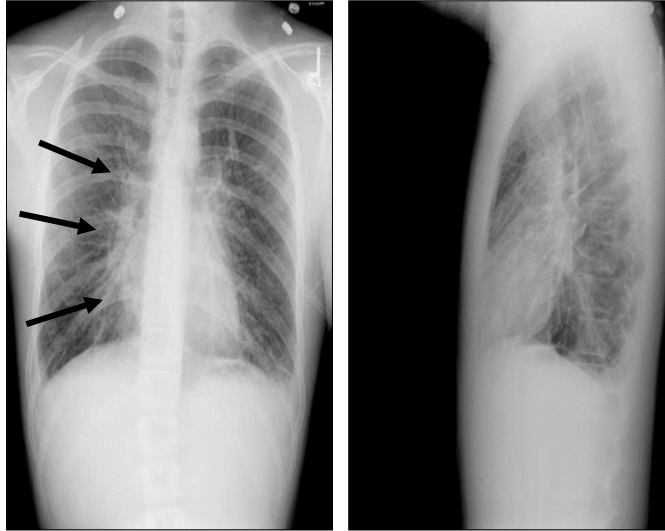
Acute Eosinophilic pneumonia

- **Presentation:**
 - Average symptoms 4 days
 - Average age 29 yrs
 - Symptoms:
 - Cough 100%
 - Dyspnea 95%
 - Chest pain 73%
 - Myalgias 50%
 - 40% “beginner” smokers
- **Exam:**
 - Average temperature 101° F
 - Average respiratory rate 32/min
 - Crackles in 80%

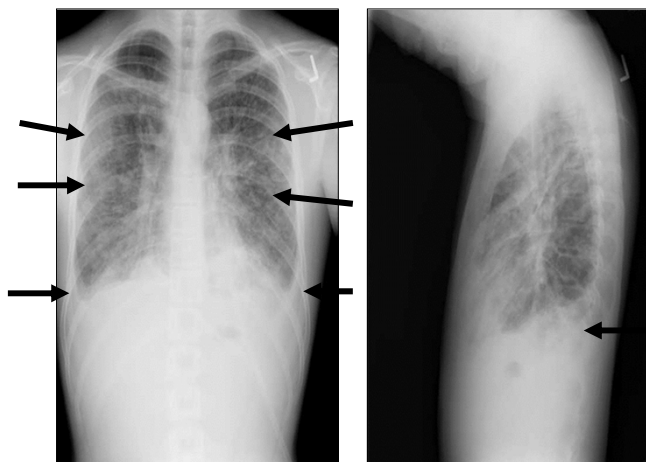
Acute Eosinophilic pneumonia

- **Chest X-ray:**
 1. Kerley B lines
 2. Interstitial infiltrates
 3. Alveolar infiltrates
 4. Pleural effusions
- **Lab:**
 - Average WBC 17,000
 - Blood eosinophils may not be elevated
 - Average PO₂ = 57 mm

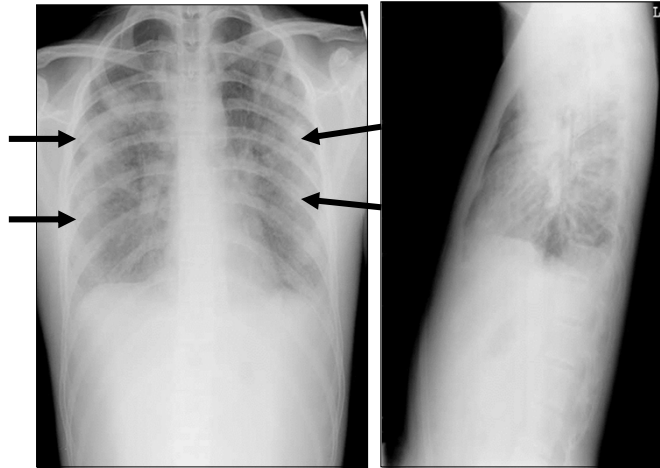
Acute Eosinophilic Pneumonia Day #1



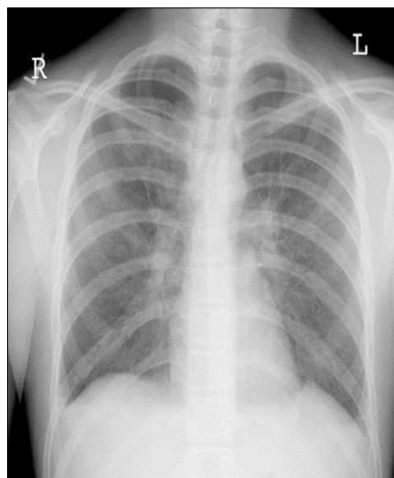
Acute Eosinophilic Pneumonia Day #2



Acute Eosinophilic Pneumonia Day #3

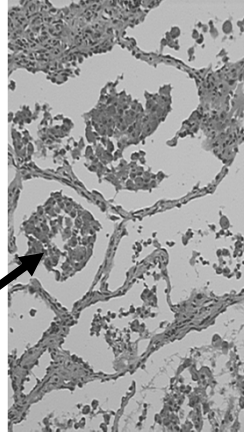


Acute Eosinophilic Pneumonia Day #7



Acute Eosinophilic pneumonia

- Typical BAL:
 - 37% eosinophils
 - 20% lymphocytes
 - 15% neutrophils
 - 28% macrophages
- Lung biopsy:
 - Intra-alveolar eosinophils



Acute Eosinophilic Pneumonia Treatment:

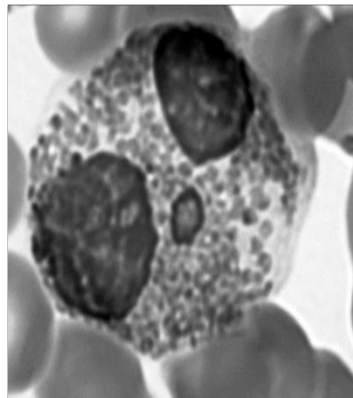
- Initial treatment:
 - With respiratory failure: IV Methylprednisolone 60-125 mg every 6 hours
 - Without respiratory failure: Prednisone 40-60 mg daily
- Subsequent treatment:
 - Prednisone 40-60 mg daily - taper over 2-4 weeks
- Relapses are rare

Acute Eosinophilic Pneumonia: Causes

- **Idiopathic**
- **Cigarette smoking**
- **Prescription drugs**
- **Street drugs**
- **Organic dust inhalation**
- **Parasites**

Key points about acute eosinophilic pneumonia

- **It mimics severe pneumonia or ARDS**
- **Bronchoscopy with BAL is required for diagnosis**
- **Responds immediately to steroids**
- **Often associated with beginning cigarette smoking**

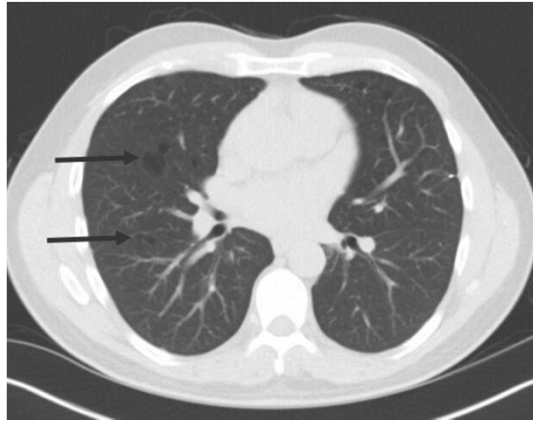


Lung Diseases They Didn't Teach You About In Medical School

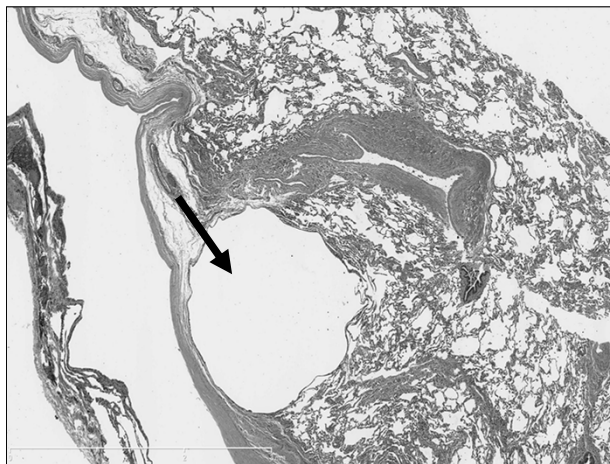
Derrick Herman, MD
Assistant Professor
Department of Internal Medicine
Division of Pulmonary, Allergy, Critical Care
and Sleep Medicine
The Ohio State University Wexner Medical Center

Case #3

- **50 year old man**
- **Recent spontaneous pneumothorax**
- **Past medical history: spontaneous pneumothorax 15 years prior**
- **Family history:**
 - **Father had spontaneous pneumothorax**
 - **Brother with kidney cancer**
- **Exam: normal**



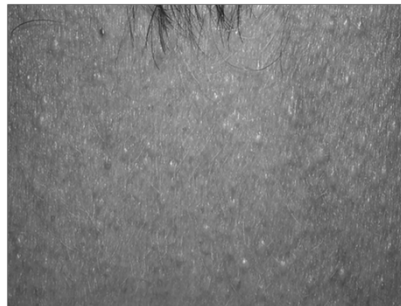Lung Biopsy at the Time of Surgical Pleurodesis



Diagnosis: Birt-Hogg-Dube Syndrome

Birt-Hogg-Dube Syndrome: Overview

- Autosomal dominant inheritance
- Folliculin (FLCN) gene mutation
- Clinical manifestations
 - Skin fibrofolliculomas
 - Kidney cancer – chromophobe tumors
 - Bilateral pulmonary cysts

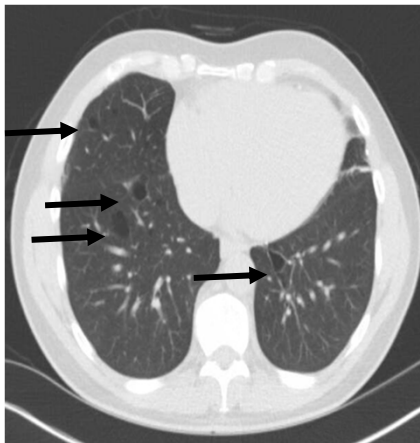


Birt-Hogg Dube Syndrome: Pulmonary Manifestations

- Cystic lung lesions in the 4th to 5th decade of life
- 2 common pulmonary presentations:
 - Incidental pulmonary cystic lesions on chest CT
 - Pneumothorax

Birt-Hogg Dube Syndrome: Radiology

- Basilar predominant pulmonary cystic lesions



Birt-Hogg-Dube Syndrome: Diagnosis

- **Pulmonary cysts plus personal or family history of:**
 - **Pulmonary cysts or pneumothorax**
 - **Fibrofolliculomas**
 - **Renal tumors**
- **Genetic testing for the FLCN gene**

Birt-Hogg-Dube Syndrome: Management

- **Renal cancer the most threatening manifestation**
 - **Cancer screening every 1-2 years:**
 - **Ultrasound**
 - **CT**
 - **MRI**
- **Pulmonary disease**
 - **Cysts do not usually impair lung function**
 - **Prevention of pneumothorax recurrence**

Key Points About Birt-Hogg-Dube Syndrome

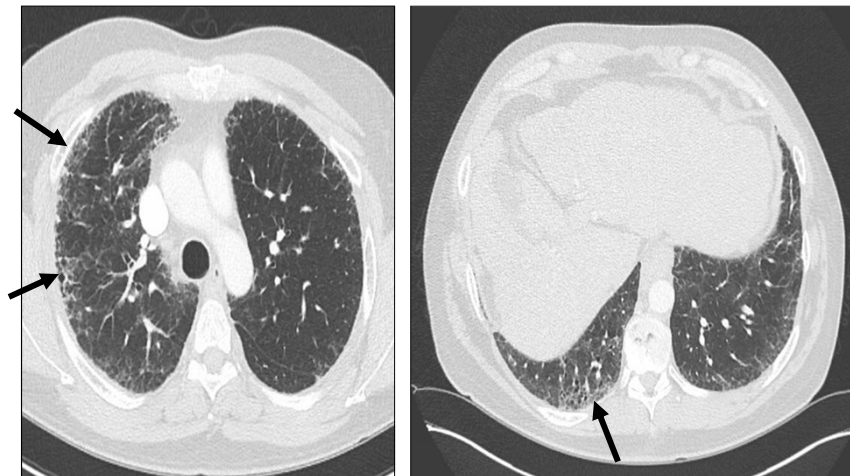
- **Syndrome of:**
 - **Skin fibrofolliculomas**
 - **Kidney cancer**
 - **Pulmonary cysts with or without pneumothorax**
- **Folliculin gene mutation**
- **Autosomal dominant inheritance**

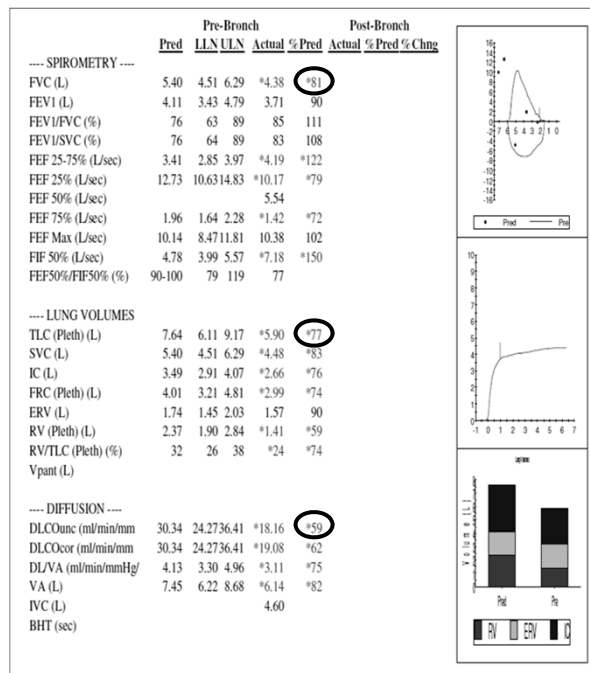
Lung Diseases They Didn't Teach You About In Medical School

James Allen, MD
Medical Director, The Ohio State University Wexner
Medical Center East Hospital
Professor of Internal Medicine
Division of Pulmonary and Critical Care Medicine
The Ohio State University Wexner Medical Center

Case #4

- 57 year-old man referred for pulmonary pre-op evaluation
- History of cirrhosis due to NASH
 - Undergoing liver transplant evaluation
- Progressive dyspnea for 6 months
- Hair turned gray at age 16
- Father died of “asbestosis” and cirrhosis
- Exam: bibasilar dry crackles

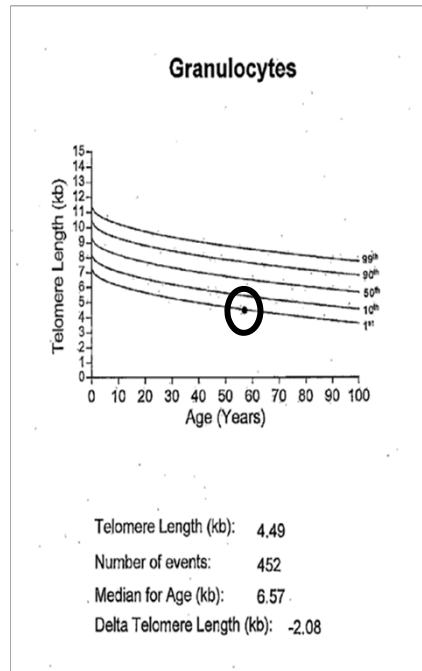




Idiopathic pulmonary fibrosis (IPF)

- **85% are sporadic**
- **15% are familial/inherited**
 - Family members may have been diagnosed with “asbestosis”, “black lung”, or “lung scarring”
 - Many genes are involved
 - MUC5B gene
 - Telomerase genes
- Sporadic and familial idiopathic pulmonary fibrosis are treated the same

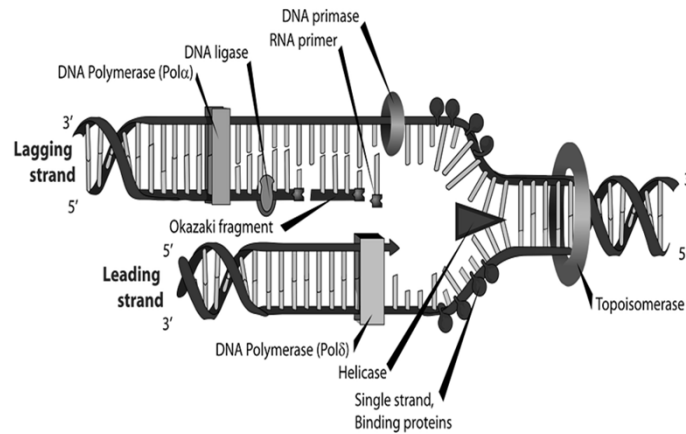
Telomere Length Testing



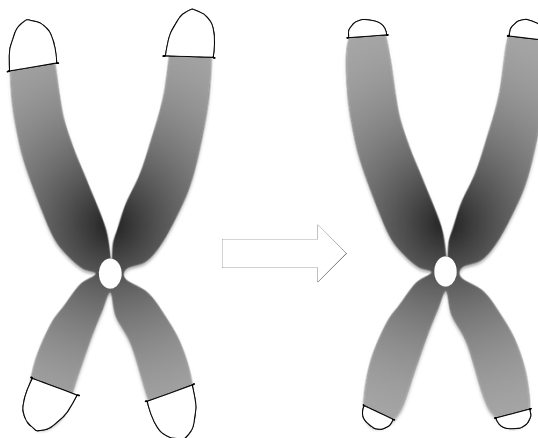
Telomeres



50 - 100 base pairs of telomere DNA is lost at the end of the lagging strand with every replication




Telomeres **Repeating sequences of TTAGGG**



11 Kilobases At Birth

4 Kilobases At Age 80

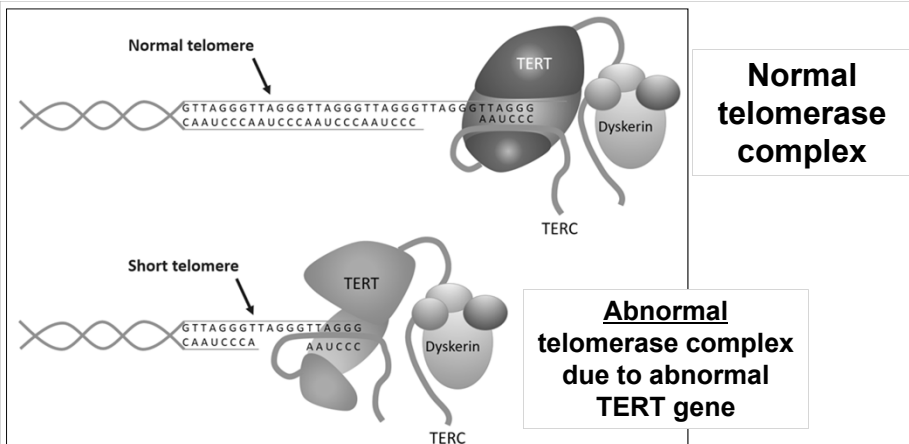
Telomeres are the body's chromosomal clocks



Telomerase replenish telomeres at the end of DNA

Normal telomerase complex

Abnormal telomerase complex due to abnormal TERT gene



Short telomere syndromes

- **Familial idiopathic pulmonary fibrosis**
- **Premature graying of the hair (before age 30)**
- **Cryptogenic cirrhosis**
- **Aplastic anemia**
- **Myelodysplasia**

Short Telomere Syndrome Key Points

- **Presentations:**
 - **Idiopathic pulmonary fibrosis**
 - **Cirrhosis**
 - **Myelodysplasia**
- **A good family history is essential**
- **Ask the patient when their hair turned gray**
- **Telomere length testing is supportive**



Lung Diseases They Didn't Teach You About In Medical School

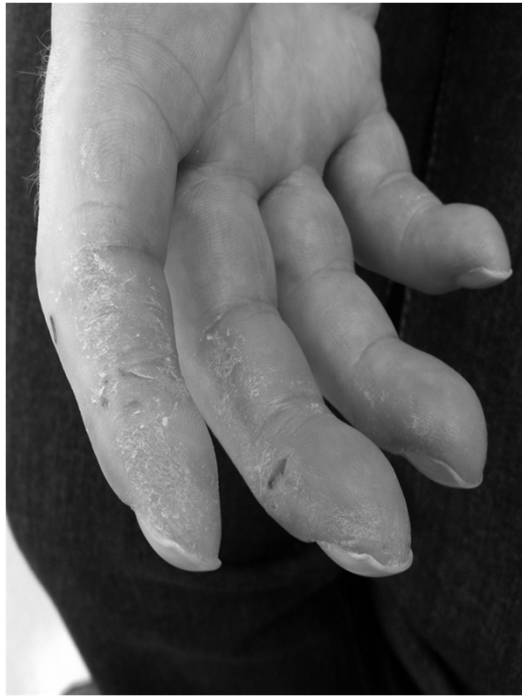Derrick Herman, MD
Assistant Professor
Department of Internal Medicine
Division of Pulmonary, Allergy, Critical Care
and Sleep Medicine
The Ohio State University Wexner Medical Center

Case #5

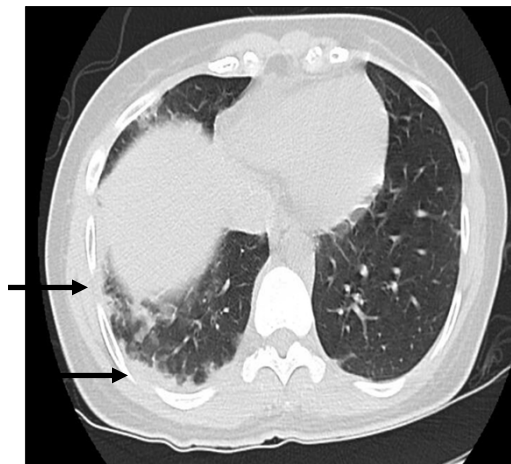
- **Previously healthy 29 year old woman**
- **2 months of progressive dyspnea**
- **No improvement despite multiple antibiotics for pneumonia**
- **Social history: never smoker**
- **Review of systems notable for Raynaud's phenomenon**

Case #5 (continued)

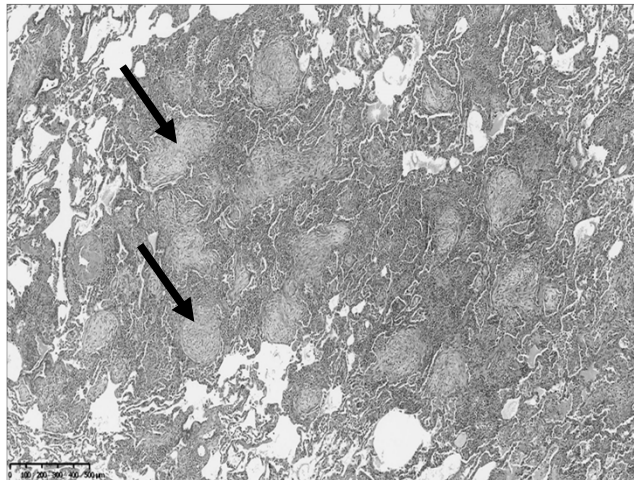
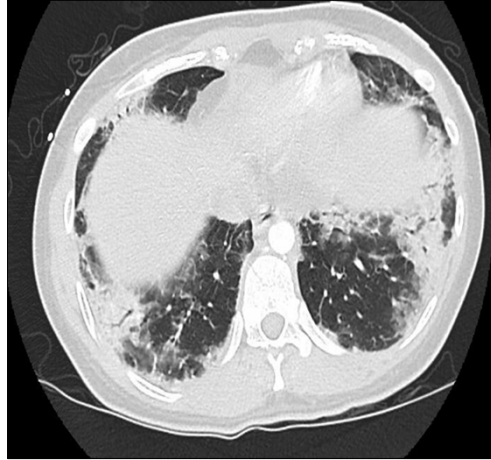- **Exam:**
 - **Bilateral diffuse crackles**
 - **Mild mechanic's hands**
- **Labs:**
 - **Elevated aldolase 15.1 (upper limit 8.1)**
 - **SS-A & CCP antibody positive**
 - **Anti-Jo1 antibody positive**



Chest CT



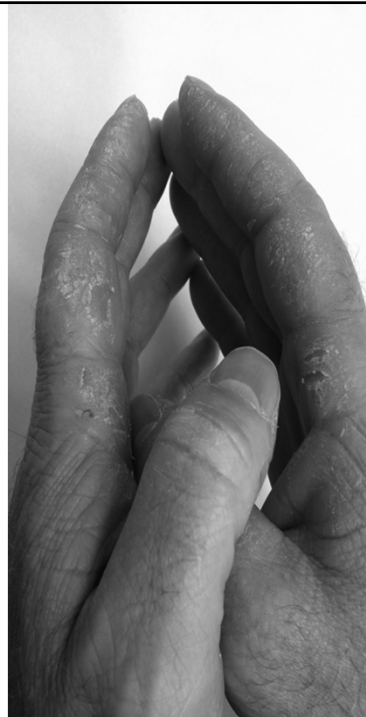Chest CT 6 Weeks Later



Diagnosis: Organizing Pneumonia due to an Idiopathic Inflammatory Myopathy

Idiopathic Inflammatory Myopathy: Overview

- Polymyositis, dermatomyositis, and inclusion body myositis
- Muscular signs and symptoms
- Extramuscular signs and symptoms
 - Constitutional
 - Dermatological signs
 - Raynaud's
 - Arthralgias
 - Pulmonary



Idiopathic Inflammatory Myopathy: Pulmonary Manifestations

- **Prevalence may approach 65%**
- **Most significant extramuscular contributor to morbidity**
- **Interstitial lung disease is the hallmark**
 - **May precede muscular signs in up to 20% of cases**

Rapidly Progressive Interstitial Lung Disease

- **Acute interstitial pneumonia progressing over several weeks or months**
 - **Strongly suggestive of an idiopathic inflammatory myositis**
- **Associated with anti-MDA5 (melanoma differentiation associated protein 5) antibody**

Idiopathic Inflammatory Myopathy: Radiology & Pathology

- **Radiology**
 - **Common: linear opacities, ground-glass opacities, reticulation**
 - Organizing pneumonia and non-specific interstitial pneumonia patterns (NSIP)
 - **Less frequent: honeycombing**
 - Usual interstitial pneumonia
- **Pathology**
 - Organizing pneumonia
 - NSIP

Idiopathic Inflammatory Myopathy: Diagnosis

- **Clinical history & exam**
- **Serological testing**
 - **Creatine kinase, aldolase, myositis-specific antibodies (i.e. anti-Jo1, anti-MDA5, etc.)**
- **Exclusion of infection**
- **Compatible chest CT**
- **+/- lung biopsy**

Idiopathic Inflammatory Myopathy: Management

- **Corticosteroids**
- **Mycophenolate**
- **Azathioprine**

Key Points About Idiopathic Inflammatory Myopathy

- **Muscular and extramuscular signs and symptoms**
 - **Pulmonary disease the primary extramuscular contributor to morbidity**
- **Diagnosed through clinical history, serology, radiology, +/- pathology**
 - **Organizing pneumonia the most common radiology and pathology**
- **Rapidly progressive pulmonary form associated with anti-MDA5 antibody**
- **Treatment is immunosuppression**

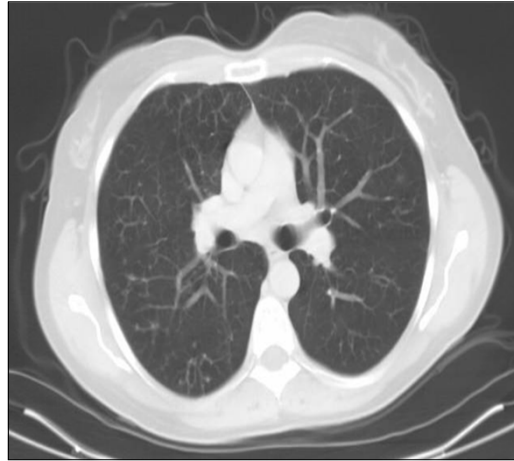Lung Diseases They Didn't Teach You About In Medical School

James Allen, MD
Medical Director, The Ohio State University Wexner
Medical Center East Hospital
Professor of Internal Medicine
Division of Pulmonary and Critical Care Medicine
The Ohio State University Wexner Medical Center

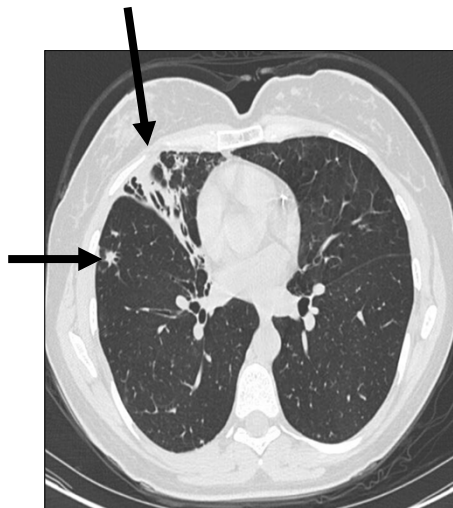Case #6

- **42 year-old woman with 14 year history of recurrent pneumonia**
- **Normal sweat chloride, IgG, IgE, alpha-1-antitrypsin**
- **2004 BAL = negative AFB culture**
- **2006 BAL = Mycobacterium avium complex & Mycobacterium abscessus**
- **2008: completed 18 months of antibiotics**
- **2015: recurrent sputum production and pneumonias**

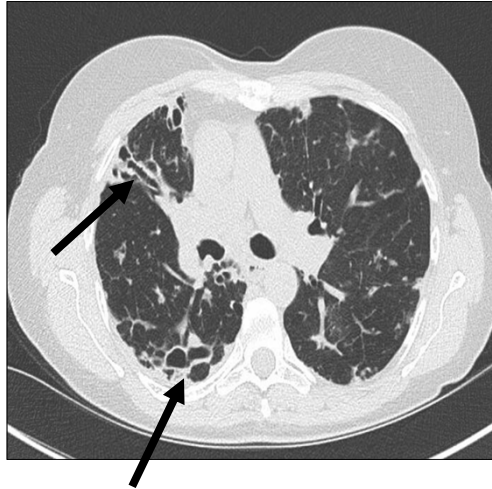
2003



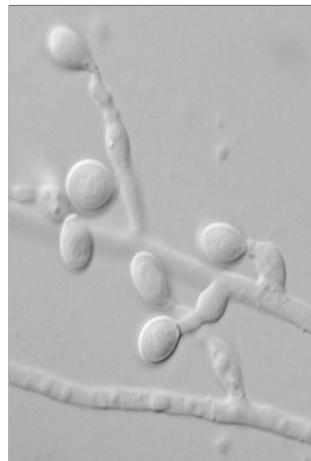
2007



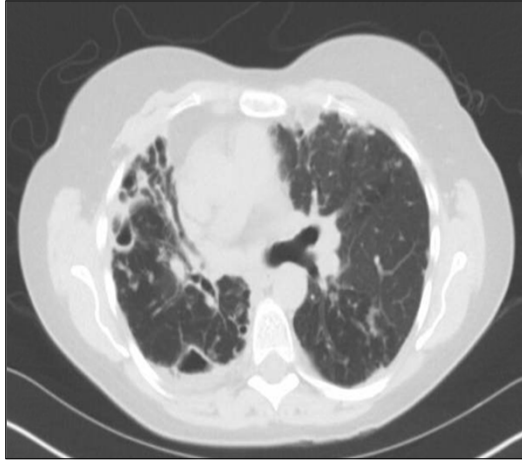
2015



Repeat BAL: Scedosporium



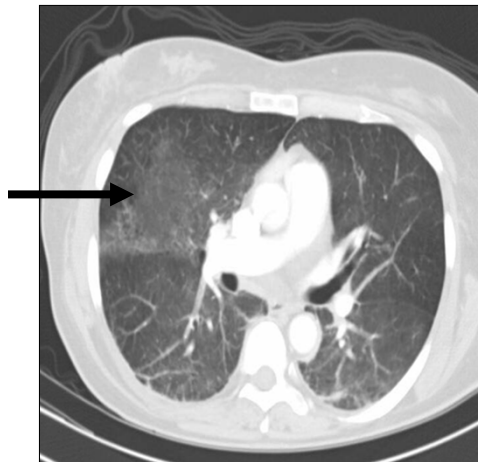2018



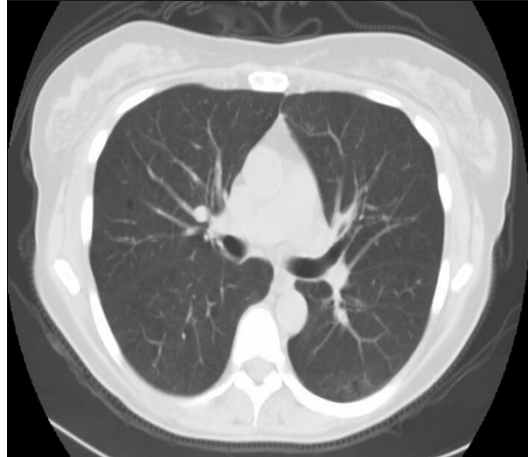
Typical clinical presentations

- Ophthalmologic
- Brain abscess
- Skin and soft tissues
- Pulmonary infections
- Patients are often immunosuppressed
- Chronic pneumonia in immunocompetent patients can occur
- Diagnosis is by fungal culture
- Treatment:
 - Voriconazole
 - Surgical debridement

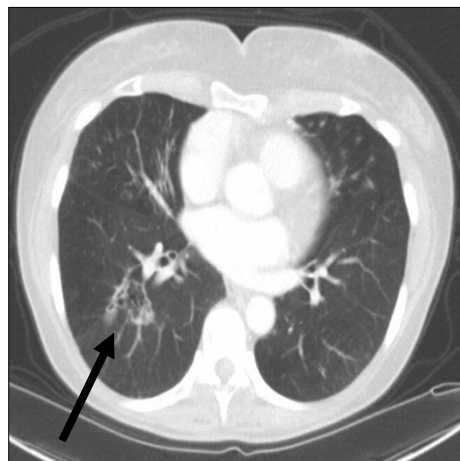January 5, 2007



January 31, 2007

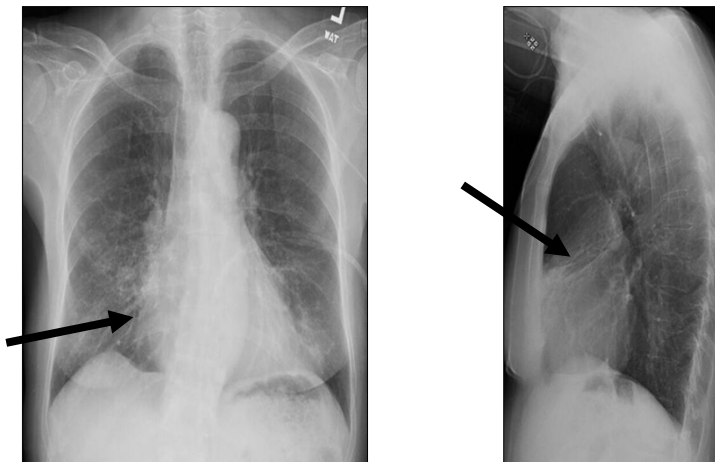


2019



**Sometimes
surgery is the only
effective cure**

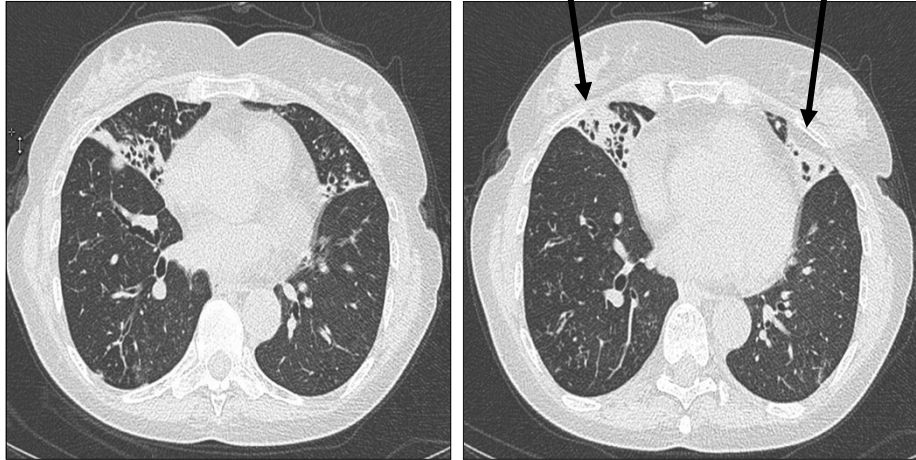
October 2011



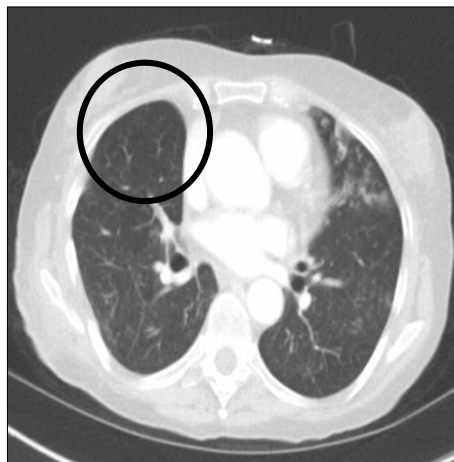October 2011

Right
Middle
Lobe

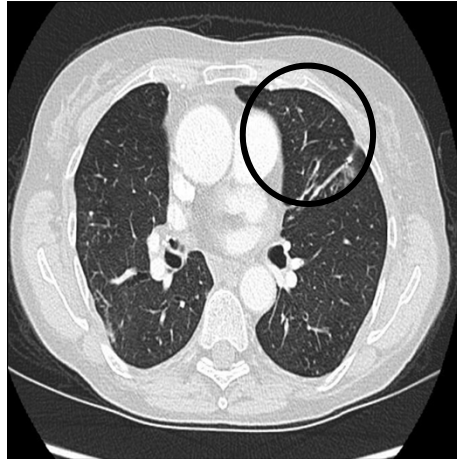
Lingula of
Left Upper
Lobe



April 2012 after right middle lobectomy

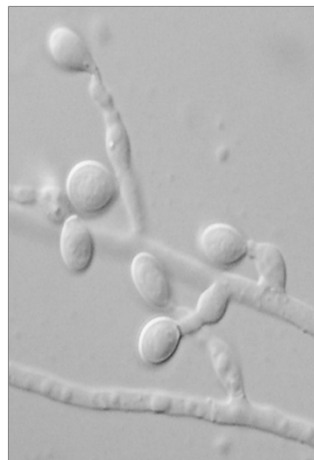


2018 after lingula segmentectomy



Key Points About Scedosporium

- Patients often are immunosuppressed
- But... chronic pulmonary infection can occur in normal patients and those with underlying bronchiectasis
- Anti-fungal antibiotics are often ineffective
- Surgery is often necessary

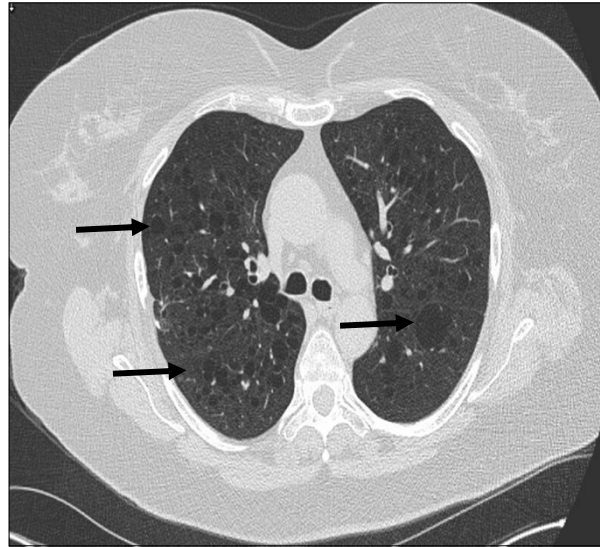


Lung Diseases They Didn't Teach You About In Medical School

Derrick Herman, MD
Assistant Professor
Department of Internal Medicine
Division of Pulmonary, Allergy, Critical Care
and Sleep Medicine
The Ohio State University Wexner Medical Center

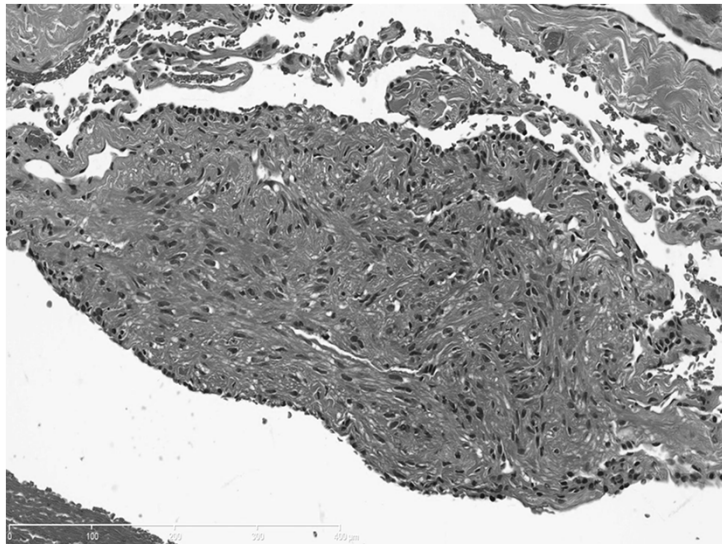
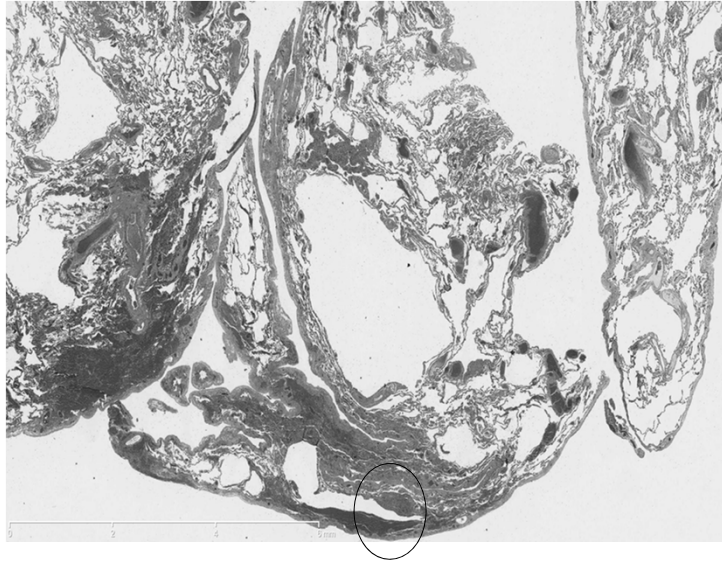
Case #7

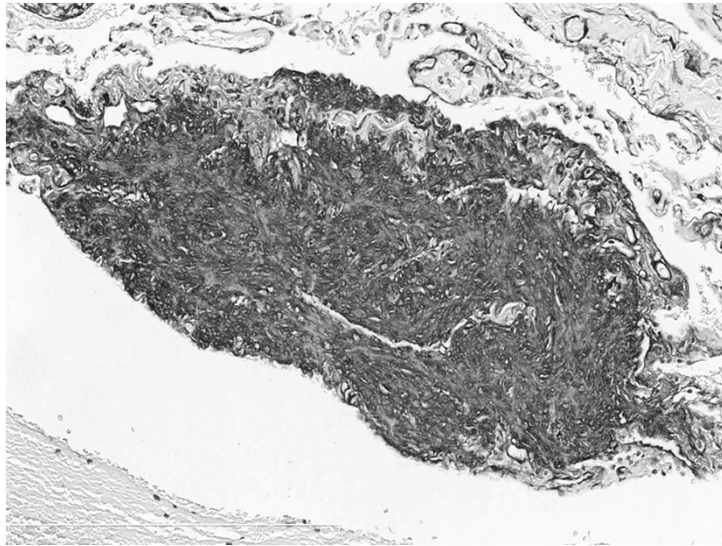
- **Previously healthy 39 year old woman**
- **Progressive shortness for several months**
- **Social history: never smoker**
- **Exam: normal**



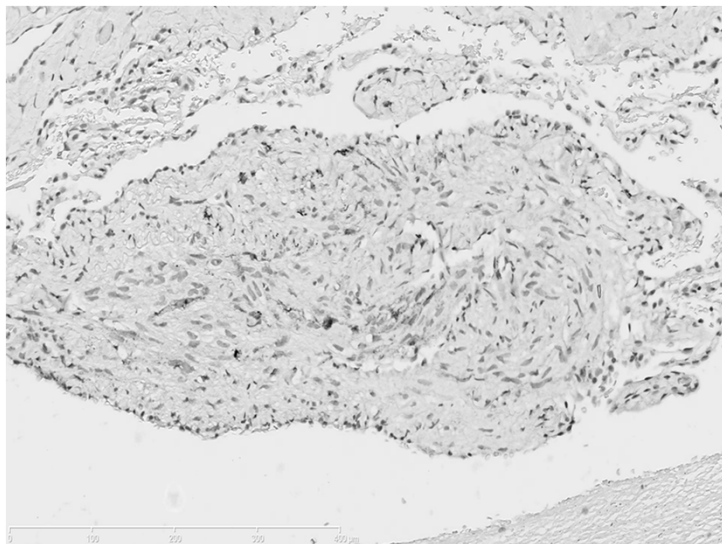
Case #7

- **Labs:**
 - **ANCA negative**
 - **Alpha-1-antitrypsin negative**
 - **ANA negative**
 - **Serum vascular endothelial growth factor (VEGF): 802 pg/ml (upper limit of normal 310)**





SMOOTH MUSCLE ACTIN



HMB45

Diagnosis: Lymphangioleiomyomatosis (LAM)

LAM: Overview

- Cystic lung disease caused by infiltration of the lung with smooth muscle
- 2 forms
 - Patients with tuberous sclerosis (TSC)
 - Sporadic form
- Caused by genetic mutations in either of 2 TSC genes
- Associated with pulmonary manifestations, angiomyolipomas, and lymphangioleiomyomas

LAM: Epidemiology

- **Average age at diagnosis: 35 years**
- **Almost entirely restricted to women**

LAM: Pulmonary Manifestations

- **Pulmonary cysts**
- **Pneumothorax**
- **Chylous pleural effusion**
- **Obstructive lung disease**

LAM: Pathology

- **Smooth muscle infiltration of parenchyma, airways, lymphatics, blood vessels**
- **Thin-walled cystic changes**

LAM: Diagnosis

- **Index of suspicion when:**
 - **Young female with a pneumothorax**
 - **Incidental discovery of pulmonary cysts, angiomyolipoma, or lymphangiomyoma**
 - **Unexplained chylous pleural effusion or ascites**
- **Compatible chest CT plus any 1 of the following:**
 - **Angiomyolipoma, lymphangiomyoma, chylous pleural effusion**
 - **VEGF greater than 800 pg/ml**
 - **Lung biopsy**

LAM: Management

- **Sirolimus for patients with a FEV1 less than 70%**

Key Points About LAM

- **Cystic lung disease in females**
 - **Consider in any young female with pulmonary cysts +/- pneumothorax**
- **Diagnosed via radiology, serum VEGF level, +/- biopsy**
- **Sirolimus is the treatment for patients with impaired pulmonary function**

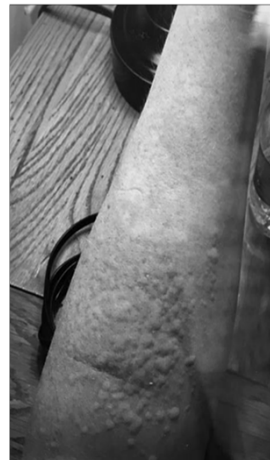Lung Diseases They Didn't Teach You About In Medical School

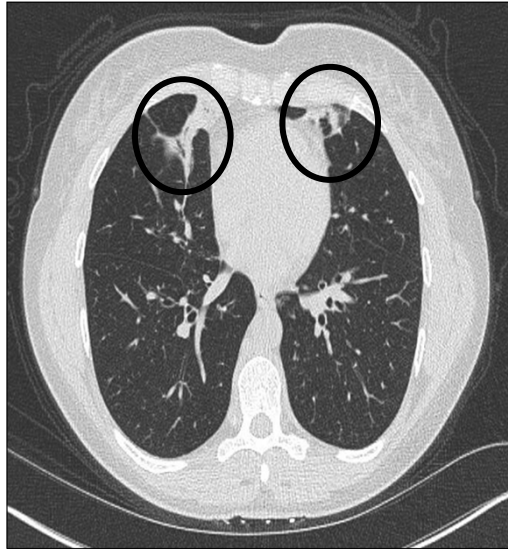
James Allen, MD
Medical Director, The Ohio State University Wexner
Medical Center East Hospital
Professor of Internal Medicine
Division of Pulmonary and Critical Care Medicine
The Ohio State University Wexner Medical Center

Case #8

- 44 year-old woman with recurrent pneumonia for 5 months
- Intermittent fevers to 103°
– resolve with prednisone and antibiotics
- Episodic urticarial skin rash
- Testing:
 - Spirometry = moderate obstruction
 - IgE elevated at 6,204
 - Eosinophil count elevated at 780

Left forearm





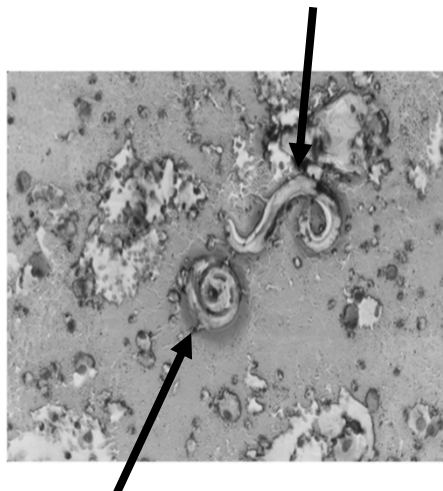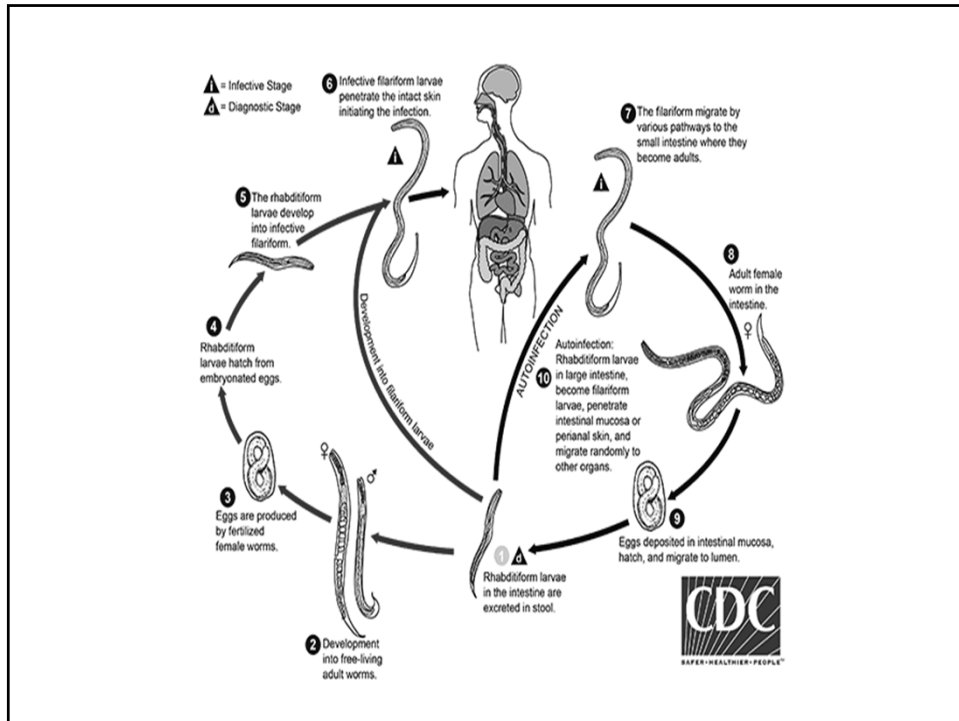
Strongyloides Symptoms

Systemic:

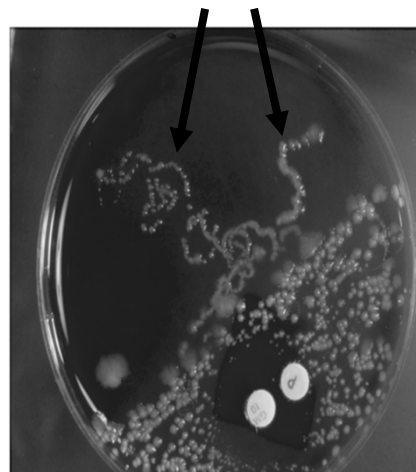
- Skin Rash
- Abdominal Pain
- Diarrhea
- Increased blood eosinophil count

In the lung:

- Wheezing
- Recurrent pneumonias (especially gram negative)
- Migratory pulmonary infiltrates
- Cough
- Hemoptysis



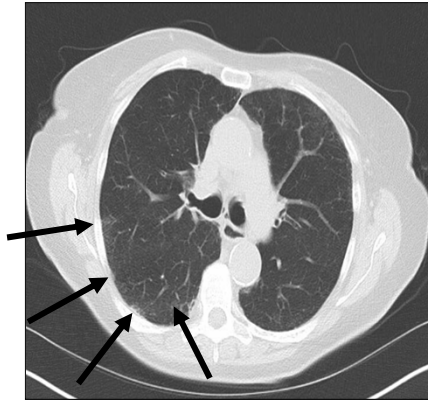
Bronchoalveolar Lavage:
Low Power Photomicrograph



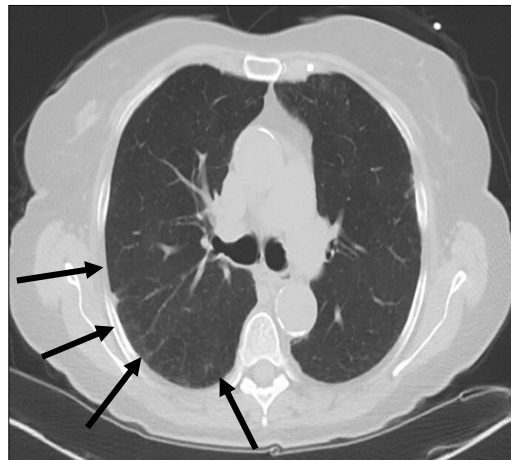
Agar Culture Plate:
Larvae Leaving Bacterial Trails

77 year-old woman with Takayasu's arteritis

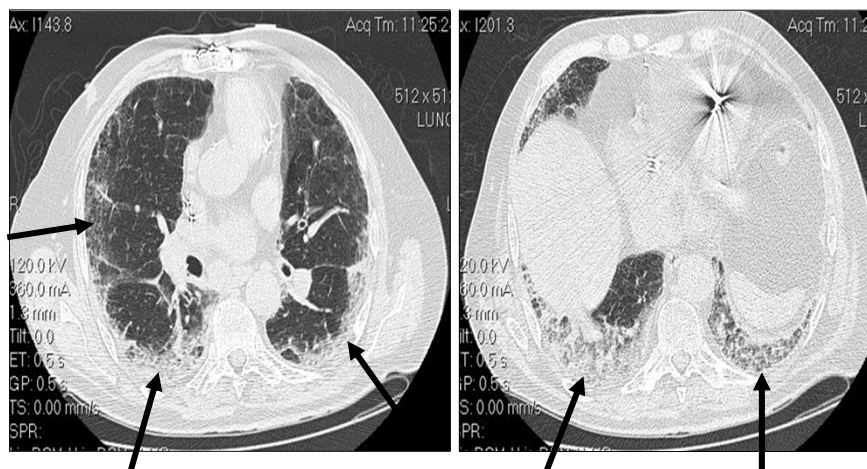
- Previously treated with methotrexate
- Now with cough and dyspnea for 3 years
- No improvement with inhalers or prednisone
- Testing:
 - PFTs = severe obstruction
 - Eosinophil count 1,200



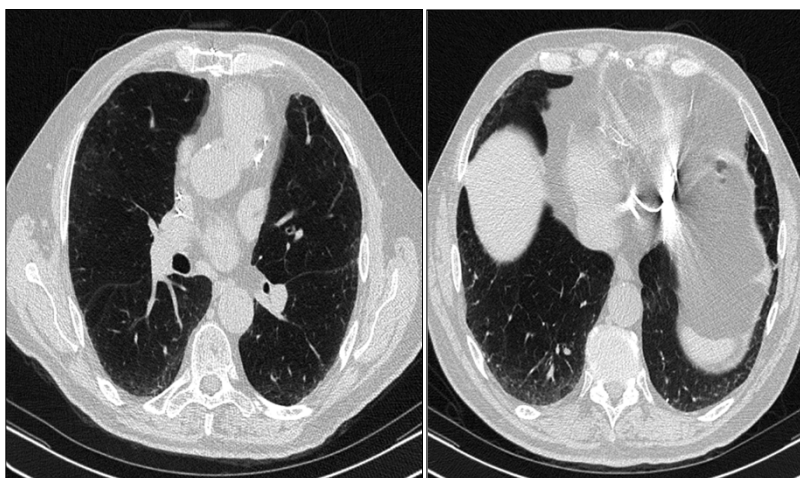
After treatment with ivermectin



79-year old man with recurrent pneumonias and peripheral blood eosinophilia

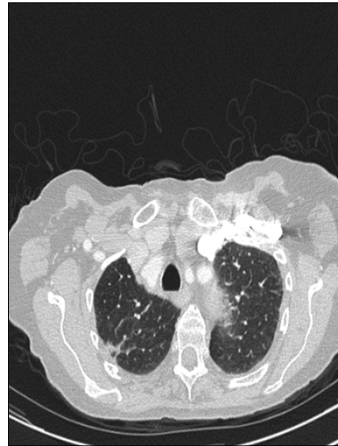

After treatment with ivermectin



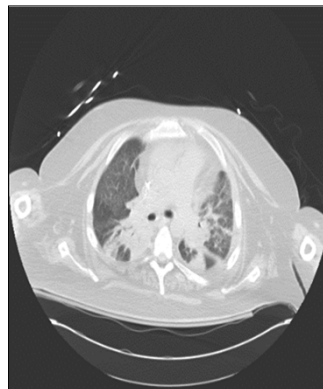Strongyloides is sneaky

- 87 year old mother of OSU physician
- Recurrent “colitis”, eosinophilia, pulmonary infiltrates and cough for 20 years
- Positive anti-strongyloides antibody
- Symptoms resolved with ivermectin



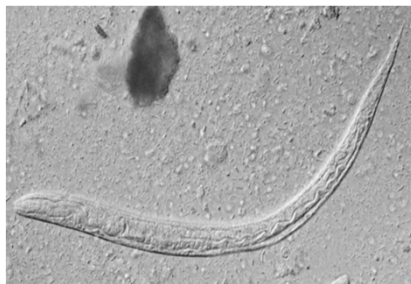You'll miss it if you only order the regular stool O&P exam

- 35-year old man
- Multiple ICU admissions
- Recurrent fevers & pseudomonas pneumonia
- Persistent fevers and blood eosinophilia (up to 2,700)
- Stool O&P negative (antigenic)
- Strongyloides antibody positive



Key Points About Strongyloides:

- **Worms are everywhere**
- **Non-resolving pneumonia + peripheral eosinophilia = order a Strongyloides antibody test**



Lung Diseases They Didn't Teach You About In Medical School

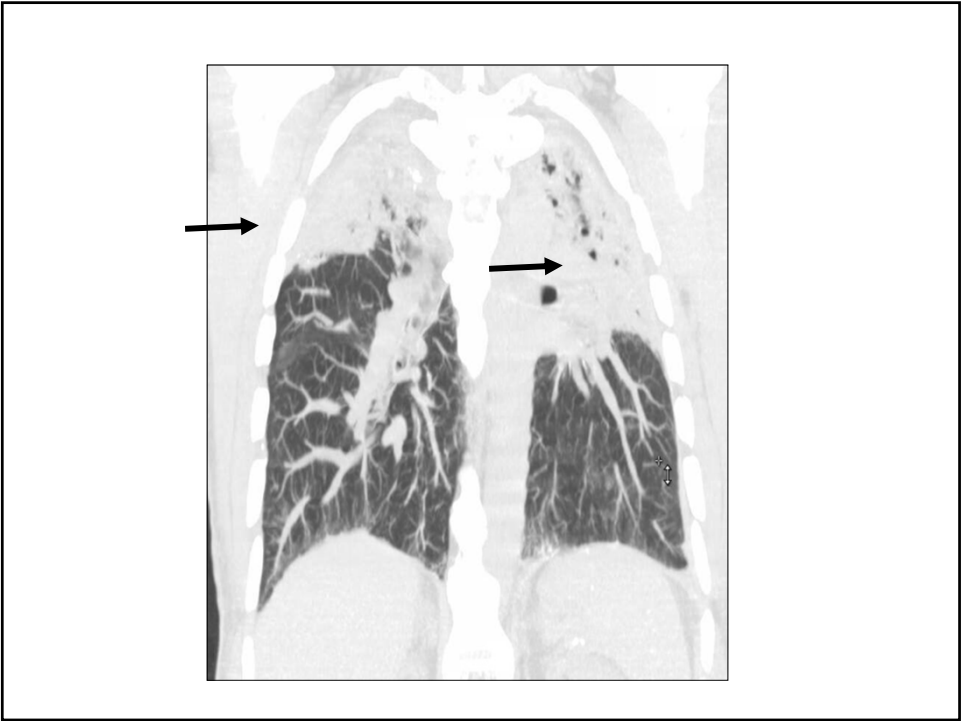
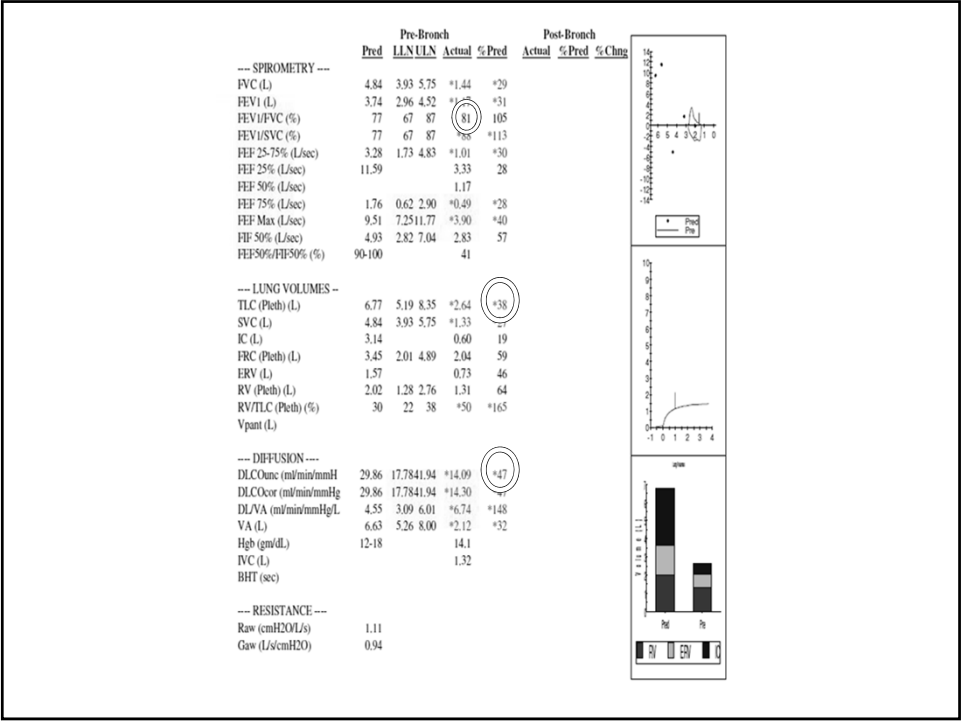
**Derrick Herman, MD
Assistant Professor
Department of Internal Medicine
Division of Pulmonary, Allergy, Critical Care
and Sleep Medicine
The Ohio State University Wexner Medical Center**

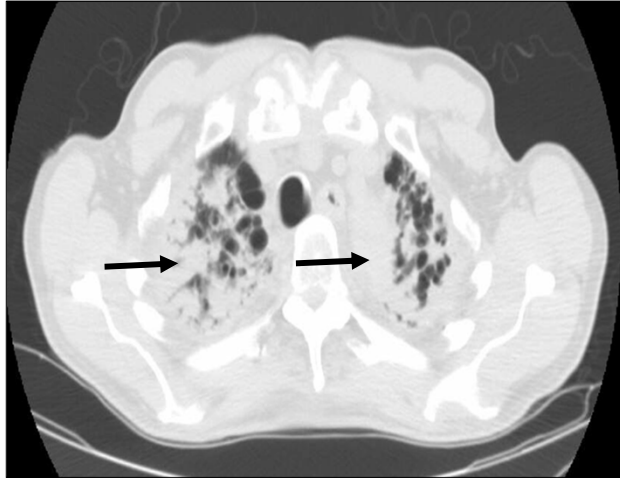
Case #9

- 63 year old man
- Dyspnea and nonproductive cough for 8 months
- Past medical history:
 - Psoriatic arthritis
 - Lupus, recently diagnosed
- Medications:
 - Methotrexate for 3 years; stopped 5 years prior
 - Prednisone, started 2 months prior

Case #9 (continued)

- Social history: never smoker
- Exam: biapical dry crackles
- Labs:
 - ANA positive
 - All other serological studies negative





Pathology Report

- **Pleuritis**
- **Pleural blebs associated with subpleural fibrobullous disease/scarring in upper and middle lobes.**
- **The etiology of these changes is not apparent**
- **UIP/IPF was considered in the differential; however, the predominance of changes in upper lobe and radiologically apparent sparing of lower lobe argue against that consideration.**

Diagnosis: Pleuropulmonary Fibroeslastosis (PPFE)

PPFE: Overview

- **Upper-lobe-dominant slowly progressive pulmonary fibrosis**
- **1st description in 1992**
- **The name, PPFE, was coined in 2004 and is descriptive**
- **Unknown etiology**
 - **Idiopathic form**
 - **Form associated with lung and bone marrow transplants, chemotherapy, infections, autoimmune diseases**

PPFE: Epidemiology

- **Median age at diagnosis: 53 years**
- **No sex predilection**
- **Smoking not a risk factor**

PPFE: Pulmonary Manifestations

- **Restrictive ventilatory impairment**
- **Interstitial lung disease**
- **Pneumothorax**

PPFE: Radiology & Pathology

- **Radiology**
 - Early bilateral and irregular apical pleural thickening
 - Later reticular and fibrotic parenchymal changes
 - Biapical blebs
- **Pathology**
 - **Fibro:**
 - Fibrous thickening of the visceral pleura
 - Dense intra-alveolar fibrosis
 - **Septal elastosis**
- **Abrupt transition from normal to abnormal tissue**

PPFE: Diagnosis

- **No agreed upon consensus statement**
- **Clinical signs and symptoms, radiology, +/- pathological exam**

PPFE: Management

- **Prognosis is highly variable**
- **No treatment has yet been demonstrated to alter disease progression**
- **Supportive care**
- **Lung transplant**

Key Points About Pleuroparenchymal Fibroelastosis

- **Relatively recently (1992) recognized entity**
- **The diagnostic term is descriptive for radiological and pathological features**
- **No consensus diagnostic criteria**
- **Clinical course variable**
- **No disease modifying treatment**

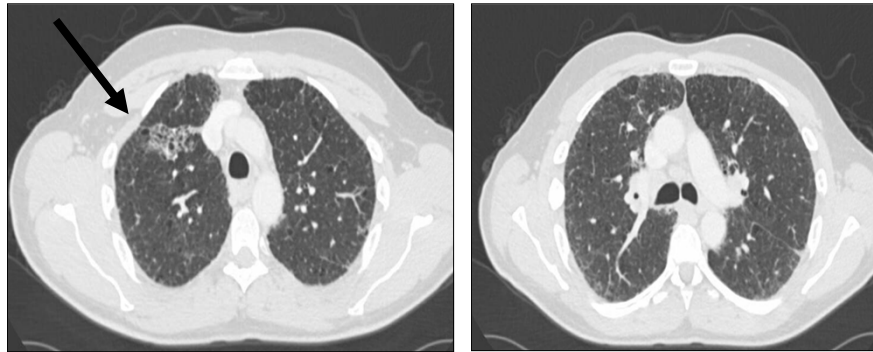
Lung Diseases They Didn't Teach You About In Medical School

James Allen, MD
Medical Director, The Ohio State University Wexner
Medical Center East Hospital
Professor of Internal Medicine
Division of Pulmonary and Critical Care Medicine
The Ohio State University Wexner Medical Center

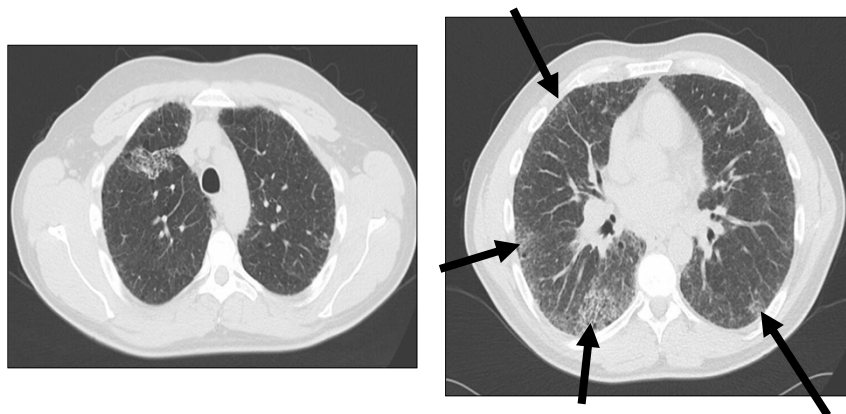
Case #10

- **48 year-old man with cough onset January 2016**
- **Referred for interstitial lung disease evaluation July 2017**
- **Past medical history = HIV (well-controlled)**
- **Family history: Mother & maternal aunt had idiopathic pulmonary fibrosis**
- **Exam: bibasilar dry crackles**
- **BAL: 89% neutrophils (normal < 2%), no cancer**

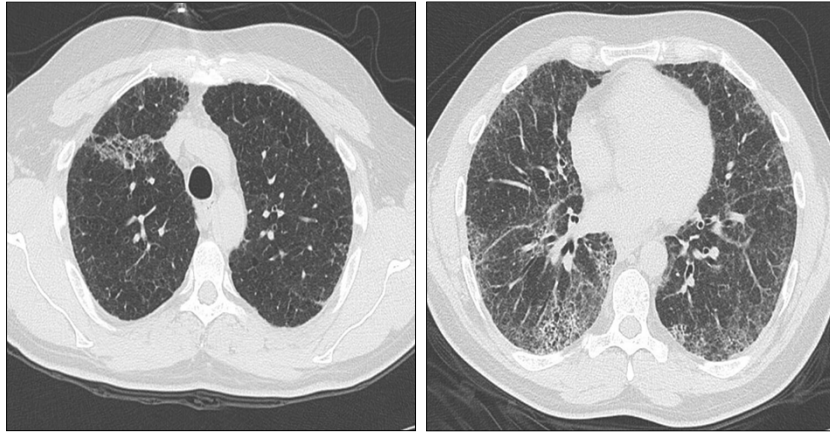
May 2016




August 2016



November 2016

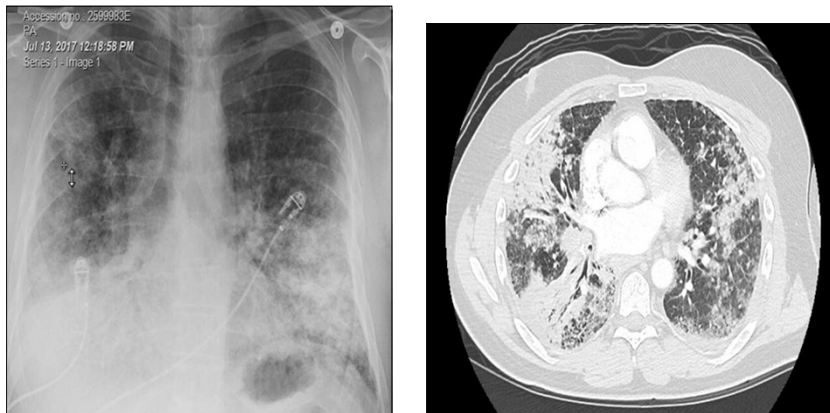


June 2017

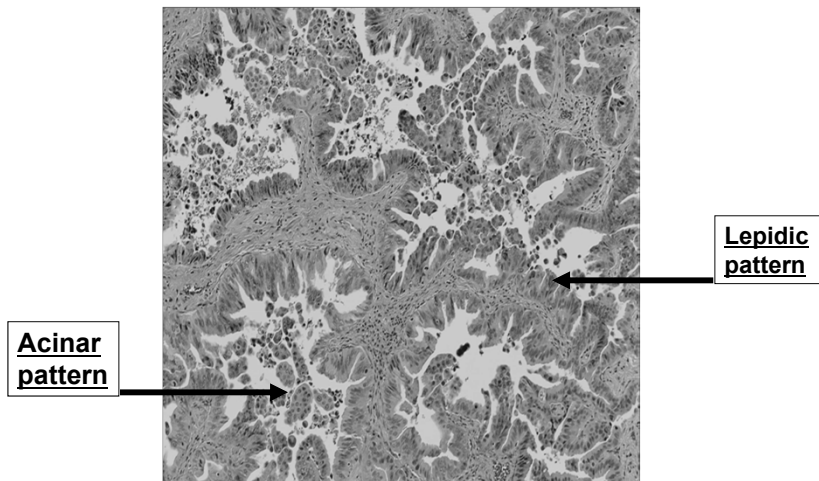


The left image is a chest X-ray (PA view) showing bilateral lung fields with some opacities and a central mediastinal structure. The right image is a cross-sectional CT scan of the chest, showing the lungs, heart, and surrounding structures in grayscale.

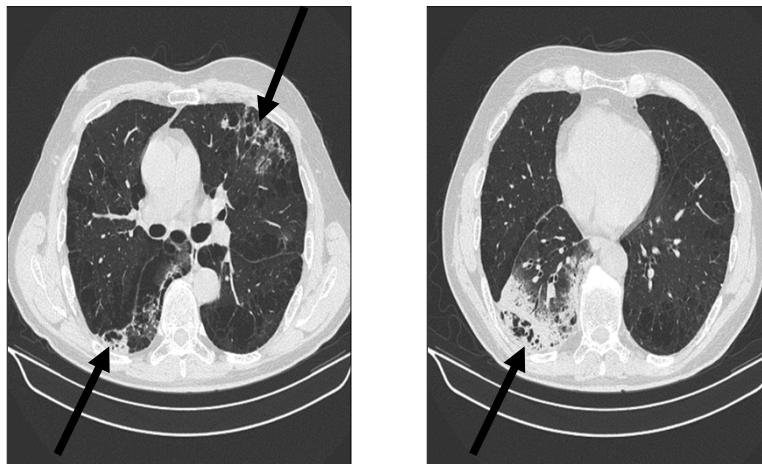
Accession no. Z599933E
PA
Jul 13, 2017 12:18:59 PM
Series 1 - Image 1



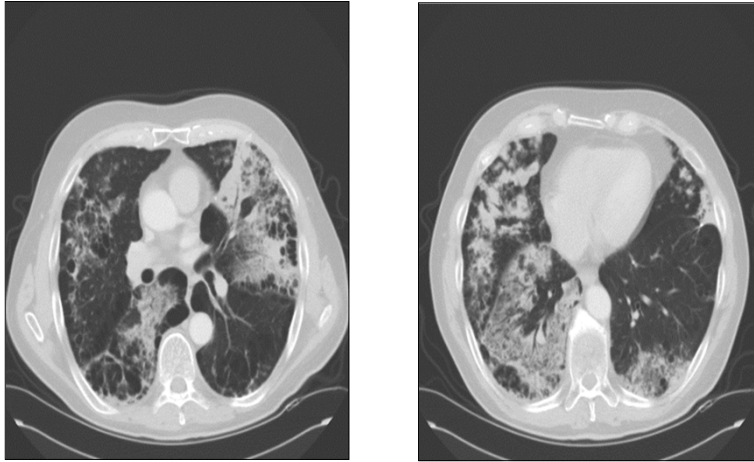
Adenocarcinoma ("bronchoalveolar carcinoma")



Adenocarcinomas can be missed on biopsy

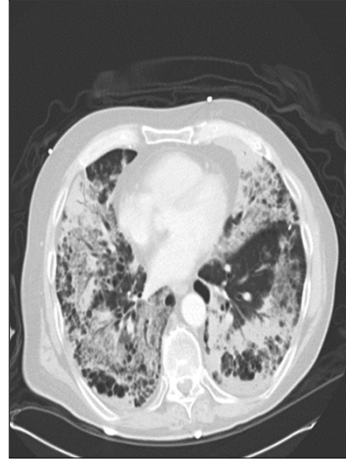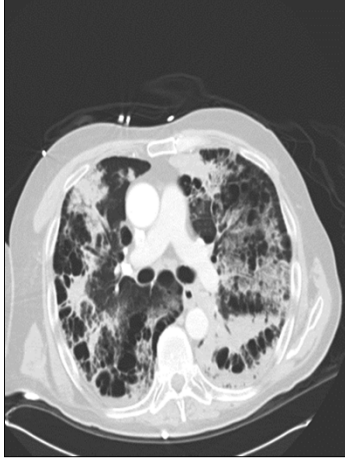


Adenocarcinomas can be missed on biopsy

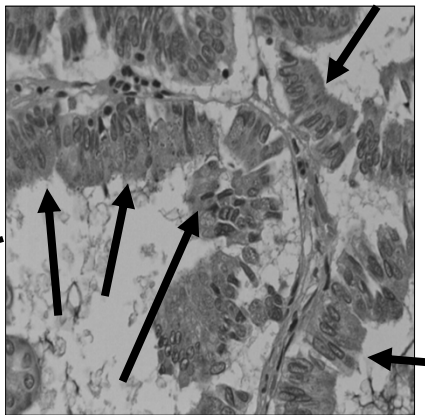
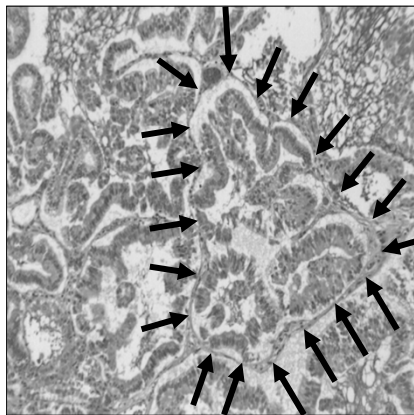


Adenocarcinomas can be missed on biopsy

- **Bronchoscopy #1**
 - BAL – 52% macrophages, 27% neutrophils, 15% lymphocytes, 6% eosinophils; negative AFB, fungal cultures; cytology negative
 - Brushings – negative cytology
 - Transbronchial biopsy – calcified granuloma with histoplasmosis organisms seen; no cancer
- **Bronchoscopy #2**
 - Negative cytology
- **Surgical lung biopsy**
 - Organizing pneumonia (pathologist #1)
 - Hypersensitivity (pathologist #2)
 - Adenomatous hyperplasia (pathologist #3)
 - Organizing pneumonia versus hypersensitivity pneumonitis but no cancer (pathologist #4)
- **Bronchoscopy #3**
 - Transbronchial biopsy = no cancer



Autopsy: Adenocarcinoma



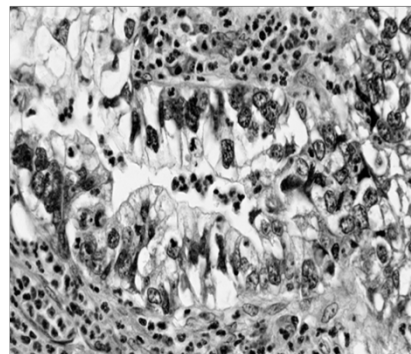
Adenocarcinoma



- Current classification of adenocarcinoma of the lung:
 - Lepidic
 - Acinar
 - Papillary
 - Solid
 - Invasive mucinous
 - Colloid
 - Minimally invasive
 - Adenocarcinoma in situ

Key Points About Adenocarcinoma

- The term “bronchoalveolar carcinoma” is no longer used
- Well-differentiated adenocarcinomas can be difficult to diagnose
- Cytology and even surgical lung biopsies can be false-negative
- Adenocarcinoma can mimic many interstitial lung diseases
- Driver mutations determine treatment choices



References

- Bonifazi M, Montero MA, Renzoni EA. Idiopathic Pleuroparenchymal Fibroelastosis. *Curr Pulmonol Rep* 2017;6:9-15.2.
- Campbell SN, Rubio E, Loschner AL. Clinical review of pulmonary manifestations of IgG4-related disease. *Ann Am Thorac Soc* 2014;11:1466-75.
- Gupta N, Finlay GA, Kotloff RM, et al. Lymphangioleiomyomatosis Diagnosis and Management: High-Resolution Chest Computed Tomography, Transbronchial Lung Biopsy, and Pleural Disease Management. An Official American Thoracic Society/Japanese Respiratory Society Clinical Practice Guideline. *Am J Respir Crit Care Med* 2017;196:1337-48.
- Gupta N, Vassallo R, Wikenheiser-Brokamp KA, McCormack FX. Diffuse Cystic Lung Disease. Part I. *Am J Respir Crit Care Med* 2015;191:1354-66.
- Gupta N, Vassallo R, Wikenheiser-Brokamp KA, McCormack FX. Diffuse Cystic Lung Disease. Part II. *Am J Respir Crit Care Med* 2015;192:17-29.
- Kamisawa T, Zen Y, Pillai S, Stone JH. IgG4-related disease. *Lancet* 2015;385:1460-71.
- Lega JC, Reynaud Q, Belot A, Fabien N, Durieu I, Cottin V. Idiopathic inflammatory myopathies and the lung. *Eur Respir Rev* 2015;24:216-38.
- McCormack FX, Gupta N, Finlay GR, et al. Official American Thoracic Society/Japanese Respiratory Society Clinical Practice Guidelines: Lymphangioleiomyomatosis Diagnosis and Management. *Am J Respir Crit Care Med* 2016;194:748-61.
- Morisset J, Johnson C, Rich E, Collard HR, Lee JS. Management of Myositis-Related Interstitial Lung Disease. *Chest* 2016;150:1118-28.
- Reddy TL, Tominaga M, Hansell DM, et al. Pleuroparenchymal fibroelastosis: a spectrum of histopathological and imaging phenotypes. *Eur Respir J* 2012;40:377-85.
- Watanabe K. Pleuroparenchymal Fibroelastosis: Its Clinical Characteristics. *Curr Respir Med Rev* 2013;9:299-37.