

Common Upper Extremity Conditions Part 1: Compression Neuropathies

Hisham Awan, MD
Director, OSU Hand and Upper Extremity Center
Associate Professor, Hand and Upper Extremities
Program Director, Hand and Upper
Extremity Fellowship
The Ohio State University Wexner Medical Center

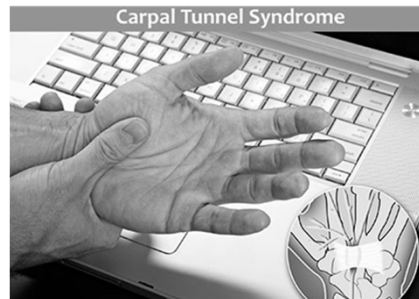
Compression Neuropathies of the Upper Extremity

- **Objectives**
 - Discuss Pathology of compressive Neuropathies
 - Discuss the most common UE nerve compression syndromes
 - Carpal Tunnel Syndrome (CTS)
 - Cubital Tunnel Syndrome (CuTS)
 - Ulnar Tunnel Syndrome



Compression Neuropathy Defined

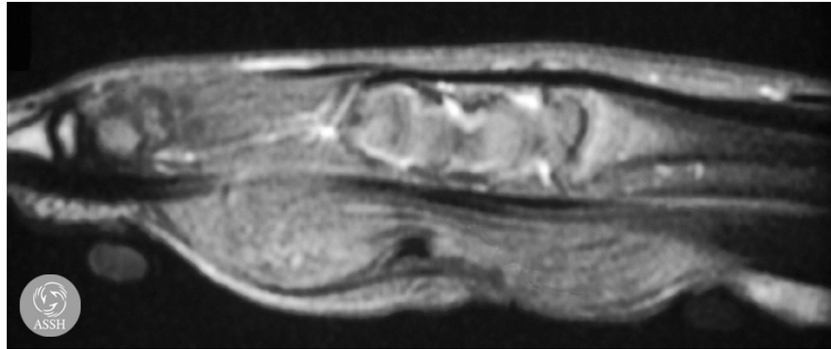
- Dysfunction of a peripheral nerve caused by pressure
- Symptoms manifested
 - Sensory
 - Motor
 - Autonomic



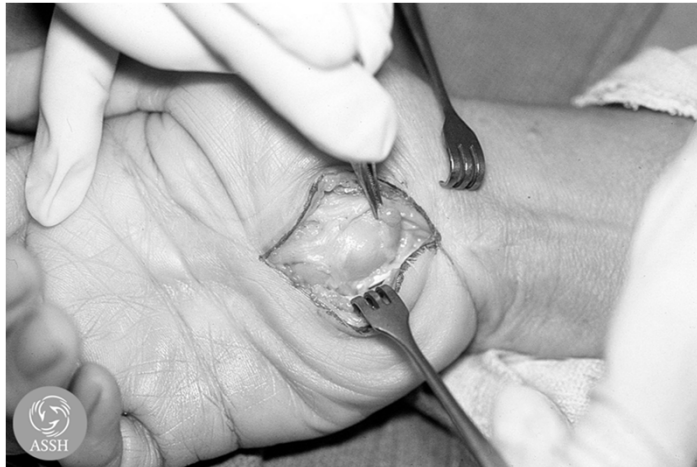Background

- Nerve compression occurs at many locations
 - Intrinsic Compression
 - Intraneural lipoma
 - Schwannoma/Neurofibroma
 - Hamartoma
 - Extrinsic Compression
 - Swelling
 - Fascia
 - Masses (ganglion, aberrant anatomy)
- Most Common: Carpal Tunnel
 - Ulnar, radial, other branches also possible

Intrinsic Compression - Lipoma of Median Nerve

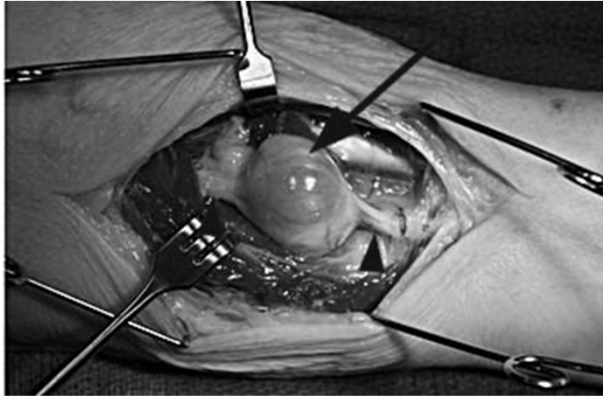


Courtesy of ASSH

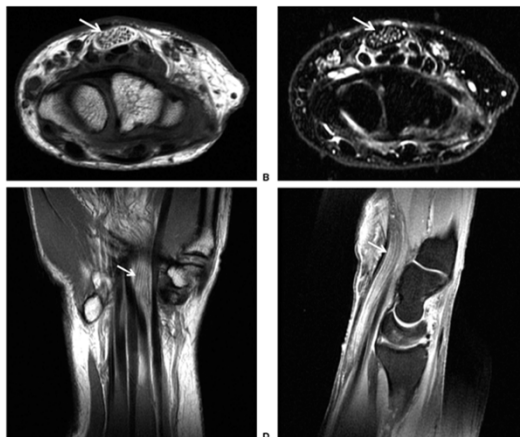


Courtesy of ASSH

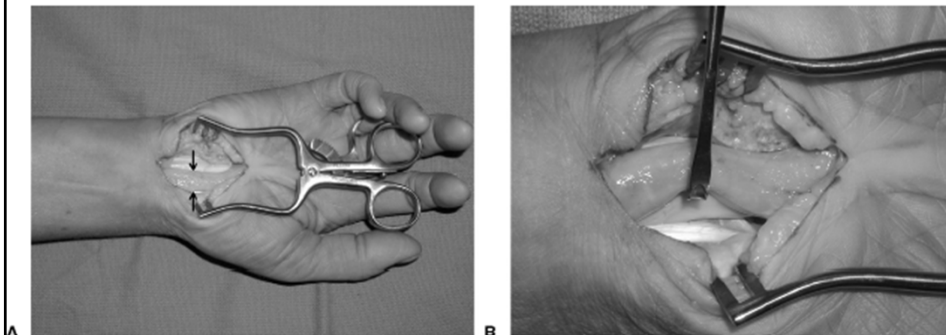
Median Nerve Schwannoma



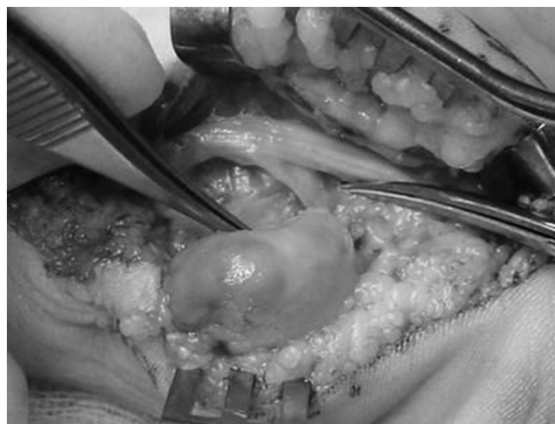Lipofibromatous Hamartoma



Lipofibromatous Hamartoma

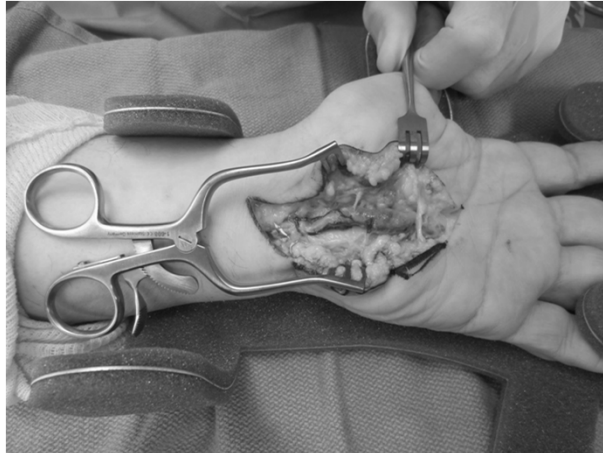


Extrinsic Compression



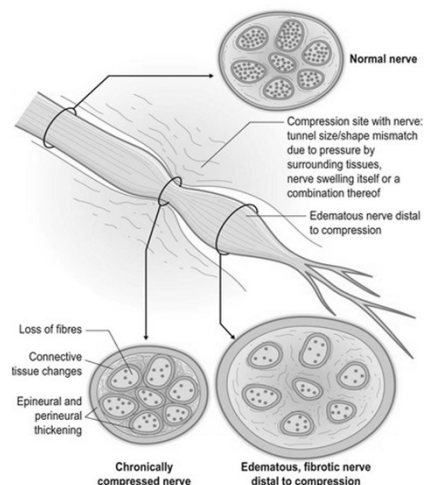
Guyon's Canal Ganglion

Ulnar Artery Thrombosis



Nerve Compression Pathophysiology

- **Altered Signal Conduction:**
 - Ischemia and impaired venous return
 - Intraneural edema
 - Decreased axoplasmic transport
 - Membrane instability
 - Fibrosis



Risk Factors

- **Genetics*****
- **Obesity**
- **Hypothyroidism**
- **Diabetes**
- **Pregnancy**
- **Renal disease**
- **Inflammatory arthritis**
- **Acromegaly**
- **Mucopolysaccharidosis**
- **Amyloidosis**
- **Multiple myeloma**
- **Gender (Women>Men)**
- **Age (> 50 y/o)**
- **Smoking**
- **Occupational exposure****

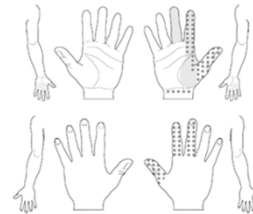


Pathophysiology: Multifactorial

- **Systemic disease creates “at risk” environment**
 - **Diabetes, hypothyroidism, smoking**
 - **Microvascular disease**
- **Symptoms develop when pressure exceeds nerve threshold**

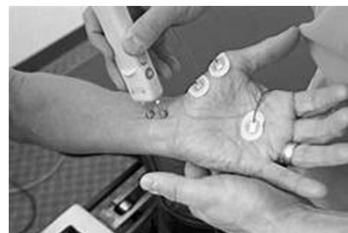General Principles of Diagnosis

- History & Physical
- Testing: No test is 100% specific and sensitive
 - EMG/NCS
 - Ultrasound
 - Hand diagrams
 - Static 2-point discrimination
 - Semmes-Weinstein
 - Provocative maneuvers
 - Physical findings (atrophy, clawing, etc.)



General Principles: EMG/NCS

- Not always positive in early stages
- False negative results may occur
- Operator dependent
- Allows localization of lesion
- Can follow progression
- Values may never normalize after decompression

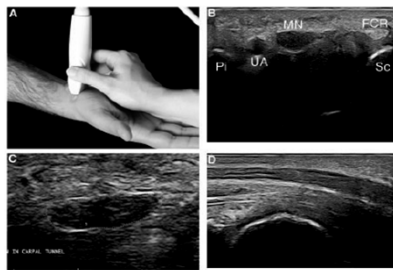


Imaging

- **Generally of Limited Use**
- **Ultrasound:** becoming more popular
- **Plain Radiographs:** 2 views (orthogonal) to rule out:
 - **Post-traumatic deformity**
 - **Arthritic changes**
- **CT or MRI**
 - **Rarely indicated**
 - **Rule out suspected soft tissue mass**
 - **Rule out occult fractures**

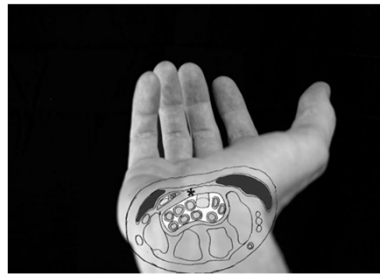Ultrasound

- **Median Nerve enlargement > 10 mm at CTS inlet**
- **Sensitivity as high as 97.9%**
- **Can also be used to guide injection**



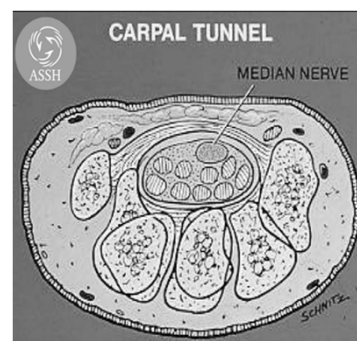
Carpal Tunnel Syndrome

- Most common compressive neuropathy
- Affects .1-10% of the general population
- 200,000+ surgeries performed annually



Anatomy of the Carpal Tunnel

- Contents:
 - Median nerve
 - FDP (flexor digitorum profundus) X 4
 - FDS (flexor digitorum superficialis) X 4
 - FPL (flexor pollicis longus)



Courtesy of ASSH

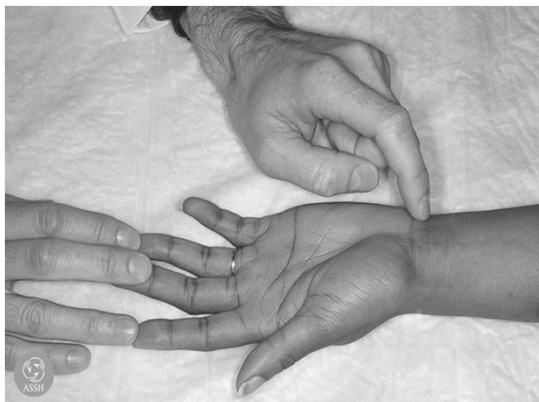Symptoms of CTS

- Numbness, paresthesia in median distribution
 - Worse with work or at night
 - Relieved by shaking hand, dependent positioning
 - May include ulnar digits
 - May radiate up forearm or even to shoulder
- Swelling of hand
- Weakness, clumsiness, dropping objects



Signs of CTS

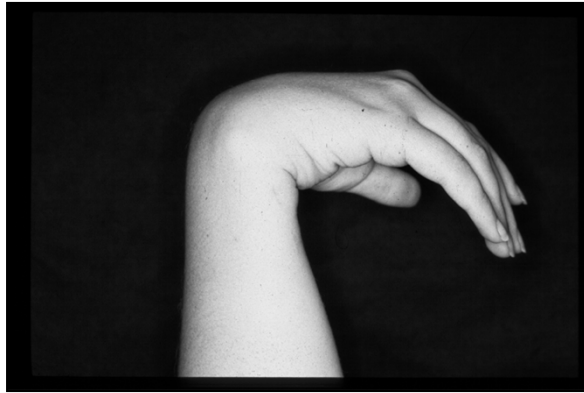- Tinel's test



Courtesy of ASSH

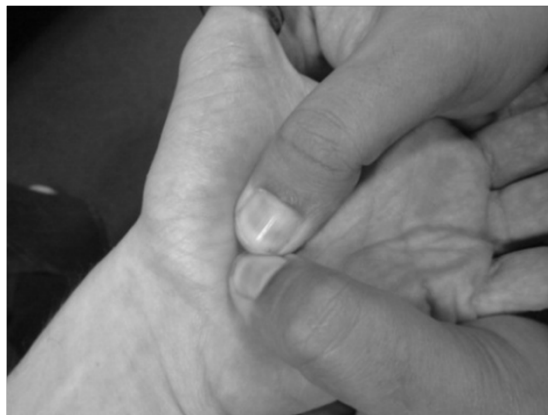Signs of CTS

- Phalen's test



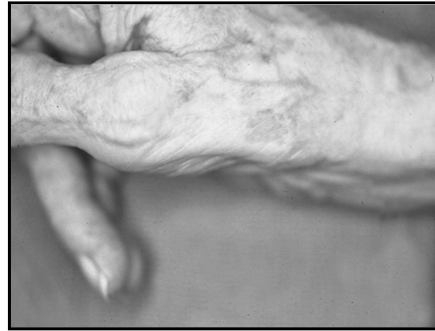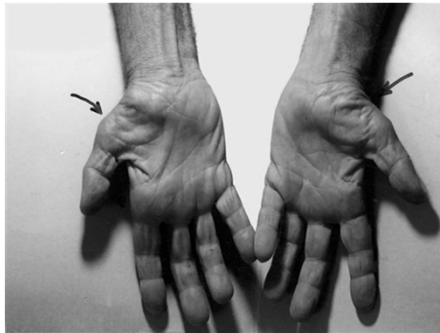
Signs of CTS

- Durkan's Test



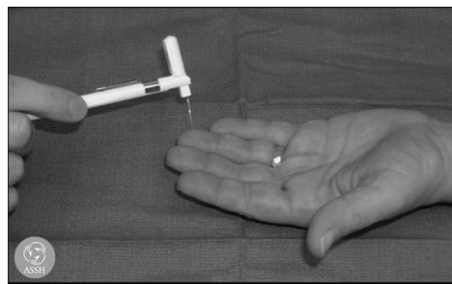
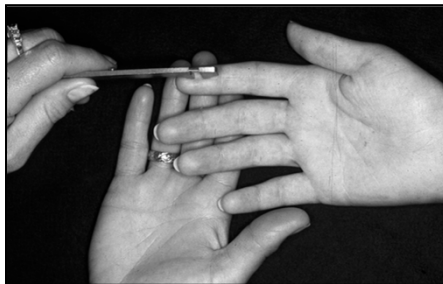Signs of CTS

- Thenar muscle wasting



Sensory Testing for CTS

- 2-point discrimination
- Monofilament
- Vibration



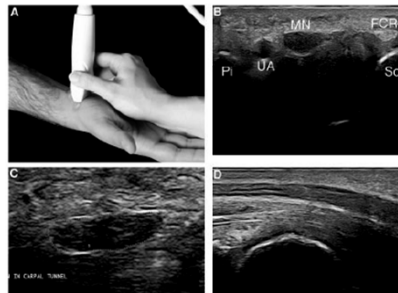
Courtesy of ASSH

CTS - Diagnosis

	Sensitivity	Specificity	
Phalen	10-88%	47-100%	
Tinel	26-79%	40-100%	
Durkan	87%	90%	
Semmes-Weinstein	Up to 91%	Up to 80%	Palumbo + Szabo, Hand Clin, 18:269-77, 2002

Diagnostic Testing

- Nerve conduction study/EMG
 - Motor latency 4.5 ms or 1 ms > opposite hand
 - Sensory latency 3.5 ms or 1 ms > opposite hand
- Ultrasound

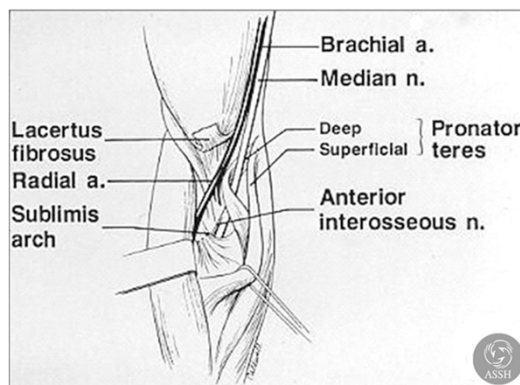


NCS vs Ultrasound

	Pros	Cons
NCS/EMG	R/O other pathology Can compare serial exams (pre and post surgery) Indicates severity	Painful False negative
Ultrasound	Can be done at same visit in office Can use to guide injections	Does not evaluate other causes Operator dependent

Median Nerve Compression: Differential Diagnosis

- **Peripheral Neuropathy**
- **Cervical Spine**
- **Thoracic Outlet**
- **Arm/Forearm**
 - **Ligament of Struthers**
 - **Lacertus Fibrosis**
 - **Pronator Teres**



Courtesy of ASSH

CTS 6 Diagnostic Criteria

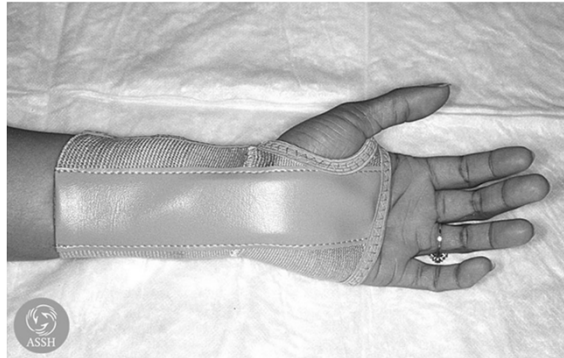- 1) Numbness in the Median nerve distribution**
- 2) Nocturnal numbness**
- 3) Weakness/Atrophy of the Thenar musculature**
- 4) Tinel's sign**
- 5) Phalen's test**
- 6) Loss of 2-point discrimination**

Carpal Tunnel Grading

- **Mild**
 - Duration < 1 year
 - Intermittent numbness
 - Normal sensory testing
 - No weakness or atrophy
 - Minimal NCV changes, no denervation
- **Moderate**
 - Continuous numbness, paresthesias
 - Increased threshold on sensory tests
 - Increased distal motor latency
- **Severe**
 - Persistent loss sensory+ motor function
 - Thenar atrophy

Treatment of CTS

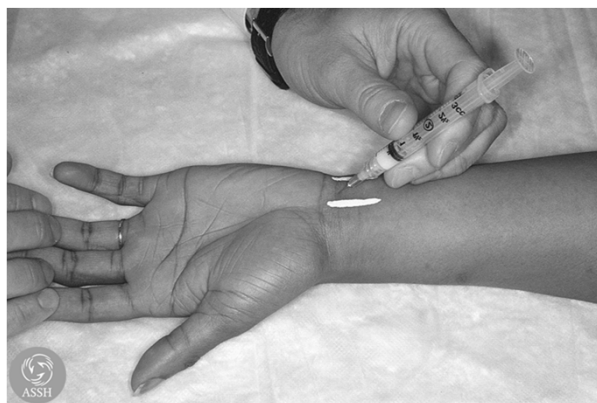- **Splint**



Courtesy of ASSH

Treatment of CTS

- **Injection of Steroid**



Courtesy of ASSH

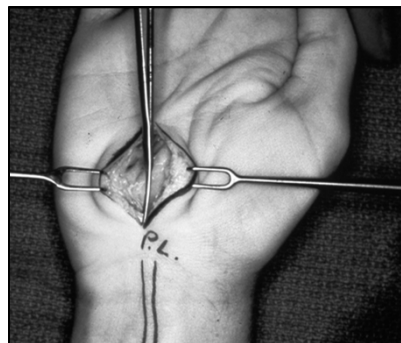
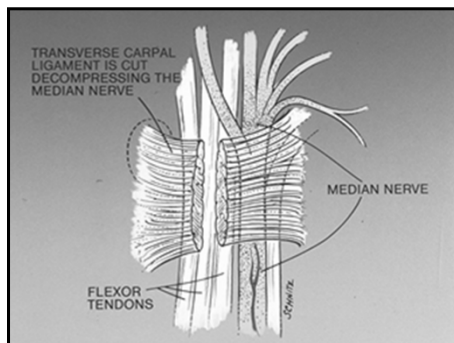
CTS – Predictors of Outcome with Conservative Treatment

- Factors – Age > 50 yrs, Duration sxs > 10 mo, Constant paresthesias, Stenosing tenosynovitis, Phalen's + in < 30 s (Kaplan et al, *JHS 15B*, 1990)

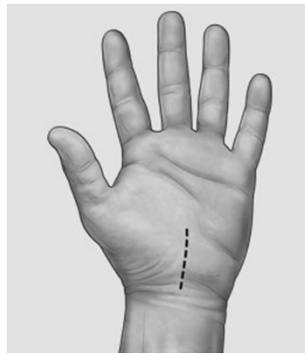
Factors Present	% Success
0	66
1	40
2	17
3	7
4	0
5	0

Surgical Treatment of CTS

- Open Carpal Tunnel Release



Open vs Endoscopic CTR

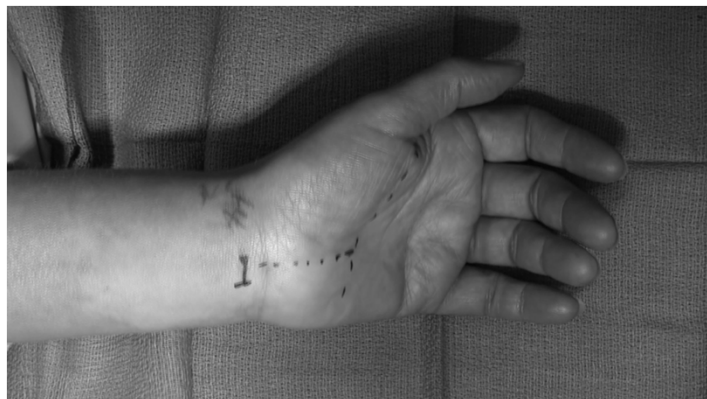

Open Surgery



Endoscopic Surgery

Endoscopic Carpal Tunnel Release



Open vs Endoscopic CTR

- 2-3 week earlier return to work with endoscopic versus open CTR
- No substantial difference in final outcome
- No difference in Complication Rates
 - Brown et al, *JBJS (Am)* 1993.
 - Trumble et al, *JBJS (Am)* 2002.

What Are Hand Surgeons Doing?


SCIENTIFIC ARTICLE

Trends in Carpal Tunnel Surgery: An Online
Survey of Members of the American Society
for Surgery of the Hand

Justin J. Munns, MD, Hisham M. Awan, MD

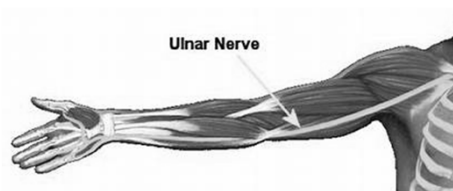
- 70% of hand surgeons who responded use Open or Mini Open CTR
- 26% perform endoscopic release
- Most under local with sedation, but 11% use general anesthesia
 - Only 8% use local only

Results



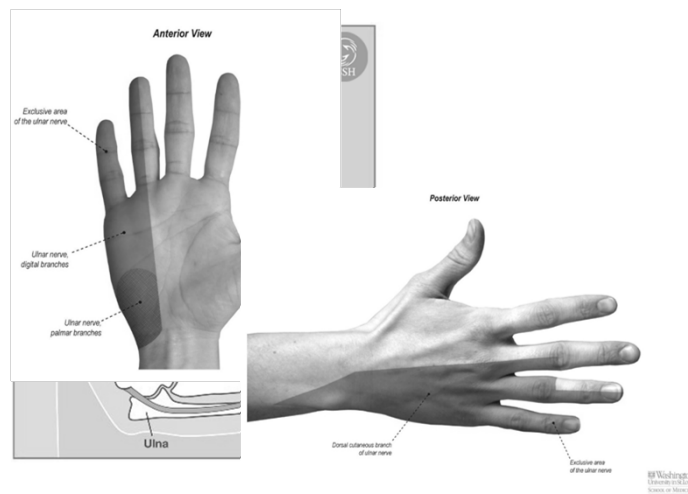
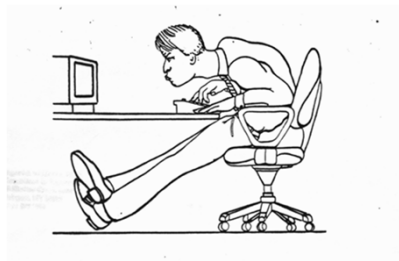Ulnar Nerve Compression

- Cubital Tunnel**
 - Compression:** Most commonly
 - Traction:** Not well understood
 - Subluxation:** Typically younger patients
- Guyon's Canal**
 - Compression at 3 Sites**
 - Idiopathic**
 - Hook of Hamate Fracture**
 - Mass/Ganglion Cyst**



Cubital Tunnel Syndrome

- Clinical syndrome of numbness, pain, and weakness associated with compression of the ulnar nerve at the elbow.
- C8-T1
- Terminal continuation of the medial cord of the brachial plexus

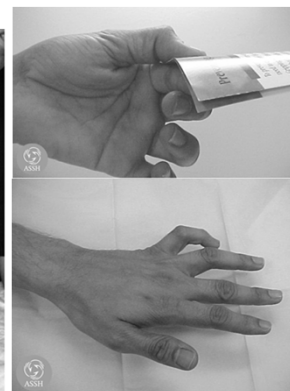
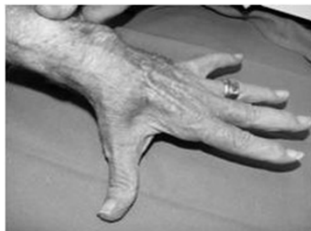
History and Physical: Cubital Tunnel

- **Symptoms**
 - Numbness/tingling
 - Night pain
 - Elbow flexion
 - Snapping at elbow
 - Pain at Medial Elbow
 - Weakness with grip/pinch
- **Late Symptoms/Signs:**
 - Persistent Numbness
 - Progressive weakness
 - Intrinsic Wasting
 - Clawing

History and Physical

- **Exam**
 - Tinel' s
 - Elbow flexion test
 - Weakness: Froment's Sign
 - Intrinsic muscle atrophy
 - Ulnar Clawing/Papal Sign



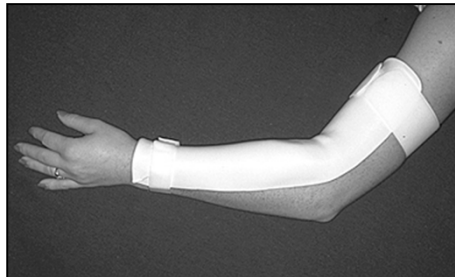
Courtesy of ASSH

Electrodiagnostic Studies

- Inching technique to localize site of compression
- Confirm diagnosis
- Evaluate degree of denervation
- Evaluate degree of conduction delay
- Rule out proximal involvement
 - Pancoast tumor, cervical radiculopathy, brachial plexopathy, thoracic outlet

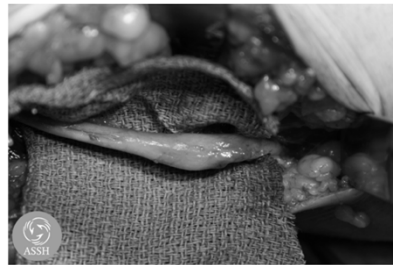
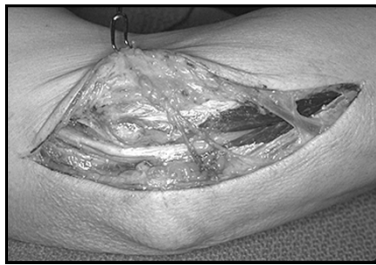
Treatment: Conservative

- Nighttime pillow/extension splinting
- Elbow pad/Avoidance direct trauma, compression
- Activity Modifications

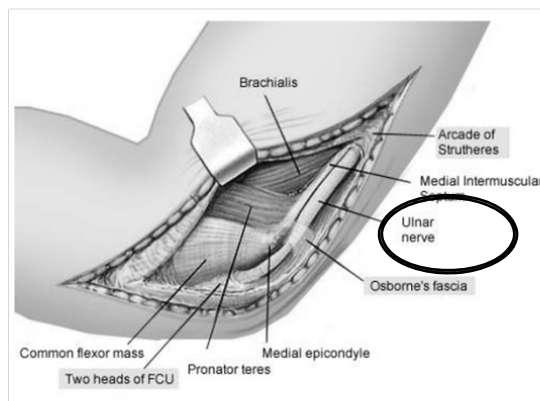


Treatment: Surgery

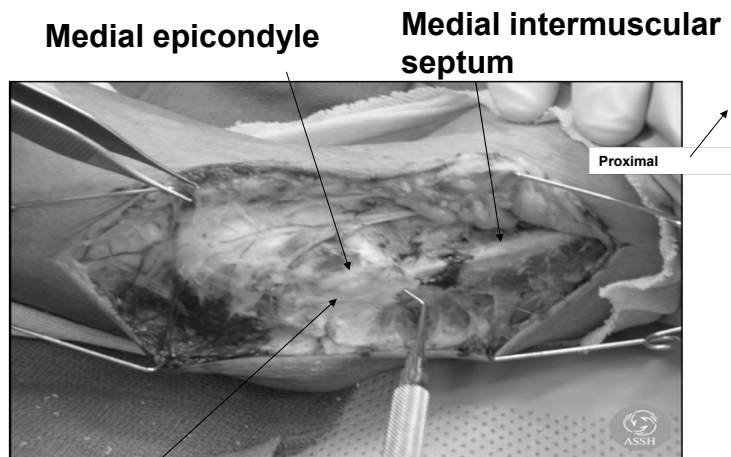
- Cubital tunnel release with or without transposition of the nerve
 - Submuscular or Subcutaneous



Treatment: Surgical Sites of Compression

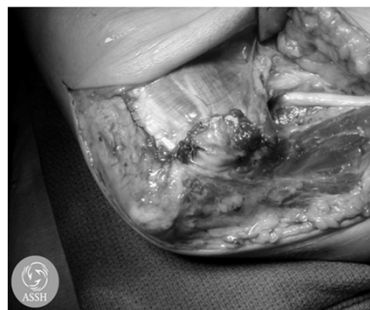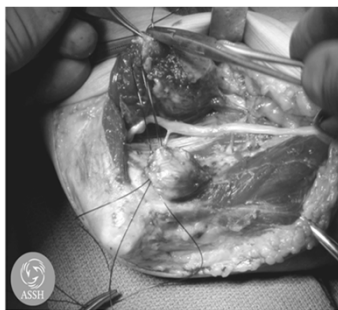


Treatment: Surgery



Cubital tunnel containing ulnar nerve, posterior to the medial epicondyle

Treatment: Surgery – Submuscular Transposition



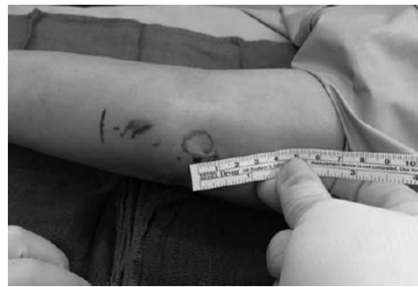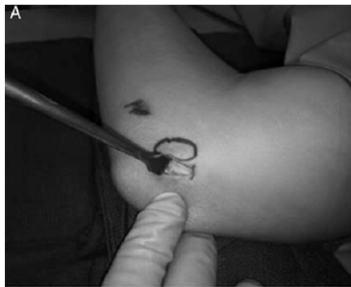My Preference – Mini Incision In Situ Release

SPECIAL TECHNICAL ARTICLE

*Techniques in
Orthopaedics Dec 2016*

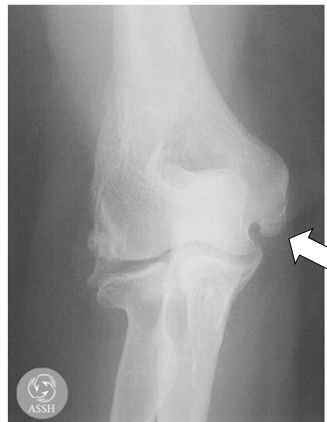Mini-Open In Situ Cubital Tunnel Release

Julie Balch Samora, MD, PhD and Hisham M. Awan, MD†*

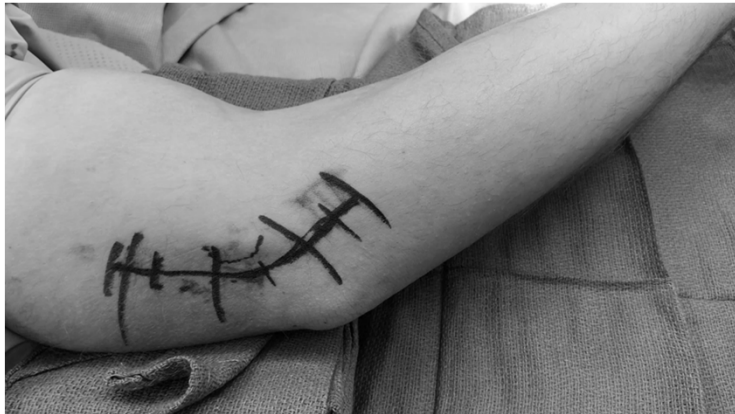

Indications for Transposition

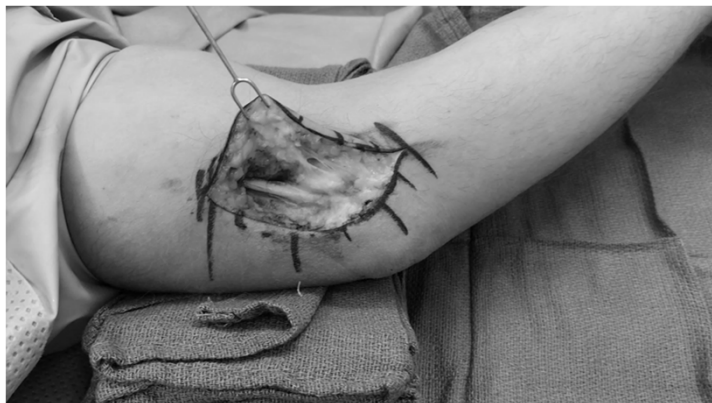- Significant Subluxation
- Osteophytes in Cubital Tunnel
- Part of Larger Operation
 - Fixation of Fractures
 - Elbow Arthroplasty



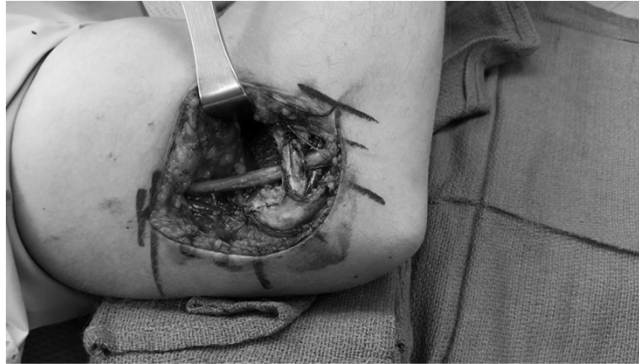Ulnar Nerve Subluxation



Ulnar Nerve Subluxation

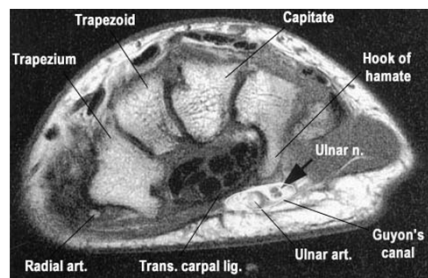


Ulnar Nerve Subluxation – s/p Transposition



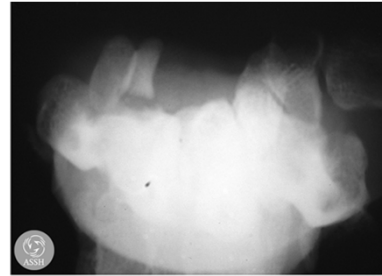
Ulnar Tunnel Syndrome

- Compression of the nerve over Guyon's canal
- Symptoms in fingers but not in dorsal hand
- May present as isolated motor weakness, or paresthesias, or combined sensory/motor



Ulnar Tunnel Syndrome

- Ganglion cysts- most common
- Ulnar Artery Aneurysm or thrombus
- Hamate Hook Fracture
- Lipoma
- Repetitive trauma (bicyclists)

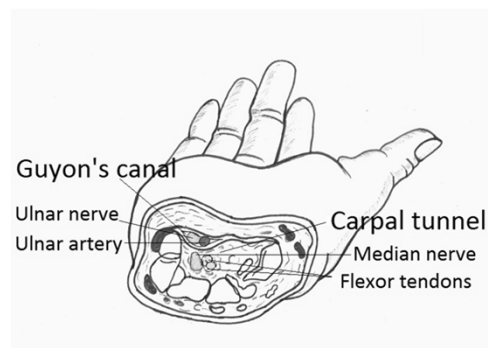


Courtesy of ASSH

C

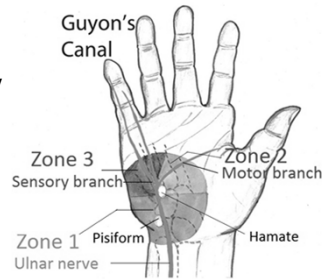
Borders of Canal

- Floor = flexor retinaculum
- Ulnar Border = Pisiform & Abd. Dig. Minimi
- Radial Border = Hook of the Hamate
- Roof = Volar Carpal Lig. & palmaris brevis



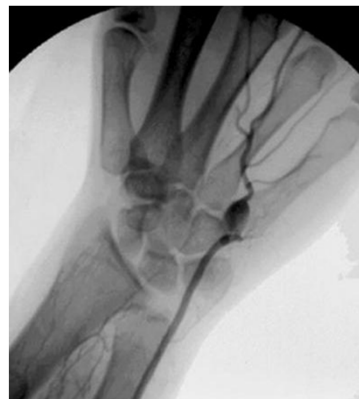Guyon's Canal Zones

- **Zone 1 = proximal to bifurcation**
 - Ganglions (most common), anomalous muscle
 - Fractures of hook of hamate
- **Zone 2 = deep motor branch only**
 - Hook of hamate fracture, ganglion
- **Zone 3 = superficial sensory branch only**
 - Ulnar artery thrombosis
 - Synovial inflammation



Nonsurgical Treatment of Ulnar Tunnel Syndrome

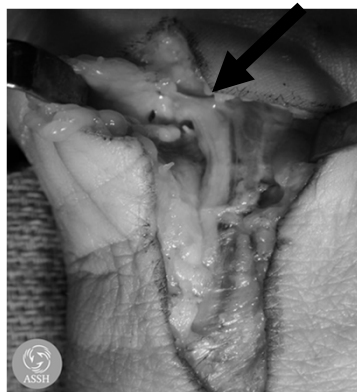- Diagnostic Imaging to evaluate vascular lesion- MRA, Doppler, Angiogram, etc.
- MRI/CT scan to r/o masses, fractures
- Activity modification- avoid pressure
- Wrist splints, NSAID's
- Padded gel gloves



Surgical Decompression of Guyon's Canal

- Indirect decompression done by CTR alone
- Dissection from proximal to distal to protect branching pattern
- Evaluate deep motor branch of ulnar nerve
- Protect palmar cutaneous branch of ulnar nerve
- Removal of mass, pressure

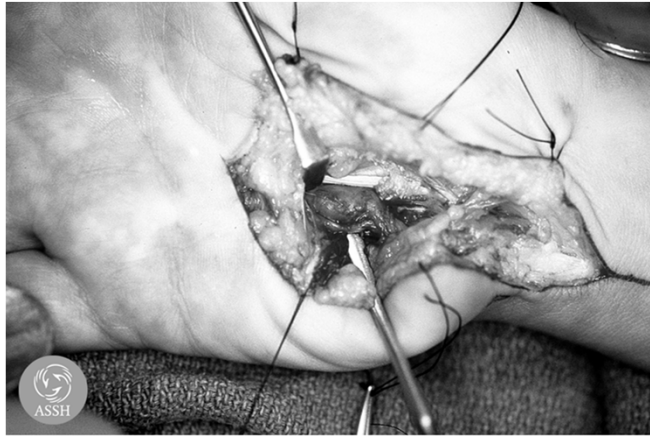Ulnar Tunnel Syndrome: Guyon's Canal



Right Palm/ Guyon's Canal

Courtesy of
ASSH

Ganglion in ulnar tunnel



Courtesy of ASSH

**Return to work and
return to activities after
surgery for
compression
neuropathy**

Long-term prognosis after surgery

Non-osseus Conditions of the Upper Extremity: Tendinopathies

Kanu Goyal, MD
Assistant Professor
Division of Hand and Upper Extremity Surgery
Department of Orthopaedic Surgery
The Ohio State University Wexner Medical Center

Agenda

- **Stenosing Tenosynovitis**
- **De Quervain's Tenosynovitis**
- **Intersection Syndrome**
- **EDC tendonitis**
- **Snapping ECU**
- **Lateral Epicondylitis**
- **Medial Epicondylitis**

Stenosing Tenosynovitis

- **"Trigger Finger"**
- **Definition:**
 - **Catching or locking of the finger secondary to A1 pulley thickening**

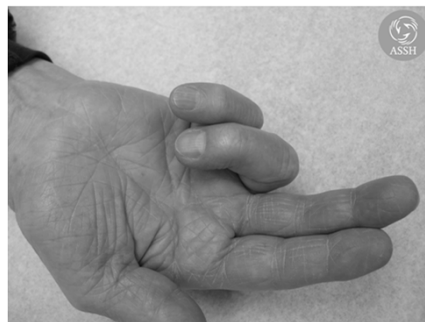

Image from American Society for Surgery of the Hand

Stenosing Tenosynovitis

- Size mismatch between flexor tendon & A1 pulley

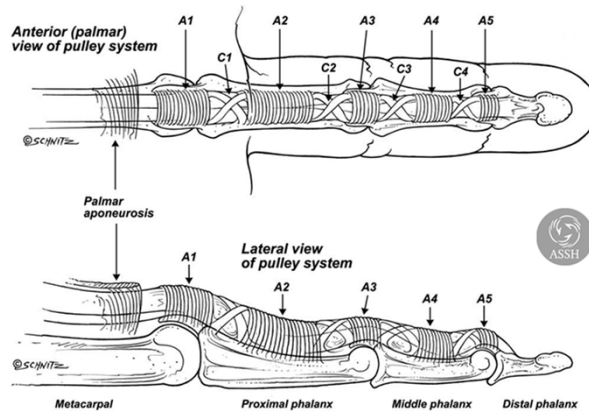


Image from American Society for Surgery of the Hand

Stenosing Tenosynovitis

- Thickened stenotic A1 pulley
- Nodular enlargement of flexor tendons
- Grades:
 - 1. pain only
 - 2. catches but can be actively unlocked
 - 3. catches but must be passively unlocked
 - 4. locked with a PIP joint flexion contracture

Stenosing Tenosynovitis

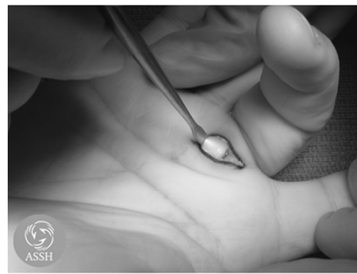
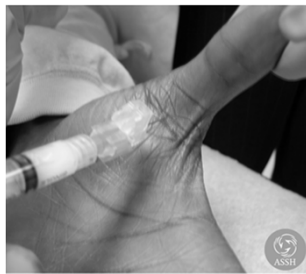- **Exam: tender volarly over A1 pulley and triggering noted**
- **Causes:**
 - **Most commonly idiopathic**
 - **Can be associated with:**
 - **Diabetes**
 - **Hypothyroidism**
 - **Rheumatoid arthritis**
 - **Recent hand surgery**
 - **Trauma**
 - **Female predilection**

Stenosing Tenosynovitis

- **DDx:**
 - **Snapping of MCPJ collaterals on osteophyte**
 - **Sagittal band rupture / snapping extensor tendon**
 - **Swan neck deformity**
 - **Slip of FDS catching under the pulley**

Stenosing Tenosynovitis

- Treatment options
 - Activity modification
 - Trigger finger splint at night
 - Steroid injections
 - Surgical Release of A1 pulley



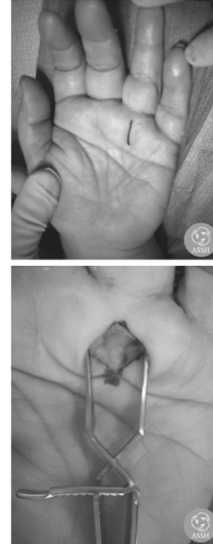Images from American Society for Surgery of the Hand

Stenosing Tenosynovitis

- Steroid injections
 - 50-70% effective
 - Reportedly equally effective in diabetics
 - Does not need to be within flexor sheath
 - Can alter blood glucose for up to a week
 - May offer a 2nd injection before surgery

Stenosing Tenosynovitis

- **Surgical release**
 - Longitudinal vs oblique vs transverse incision
 - Protect NV bundle
 - Thumb radial digital nerve
 - Completely release A1 pulley
 - Actively flex digit if wide awake
 - Release palmar pulley, vent A2 if necessary.
 - Release ulnar FDS slip if needed



Images from American Society for Surgery of the Hand

De Quervain's Tenosynovitis

- **Extensor compartments**
 - 1st: **APL & EPB**
 - 2nd: **ECRL & ECRB**
 - 3rd: **EPL**
 - 4th: **EIP & EDC**
 - 5th: **EDM**
 - 6th: **ECU**

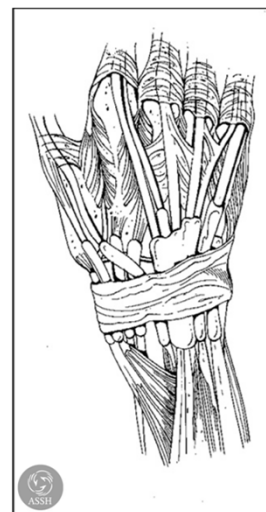


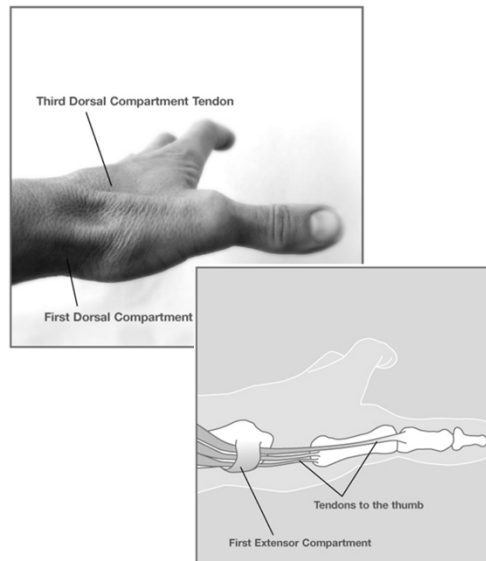
Image from American Society for Surgery of the Hand

De Quervain's Tenosynovitis

- **Definition:**
 - **Stenosing tenosynovitis of the first dorsal extensor compartment (APL & EPB)**
- **Extensor sheath becomes relatively stenotic or narrowed leading to pain**

De Quervain's Tenosynovitis

- **EPB**
 - **Distal muscle belly**
 - **Absent is 5-7% pts**
- **APL**
 - **Often Multiple slips**



Images from American Society for Surgery of the Hand

De Quervain's Tenosynovitis

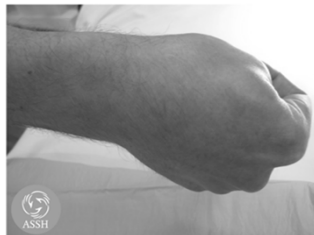- **Demographics:**
 - Overuse of thumb
 - New mothers/parents
 - Elderly
 - 6:1 women



www.publicdomainpictures.net

De Quervain's Tenosynovitis

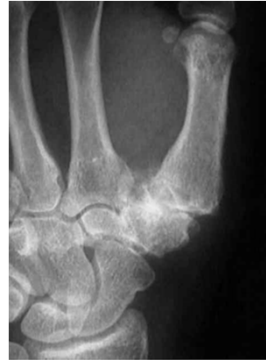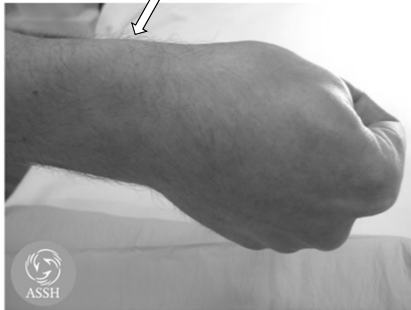- **Atraumatic radial sided wrist pain**
- **Diagnosis**
 - Pain at or just proximal to the radial styloid
 - Worsens with ulnar deviation of the wrist
 - Finkelstein test



Images from American Society for Surgery of the Hand

De Quervain's Tenosynovitis

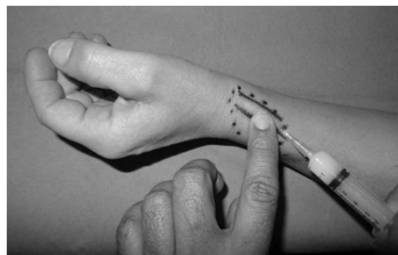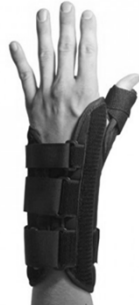- **Differential diagnosis**
 - Intersection syndrome
 - Thumb CMC joint arthritis
 - Wrist STT arthritis
 - Radioscaphoid arthritis
 - Wartenberg Syndrome



Images from American Society for Surgery of the Hand

De Quervain's Tenosynovitis

- **Treatment:**
 - Activity modification, NSAIDs, thumb spica splint
 - Steroid injection
 - Brace shown to improve outcomes after injection
 - Surgical release



Images from American Society for Surgery of the Hand

De Quervain's Tenosynovitis

- **Injections:**
 - 60% success rate
 - I personally offer 2 injections at most
 - May elevate blood glucose for a week
 - Subcutaneous injection is effective

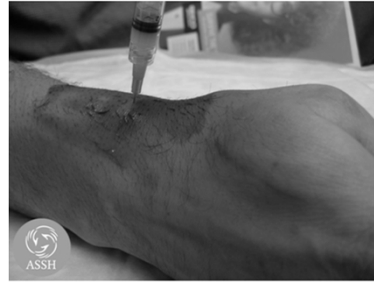

Image from American Society for Surgery of the Hand

De Quervain's Tenosynovitis

- **Surgical release of first dorsal compartment**
 - Indicated if patient dissatisfied with non-operative measures.
 - Division of the fibro-osseous sheath over the first dorsal compartment (dorsal edge)
 - Care must be taken to identify all slips of both APL and EPB tendons

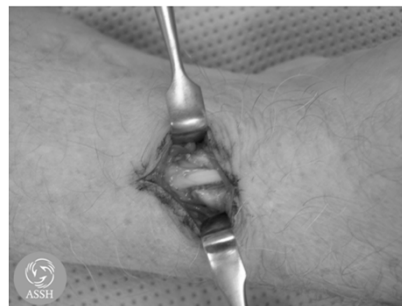

Image from American Society for Surgery of the Hand

De Quervain's Tenosynovitis

- Avoid branches of the superficial radial nerve

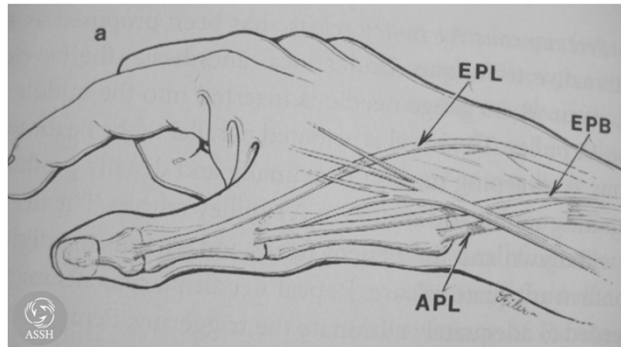


Image from American Society for Surgery of the Hand

Intersection Syndrome

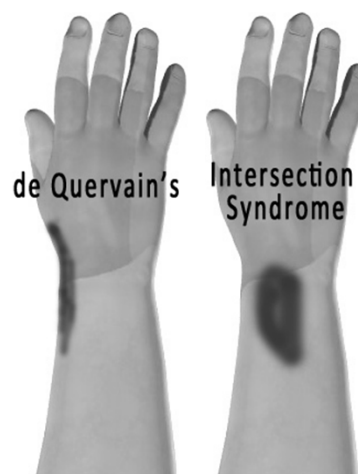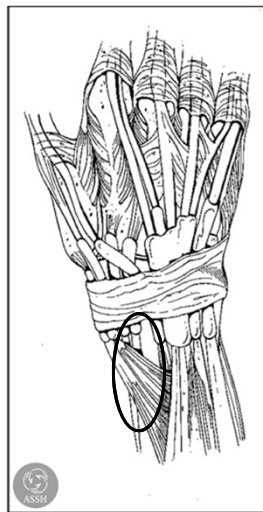
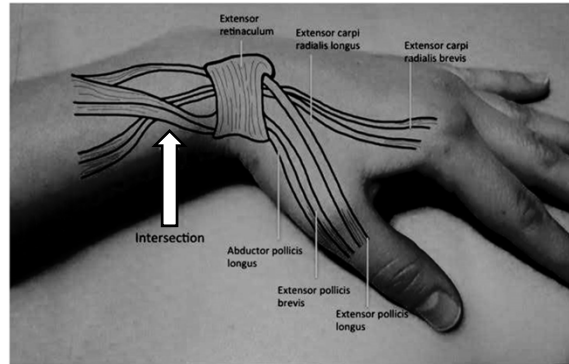


Image from American Society for Surgery of the Hand

Intersection Syndrome

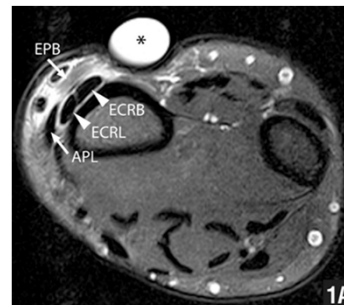
- Pain and swelling due to entrapment of and compression of 2nd compartment where the 1st dorsal compartment intersects it. Approximately 5cm proximal to wrist joint



Intersection Syndrome: The subtle squeak of an overused wrist. JABFM, July 2017

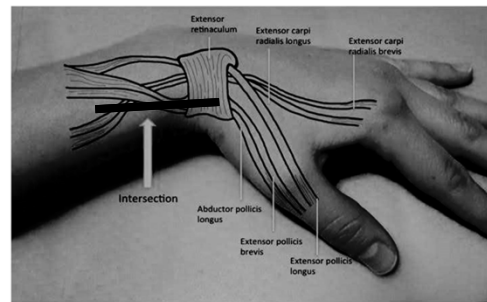
Intersection Syndrome

- History:
 - Common in rowers and weight lifters (repetitive wrist extension)
- Exam:
 - TTP over site of intersection
 - Crepitance at intersection site with resisted wrist and thumb extension
- Imaging:
 - MRI
 - Peritendinous edema
 - Fluid surrounding the 1st/2nd extensor compartments



Intersection Syndrome

- **Treatment:**
 - Immobilization
 - Steroid injection
 - Surgical release
 - Longitudinal incision to release 1st and 2nd dorsal compartment and proximal fascia
 - Retinaculum is left open



Intersection Syndrome: The subtle squeak of an overused wrist. JABFM, July 2017

EDC Tendonitis

- Rare
- Drummer's wrist
- Repetitive wrist extension
- Inject, brace, stop drumming



www.pexels.com

ECU pathology

- Ulnar sided wrist pain
- Synergy Test positive
- Stenosing tenosynovitis
 - All Treatment similar to De Quervain's
- Tendinopathy (enlarged and thickened tendon)
 - Non-operative measures similar
 - Surgically, consider debridement or excision
- ECU subluxation or ECU Snapping

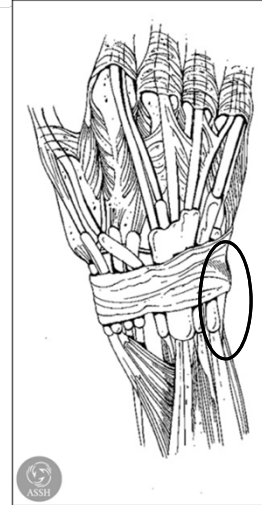
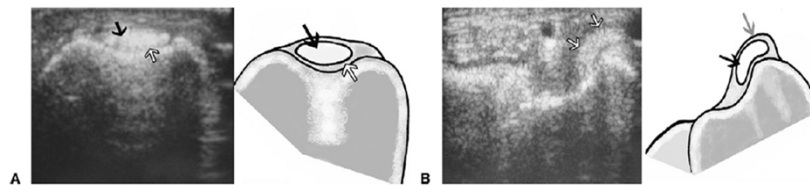


Image from American Society for Surgery of the Hand

Snapping ECU tendon

- Traumatic or overuse injuries cause attenuation or rupture of ECU subsheath

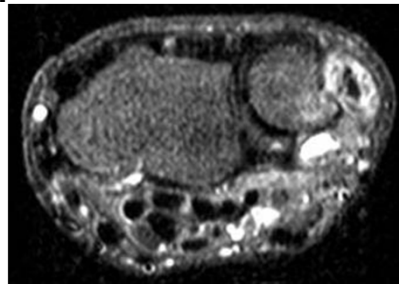


Diagnosis and Anatomic Reconstruction of Extensor
Carpi Ulnaris Subluxation [JHS 2008;33\(A\)](#)

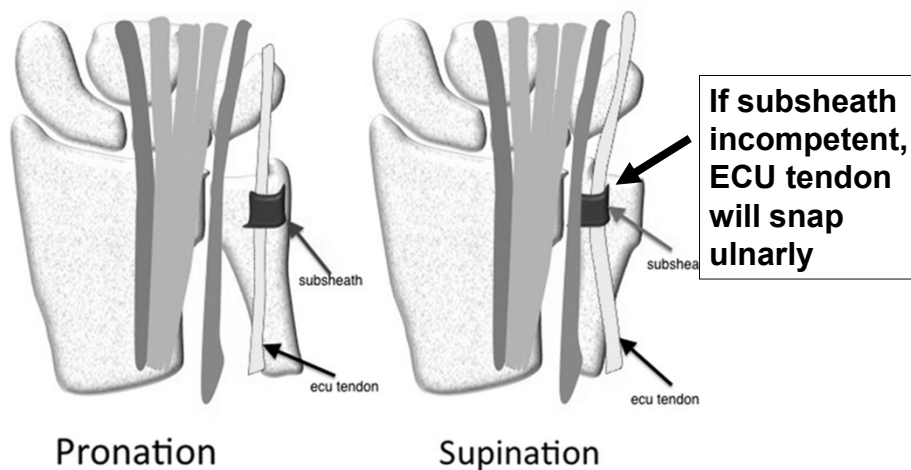
Allison J. MacLennan, MD, Nicholas M. Nemecek, BS, Thanapong Waitayawinyu, MD,
Thomas E. Trumble, MD

Snapping ECU tendon

- **History:**
 - Atraumatic/Asymptomatic
 - Injury sometimes recalled
 - Pain/snapping over dorsoulnar wrist
- **Exam:**
 - Extension/supination of the wrist elicits a painful snap
 - ECU tendon reduces with pronation
- **Imaging:**
 - MRI demonstrates peritendinous edema



Snapping ECU tendon



British Journal of Sports Medicine, Volume 47, Issue 17

Snapping ECU tendon

- **Differential Diagnosis of Ulnar Sided Wrist Pain:**
 - Other ECU pathology
 - TFCC tears
 - DRUJ synovitis/instability
 - Pisotriquetral arthritis/cysts
 - Lunotriquetral tears

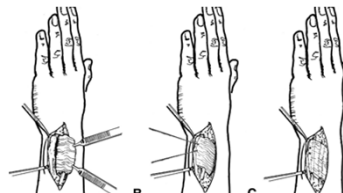
Snapping ECU tendon

- **Non-Operative Treatment:**
 - Wrist splint for tendonitis
 - Long arm cast in pronation
- **Operative:**
 - ECU subsheath repair (acute) vs reconstruction (chronic)
 - +/- wrist arthroscopy (concurrent TFCC tear in 50% of cases)
 - Change ECU vector by inserting onto ring finger MC base

Diagnosis and Anatomic Reconstruction of Extensor

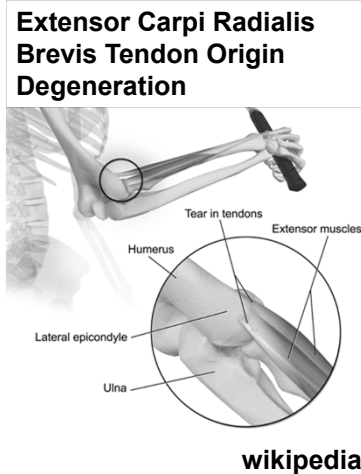
Carpi Ulnaris Subluxation JHS 2008;33(A)

Allison J. MacLennan, MD, Nicholas M. Nemecek, BS, Thanapong Waitayawinyu, MD,
Thomas E. Trumble, MD



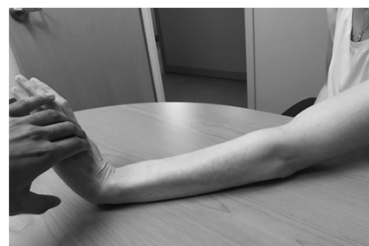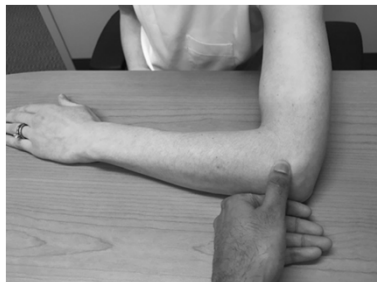Lateral Epicondylitis

- “Tennis elbow”
 - anyone and everyone
- Repetitive eccentric overload of common extensor tendon
 - Primarily tendinopathy of ECRB
 - May also involve microtears of ECRL, ECU, and EDC
- Most common cause of elbow pain



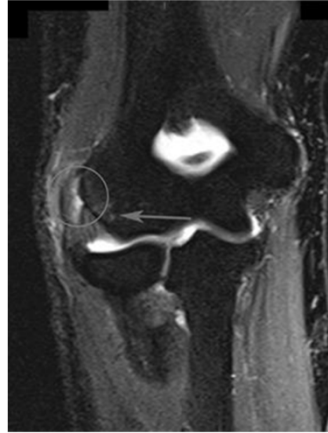
Lateral Epicondylitis

- Physical exam
 - Point tenderness at ECRB origin (just distal to lateral epicondyle)
 - Decreased grip strength
 - Provocative tests:
 - Resisted wrist extension with elbow fully extended
 - Resisted extension of the middle finger



Lateral Epicondylitis

- **Imaging**
 - Plain films usually normal
 - Calcification of extensor origin may be present but doesn't usually change management
- **MRI**
 - For uncertain diagnoses
 - Increased signal at ECRB origin (~50%); thickening
 - Evaluate LUCL



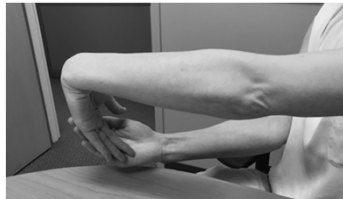Lateral Epicondylitis

- **DDx:**
 - Radial tunnel syndrome (5% concomitant Dx)
 - 3-4 cm distal/anterior to lateral epicondyle
 - LUCL injury / Posterolateral Rotatory Instability (PLRI)
 - Capitellar OCD
 - Radiocapitellar arthritis
 - Radial head fracture
 - Triceps tendinitis
 - Cervical radiculopathy

Lateral Epicondylitis

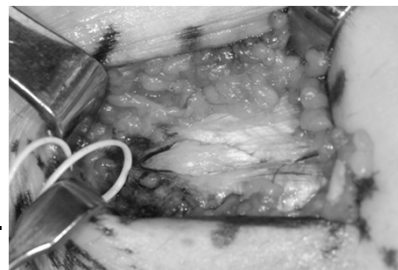
- **Non-operative treatment (95% success)**
 - Activity modification (rest), ice, NSAIDs
 - Home Stretching Program
 - Counter-force brace
 - Wrist brace
 - Steroid injections
 - Physical therapy (iontophoresis/phonophoresis)

Home exercise program



Lateral Epicondylitis

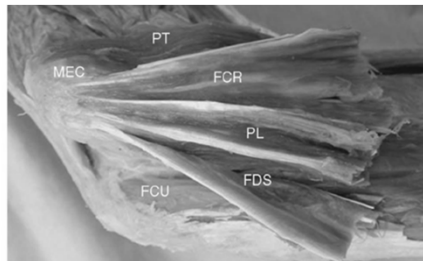
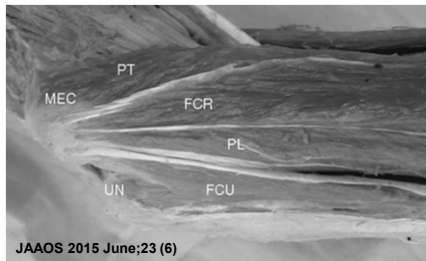
- **Operative treatment**
 - Indicated if failed non-op for 6-12mo
 - Open ECRB debridement
 - Stay anterior to LUCL origin
 - Deep/posterior to ECRL
 - Excise degenerative ECRB tendon
 - Decorticate epicondyle
 - Side-to-side tendon repair



**Arthroscopic
ECRB release
TENEX**

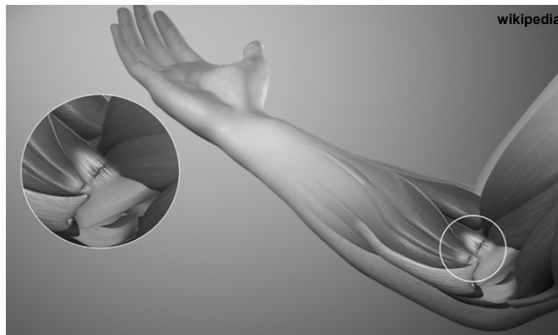
Medial Epicondylitis

- “Golfer’s elbow”
 - Pitchers, bowlers, racquet sports
- Tendinosis of flexor/pronator origin
 - Secondary stabilizers to valgus stress
 - PT, FCR, PL, FDS, FCU
 - Traditionally Pronator Teres > FCR
- Less common and harder to treat vs lateral epicondylitis



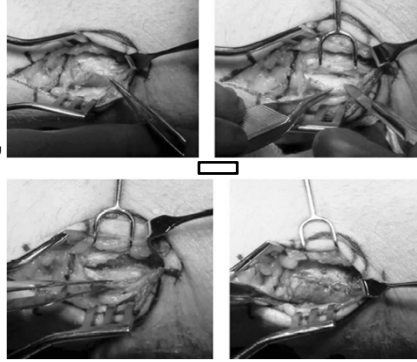
Medial Epicondylitis

- Physical Exam
 - TTP 5-10mm distal/anterior to medial epicondyle
 - Pain with resisted pronation & wrist flexion
 - Always check for valgus instability and ulnar



Medial Epicondylitis

- **Treatment**
 - Non-operative similar to Lateral Epicondylitis
 - Operative:
 - Indicated after 6mo failed non-op
 - Debridement of PT/FCR, reattachment of flexor-pronator group
 - Good to excellent outcomes in 80%
 - Not as good as surgery for lateral epicondylitis
 - Worse outcomes with pre-op ulnar nerve symptoms



JAAOS 2015;23