

# **Sarcoidosis For The Internist**

**Arindam (AJ) Singha, MD**  
**Clinical Instructor of Internal Medicine**  
**Pulmonary and Critical Care Medicine**  
**Department of Internal Medicine**  
**The Ohio State University Wexner Medical Center**

## **Disclosure**

**Dr. Singha: No conflicts of interest to disclose.**

**Dr. Crouser: Sarcoidosis related support**

- **American Thoracic Society Sarcoidosis Clinical Practice Guidelines Chair**
- **Foundation for Sarcoidosis Research Model Grant**
- **National Institutes of Health/NHLBI**
- **aTYR Pharmaceutical**

## **A clinical scenario**

**A 48 y.o. African American woman with asthma presents for follow up. She was seen in the ED two weeks ago for acute asthma exacerbation. A CXR at the time showed no infiltrate but bilateral hilar fullness. Patient's respiratory symptoms have since improved back to baseline. She reports a family history of sarcoidosis and is concerned she has the same disease.**

- **What is her risk for having sarcoidosis?**
- **How can we confirm or rule out her suspicion?**
- **If she does have sarcoidosis what can we do to help?**

## **Objectives**

- **Clinical presentation, epidemiology and histopathology of sarcoidosis**
- **Diagnostic criteria based on ATS guidelines**
- **Differential diagnoses that resemble sarcoidosis**
- **Screening/detection of extrapulmonary sarcoidosis**
- **Treatment of sarcoidosis**

## **Background**

- **Granulomatous inflammatory disease with unknown etiology**
- **Caeser Boeck coined the term, “sarcoid” in 1899**
- **Multisystem disease affecting:**
  - **Lungs (>90% of cases)**
  - **Skin**
  - **Heart**
  - **Kidney**
  - **Bone marrow**
  - **Liver**

## **Epidemiology – Ethnicity and Nationality**

- **Globally, high prevalence noted in Swedish/Dutch populations**
- **Japanese sarcoidosis is less common, but more often involves heart and eyes.**
- **In the US, incidence & prevalence is highest among African Americans, lowest in Asian and Hispanic Americans**
  - **~4 fold higher prevalence among AA compared to White**
- **Both race and geography matters**
  - **Incidence and prevalence among Afro Caribbeans living in mainland France is twice that of Afro Caribbeans living in Guadeloupe**

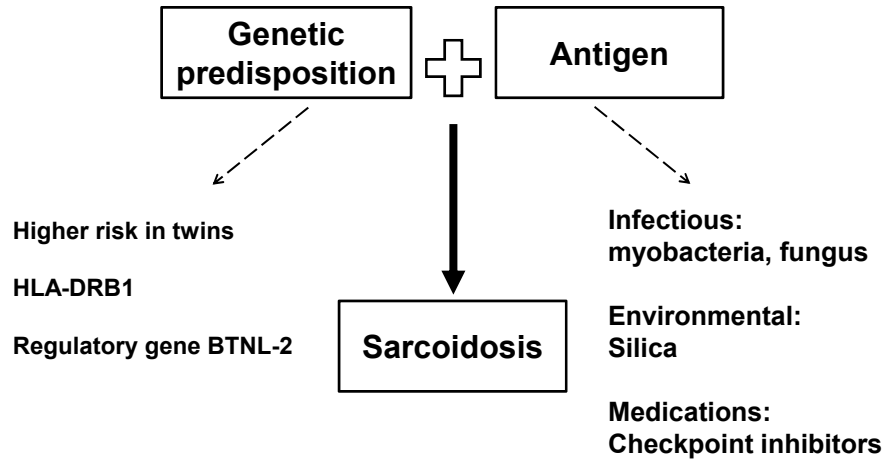
## **Epidemiology – Age and Sex**

- **Prevalence similar among men and women**
- **Overall combined age of onset: 40s to 50s**
- **Women have a later disease onset than men**
  - **Swedish cohort: men presented 10 years earlier than women**
- **Peak age at incidence has increased in recent years**

## **Epidemiology continued**

- **Patients with sarcoidosis have higher mortality than those without**
  - **Mortality rate among African American women in NE USA with sarcoidosis 2-4 times higher than matching cohorts without sarcoidosis**
- **Rate of hospitalization higher among patients with sarcoidosis than patients without sarcoidosis (particularly women)**
- **Obesity associated with higher risk, smoking confers lower risk**

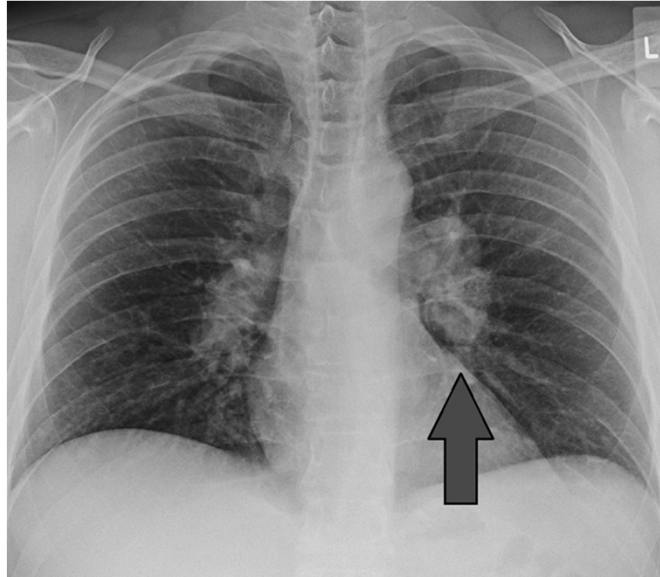
## Pathogenesis



## Clinical presentation

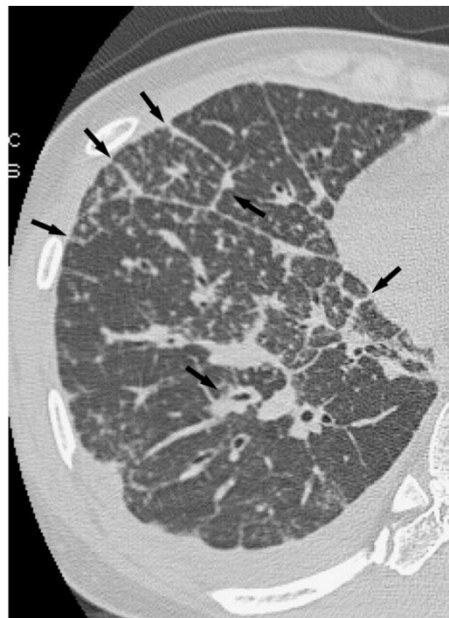
- Up to 50% are asymptomatic with incidental hilar adenopathy seen on CXR
- Symptoms will depend on the organs involved
- Common respiratory symptoms:
  - Cough, dyspnea, chest pain
- On pulmonary physical exam,
  - Wheezing may be present; crackles and clubbing are rare
  - The lung exam is often normal despite radiographic abnormalities

## Chest Imaging:



## Chest Imaging:

Perilymphovascular  
nodules



## **A clinical scenario**

**A 42 y.o. businessman travelling from Japan has an episode of syncope. He did not have any prodromal symptoms. No seizure like activity was noted. He did not lose control of his bowel or bladder. He is alert, and oriented following the episode. He denies any chest pain, dyspnea, lightheaded or dizziness. In the ED, an EKG shows third degree AV block. In addition to an evaluation by an Cardiologist, what else should be done?**

## **A clinical scenario**

**A 42 y.o. businessman travelling from Japan has an episode of syncope. He did not have any prodromal symptoms. No seizure like activity was noted. He did not lose control of his bowel or bladder. He is alert, and oriented following the episode. He denies any chest pain, dyspnea, lightheaded or dizziness. In the ED, an EKG shows third degree AV block. In addition to an evaluation by a Cardiologist, what else should be done?**

**Answer: Workup for sarcoidosis**

## **Extrapulmonary manifestation**

### **Cardiac:**

- **New onset high degree AV block**
- **Non ischemic cardiomyopathy without known etiology**
- **Spontaneous VT without inciting etiology**

### **Cutaneous:**

- **Maculopapular, erythematous, or violaceous skin lesions**
- **Subcutaneous nodules**

## **Extrapulmonary manifestation**

### **HEENT:**

- **Bilateral parotid gland swelling**
- **Violaceous rash on nose and cheek**
- **Uveitis, optic neuritis**
- **Granulomatous lesions noted on laryngoscopy**

### **Renal:**

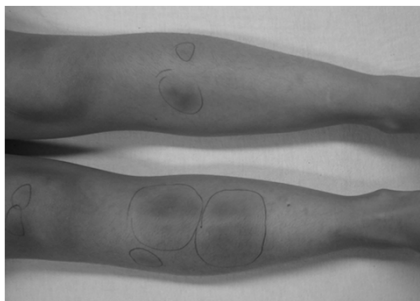
- **Hypercalcemia with abnormal vitamin D metabolism**
- **Hypercalciuria, and nephrolithiasis with Ca stones**

## Extrapulmonary manifestation

- Elevated alkaline phosphatase level specially in the absence of gallstones
- Two or more enlarged extra thoracic lymph nodes (CT,MRI, and PET)
- Increased inflammatory activity in heart (MRI, PET, and gallium)
- Imaging showing enlargement or nodules in liver or spleen (CT, PET, and MRI)
- Inflammatory lesions in bone

## Lofgren Syndrome

- Acute form of sarcoidosis
- Presence of erythema nodosum, migratory polyarthralgia, bilateral hilar lymphadenopathy and fever highly specific for sarcoidosis
- Prognosis is excellent



Erythema Nodosum

Image: wikipedia.org

# Lupus Pernio

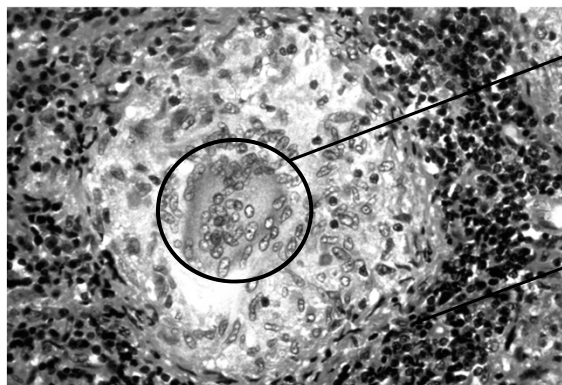
- Violaceous skin plaques with predilection for nose, cheeks, ear and fingers
- Concurrent intrathoracic involvement common
- Biopsy of the affected skin would show granuloma

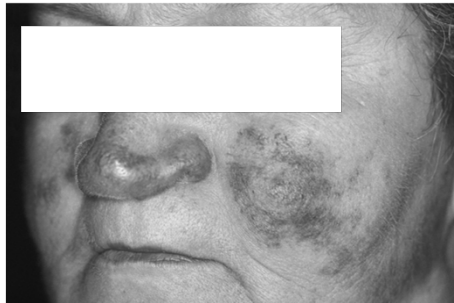

Image: wikipedia.org

## Histopathology

- Non caseating granuloma
  - Inner core of macrophages and multinucleated giant cell
  - Outer rim of T-lymphocytes
  - Mostly but not always is non-necrotic



Multinucleated  
giant cell

Lymphocytes

Image: commons.wikimedia.org

## **Diagnostic Criteria**

**Three major criteria:**

- 1. A compatible clinical presentation**
- 2. Nonnecrotizing granuloma on biopsy**
- 3. Exclusion of alternative causes of granulomatous disease**

## **Etiology of granulomas - Infectious**

**Mycobacteria:**

- **M. Tuberculosis and non TB mycobacteria**
  - **Culture is gold standard**
  - **Quantiferon testing preferred for screening over TB skin test (pt w/ sarcoid may have anergy)**

**Tropheryma Whipplei:**

- **Diarrhea, weight loss**
- **Periodic acid–Schiff stain**

## **Etiology of granulomas - Infectious**

### **Zoonotic etiology:**

- **Francisella tularensis:** rabbit exposure
- **Bartonella henselae:** cat exposure
- **Coxiella burnetii & Brucella:** livestock exposure

### **Fungi:**

- **Aspergillus, Histoplasma, Blastomyces, Coccidioides, Cryptococcus, Pneumocystis**

### **Parasites:**

- **Toxoplasma gondii, Schistosomiasis, Leishmaniasis**

## **Etiology of granulomas – Non Infectious**

### **Malignancy:**

- **Lymphoma**
- **Sarcoid like reaction to solid tumor**
- **Germ cell tumor**

### **Drug induced:**

- **Checkpoint inhibitors**
- **Interferon therapy**
- **Biologic therapies**
- **pneumotox.com is a great resource**

## **Etiology of granulomas – Non Infectious**

### **Autoimmune diseases:**

- **ANCA-associated vasculitis**
- **Langerhans cell histiocytosis – usually young female, smoker, with cystic lung disease**
- **Rheumatoid nodules – tend to be necrotizing granulomas**

## **Etiology of granulomas – Non Infectious**

### **Exposures:**

- **Hypersensitivity pneumonitis:**
  - **Exposure to organic particles**
- **Hot tub lung syndrome**
  - **MAC w/ hypersensitivity features**
  - **Aerosolized water exposure (hot tubs)**
- **Pneumoconiosis:**
  - **Beryllium, titanium, aluminum, zirconium, cobalt**
- **Foreign body aspiration**

# **Sarcoidosis**

**Elliott D. Crouser, MD**  
Professor of Medicine  
Chair, Department of Medicine  
The Ohio State University Wexner  
Medical Center East Hospital  
Division of Pulmonary, Critical Care  
and Sleep Medicine  
The Ohio State University Wexner Medical Center

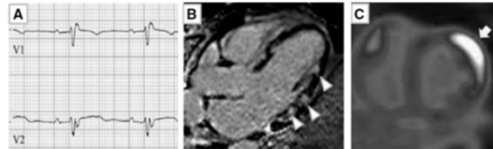
## **Detection of Extra-thoracic Disease**

- **Extra-thoracic involvement occurs in >50% of cases**
- **<3% present exclusively with extra-thoracic disease**
- **Asymptomatic extra-thoracic involvement is common, and requires additional screening tests.**

## Ocular Sarcoidosis:

- ~10% prevalence in USA; closer to 50% in Europe and Japan
- Usually is symptomatic
  - Red, painful, blurry vision
- Uveitis is most common
- Conjunctivitis
- Lacrimal gland involvement
- Posterior uveitis
- Routine baseline ophthalmology screening is recommended
- Eye exam if symptoms develop
- Treatment is always indicated

## Cardiac sarcoidosis

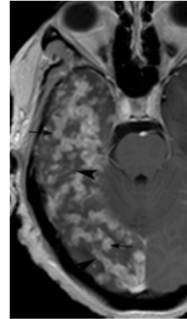
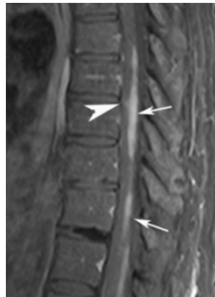

- ~25% prevalence on autopsy
- Second leading cause of death behind pulmonary sarcoidosis
- Only 5% based on symptoms
  - Palpitations, chest pain, dizziness, syncope (sudden death).
- Heart block (complete or bundle branch)
  - ~1/3 of all cases of adult onset complete heart block
- Ventricular arrhythmias
- Heart failure
- Atrial arrhythmias (uncommon)
- ECG is recommended for screening asymptomatic sarcoidosis
- MRI is best for detection if cardiac involvement is suspected
- Treatment or at least close follow up are necessary

Crouser ED, Maier LA, Wilson KC, et al. Diagnosis and Detection of Sarcoidosis. An Official American Thoracic Society Clinical Practice Guideline. Am J Respir Crit Care Med. 2020;201(8):e26-e51. doi:10.1164/rccm.202002-0251ST

## Neurosarcoidosis

- ~5-15% of cases
- Causes ~10% of deaths
- Can involve any part of the brain or spine
  - Most commonly the cranial nerves
  - Leptomeningeal
  - Spinal cord



## Skin

- 15-20%
- Topical treatments may work for most cases
- Lupus pernio usually requires systemic treatment

## **Hepatic sarcoidosis**

- **>50% have granulomas on liver biopsy**
- **~35% have abnormal liver function tests**
  - **Alkaline phosphatase is abnormal in >90%**
- **Treatment is generally not indicated**
- **~6% progress to cirrhosis and 3% develop portal hypertension**
  - **Corticosteroids are useful for symptomatic RUQ pain, nausea, wgt loss, jaundice**
  - **Pruritis responds to ursodeoxycholic acid**
  - **Liver transplantation is often successful if other organ involvement is minimal**

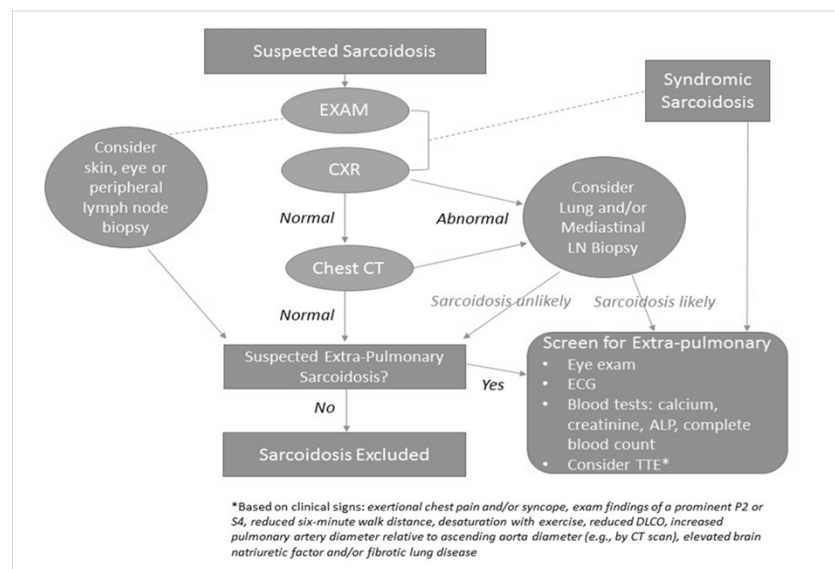
## **Abnormal Calcium Metabolism**

- **Is common but not well documented in the literature**
- **Overactive 1- $\alpha$  hydroxylase (macrophages) converts 1-OH Vitamin D to 1,25 OH Vitamin D**
  - **1,25 OH Vit D promotes hypercalcemia and hypercalciuria**
- **Common complications:**
  - **Kidney stones**
  - **Acute kidney injury or failure**
  - **Altered mentation**
  - **Dehydration**
- **Treatment is required if complications or if serum calcium exceeds 11 mg/dL**

## Other common manifestations

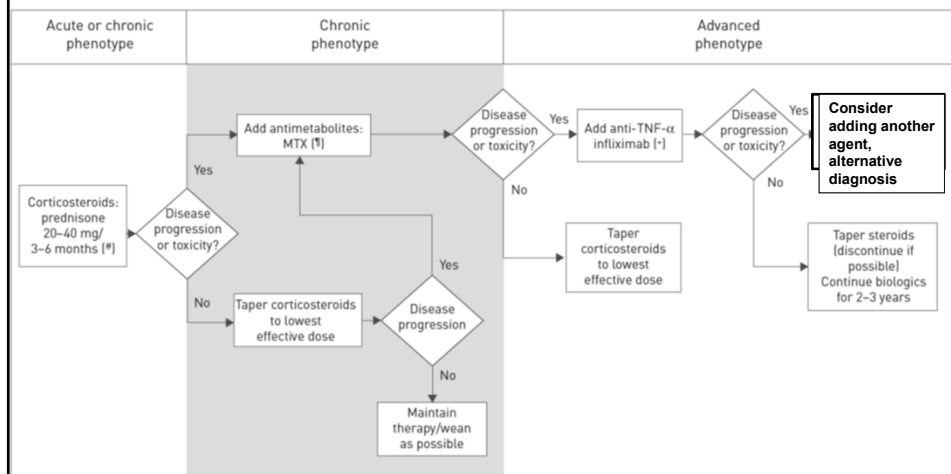
- Arthritis 15-35%
- Upper airways
  - Stridor
  - Recurrent sinus infections
- Spleen
  - Asymptomatic
  - LUQ pain
  - Hypersplenism
- Anemia
- Leukopenia (lymphopenia)
- Monocytosis
- Pulmonary hypertension (unexplained dyspnea, prominent second heart sound): should be treated as it portends increased mortality
- Primary renal involvement (rare)

## Summary of Diagnosis and Detection



Rahaghi FF, Baughman RP, Saketkoo LA, et al. Delphi consensus recommendations for a treatment algorithm in pulmonary sarcoidosis. Eur Respir Rev 2020; 29: 190146 [<https://doi.org/10.1183/16000617.0146-2019>]. - (CC BY-NC 4.0)

## Recommended Treatment Approach (minimize steroid exposure)



¶ MTX = methotrexate. Alternatives treatments include azathioprine, mycophenolate, leflunomide  
 •Infliximab alternatives: adalimumab, rituximab

Rahaghi FF, Baughman RP, Saketkoo LA, et al. Delphi consensus recommendations for a treatment algorithm in pulmonary sarcoidosis. Eur Respir Rev 2020; 29: 190146 [https://doi.org/ 10.1183/16000617.0146-2019]. - (CC BY-NC 4.0)