



# Non-Arthroplasty Options for Osteoarthritis of the Knee

**Robert A. Duerr, MD**

*Assistant Professor*

*Orthopedic Surgery and Sports Medicine*

*The Ohio State University Wexner Medical Center*

**MedNet21**  
Center for Continuing Medical Education

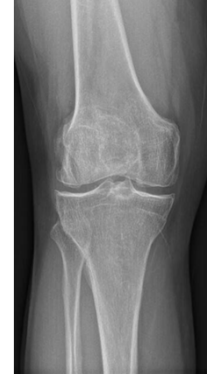 **THE OHIO STATE UNIVERSITY**  
WEXNER MEDICAL CENTER

## Disclosures

- Educational Support – Arthrex
- None related to this talk

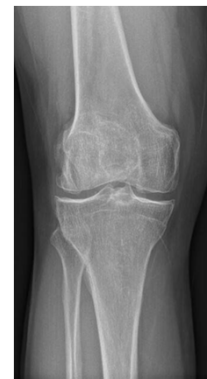## Defining the Problem

- Osteoarthritis (OA)
  - Clinical syndrome of joint pain, swelling and stiffness
  - Characterized by gradual loss of articular cartilage, osteophyte formation, subchondral bone remodeling, and joint inflammation



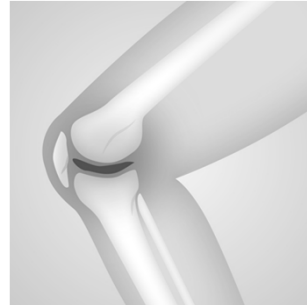## Defining the Problem

- Osteoarthritis (OA)
  - ♦ Most common form of joint disease
  - ♦ 7.7 million ambulatory visits yearly
  - ♦ \$3.4 to \$13.2 Billion annual job-related costs
  - ♦ Among leading cause of disability worldwide
    - 10% of people over 55 yo with symptomatic knee OA
  - Correlation between severity of walking disability and risk of death (CV disease)



## Why do people get OA?

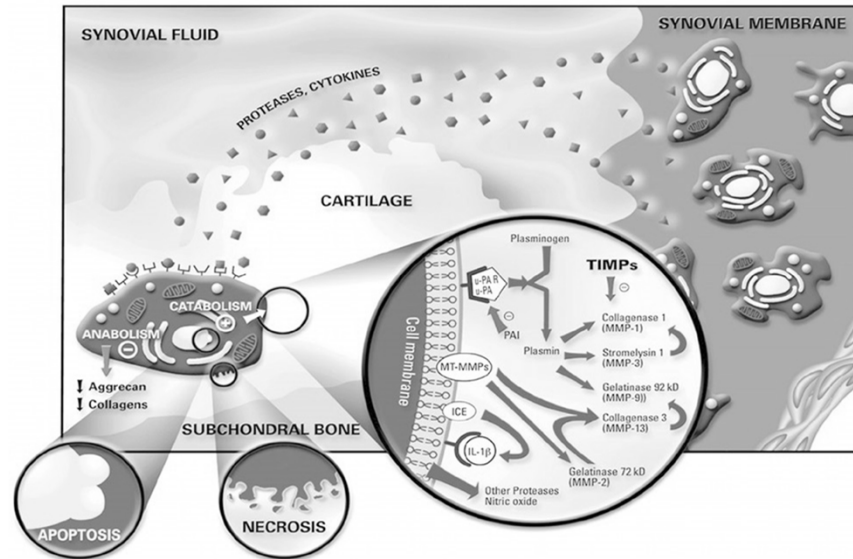
- Trauma
- Gender (F > M)
- Race
- Age
- Occupation
- Obesity (3x increase in US since 1995)
  - Metabolic syndrome (Central obesity, dyslipidemia, HTN, elevated fasting glucose)
  - Altered metabolic profile = increased joint inflammation
- Genetic markers – Linked to Vit D receptor, estrogen receptor 1, IL-1, IL-4, BMP-2, BMP-5, matrilin-3



## Other Factors

- Instability (Chronic ligament injury)
  - ♦ Shear stress on cartilage
- Muscle weakness
  - ♦ Stress and overload
- Malalignment
  - ♦ Overload
- All lead to abnormal stresses on the cartilage

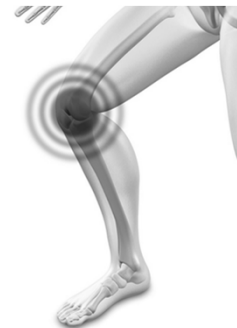# Pathophysiology



Pelletier, J., Martel-Pelletier, J. The Novartis-ILAR Rheumatology Prize 2001 Osteoarthritis: from molecule to man. *Arthritis Res Ther* 4, 13 (2001). <https://doi.org/10.1186/ar378>

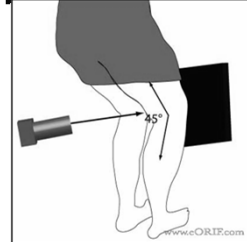
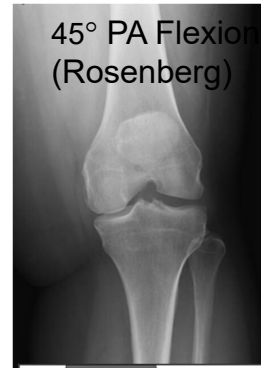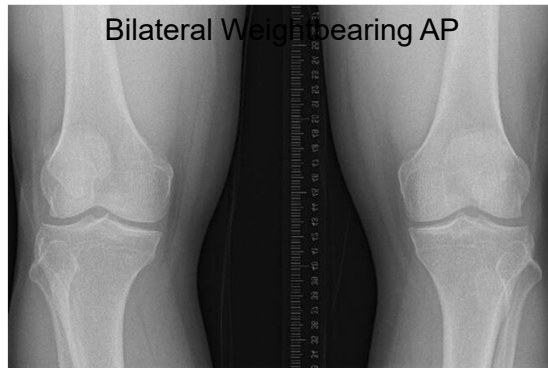
## Patient presentation

- Pain\*
- Swelling
- Morning stiffness <30 min
- Worse with activities
- Mechanical symptoms
  - ♦ Catching, locking

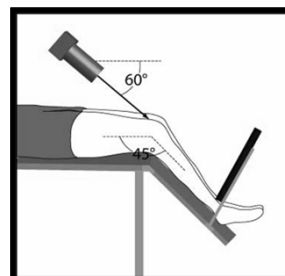
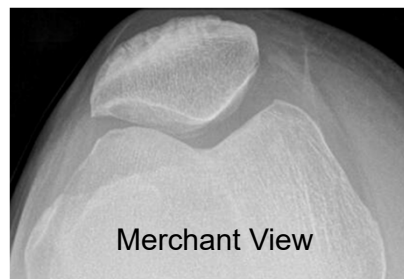
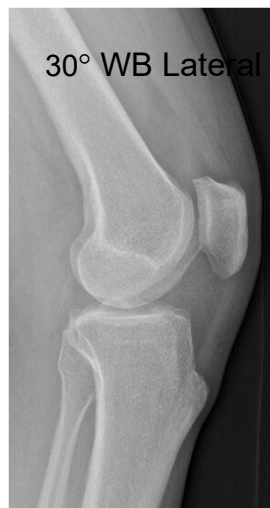


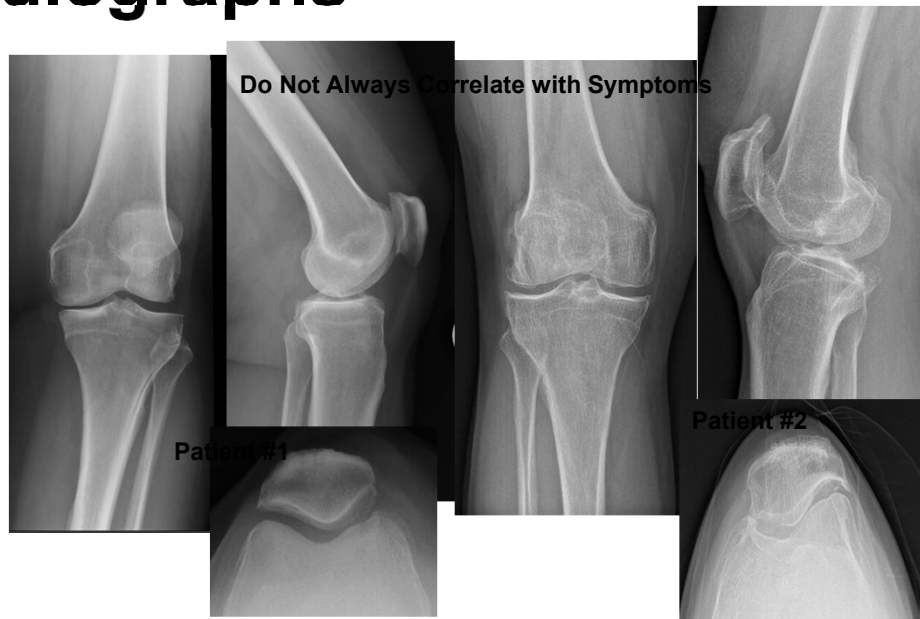## Standard X-ray Series



## Standard X-ray Series

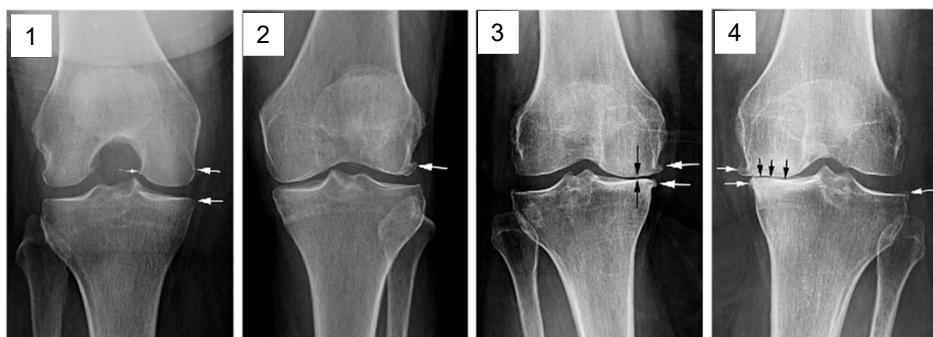


# Radiographs



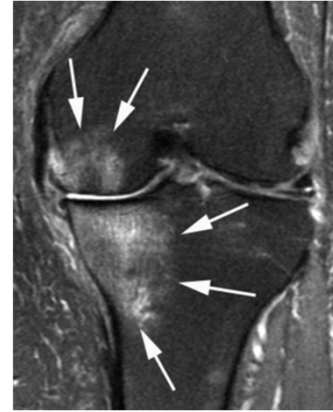
# Radiographic Grading

- Kellgren-Lawrence Scale

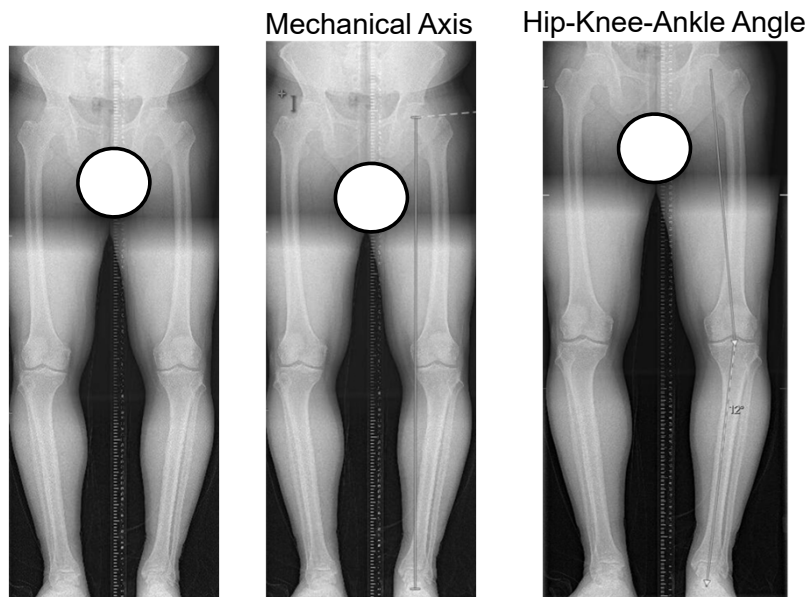


## Magnetic Resonance Imaging (MRI)

- Not necessary
- Useful to rule out other pathology after failed conservative treatment
  - ♦ Meniscus
  - ♦ Ligament
  - ♦ Insufficiency fractures
- Surgical planning
  - ♦ Partial knee replacement
  - ♦ Osteotomy



## Full Length Alignment Radiographs



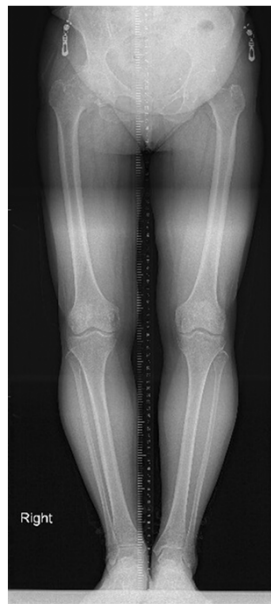# What is “Normal”?

## *Hip-Knee-Ankle Angle*

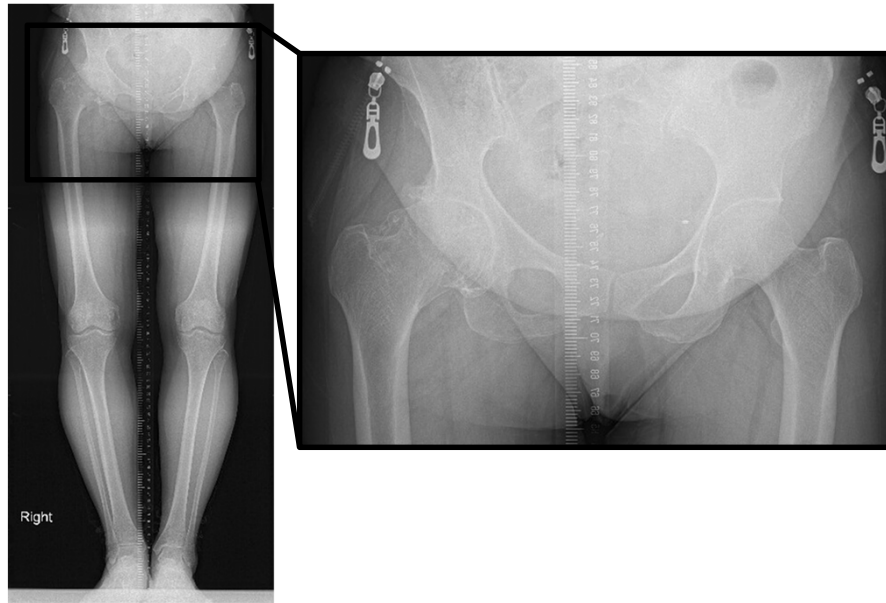


- Bellemans, et al. Is Neutral Mechanical Alignment Normal for All patients? The Concept of Constitutional Varus. CORR 2012
- 500 knees in 250 healthy volunteers measured on full length weight bearing X-ray
  - Only 2% with neutral MA
  - **76% within 3°**
  - Males: 32% > 3° varus
  - Females: 17% > 3° varus
  - 2.4% >3° valgus

## Full Length Alignment Radiographs



## Full Length Alignment Radiographs



## First Line Treatment Algorithm

- Self management – “Get moving”
- Physical therapy
- Weight loss
- Anti-inflammatory medications
  - ♦ Oral NSAIDs, COX-2 Inhibitors
  - ♦ Intra-articular steroids
- Unloader bracing

## **Self Management – “Home Exercise Program”**

- Exercise\*
  - ♦ Walking, stationary bike, water aerobics, elliptical
  - ♦ Underutilization due to fear of disease progression
  - ♦ Recommend 180 min/week

## **Physical Therapy**

- Supervised exercise program
- Goals:
  - ♦ Preserve ROM
  - ♦ Correct gait impairment
  - ♦ Strengthening - Hip abductors, Quad, Hamstrings
- Severe OA
  - ♦ Aquatic PT
  - ♦ Land PT may worsen symptoms
- “Post-PT syndrome” → 6 weeks PT followed by...

## Weight Loss

- **BMI 25 – 30**
  - ♦ Discussion of proper diet
- **BMI 30 - 35**
  - ♦ Consider nutritionist referral
- **BMI 35– 40**
  - ♦ Consider comprehensive weight management program
- **BMI >40**
  - ♦ Comprehensive weight management program referral prior to any surgery

## Oral Medications

- Based on severity of symptoms
- Mild – Moderate
  - ♦ NSAIDs (Ibuprofen, Naprosyn)
  - ♦ Diclofenac
  - ♦ Meloxicam
  - ♦ COX-2 Inhibitors (Celebrex)
- Severe
  - ♦ Rarely Tramadol
  - ♦ Do NOT provide narcotic pain medications for OA pain

## Topicals

- NSAIDs
  - ♦ Voltaren gel
- Compounded Creams
  - ♦ Mixture of medications
  - ♦ Can be \$\$\$
- Capsaicin

## Unloader Brace

- Patients with **isolated** medial or lateral compartment OA
- Apply an external valgus (or varus) force, reducing the load in the medial/lateral compartment
- Improved joint proprioception can also help reduce pain

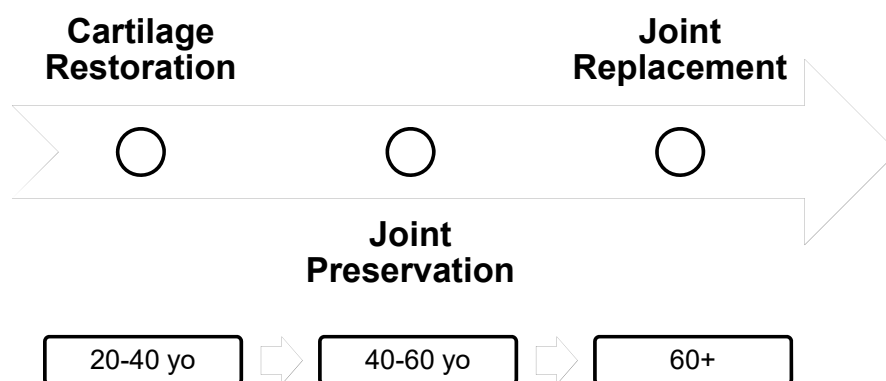




## Intra-articular Injection Options

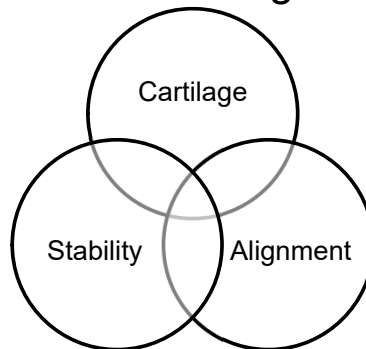
- Corticosteroids
- Hyaluronic Acid
- Orthobiologics:
  - ♦ Platelet Rich Plasma (PRP)
  - ♦ Adipose derived stromal cells
  - ♦ Bone marrow derived mesenchymal stem cells
  - ♦ Amniotic-derived therapies

## Surgical Options in Knee OA



# Cartilage Restoration in Knee OA

- Focal chondral defects ( $>2 \text{ cm}^2$ )
  - ♦ Autologous chondrocyte implantation (MACI)
  - ♦ Osteochondral allograft transplant
- Correction of other contributing factors



## Autologous Chondrocyte Implantation



- ACI or MACI (Membrane)
  - ♦ Autologous cultured chondrocytes on porcine collagen membrane
- Goal: Form autologous “Hyaline-like” cartilage

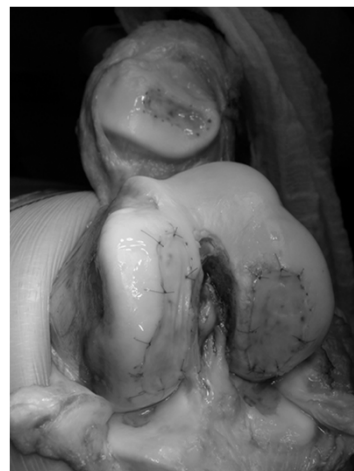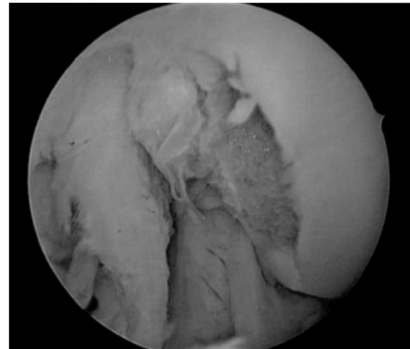
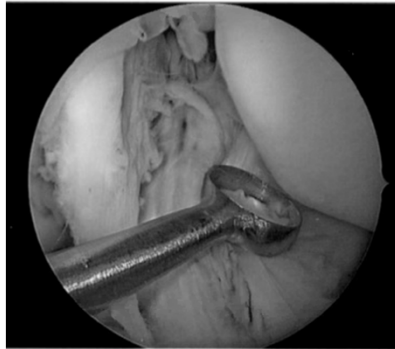


Photo courtesy Dr. Tom Minas

## Autologous Chondrocyte Implantation



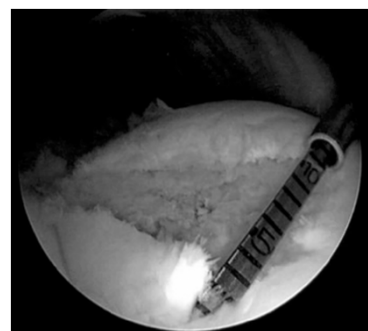- Requires staged arthroscopic harvest from non-weight bearing area



## Autologous Chondrocyte Implantation

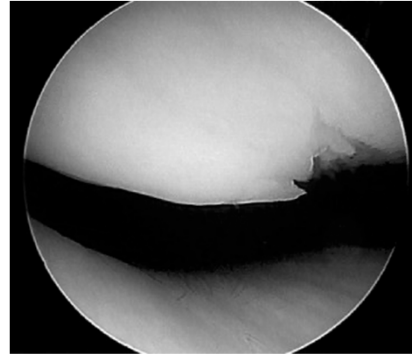


- Pros: Regeneration of autologous tissue
  - ♦ Can address larger and various sized defects
  - ♦ Multiple defects
- Cons: High costs
  - ♦ 2-stage procedure
  - ♦ Prolonged protection needed to allow maturation of chondrocytes

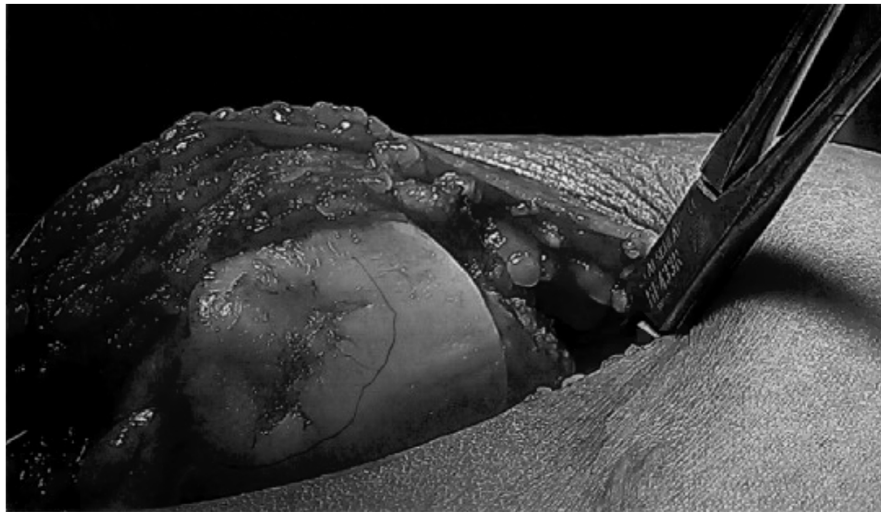


## Case Example


- 26 yo F persistent anterior knee pain
- Underwent previous arthroscopy → Partial thickness cartilage injury to patella
- 2 years of persistent pain
- Failed PT, NSAIDs, Nerve ablation, pain management



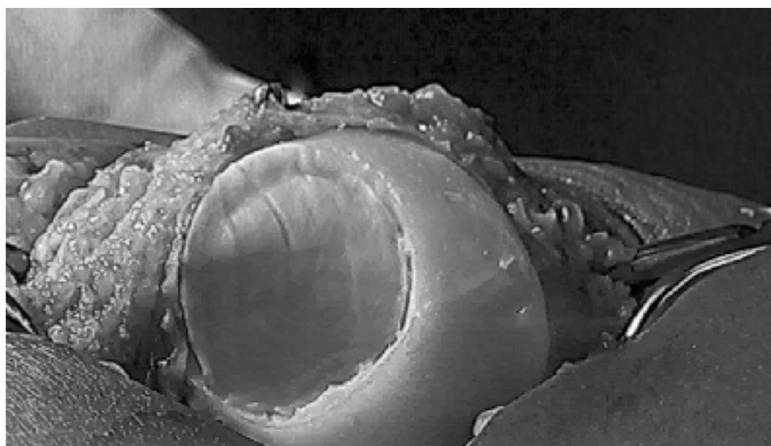
## Patella cartilage defect



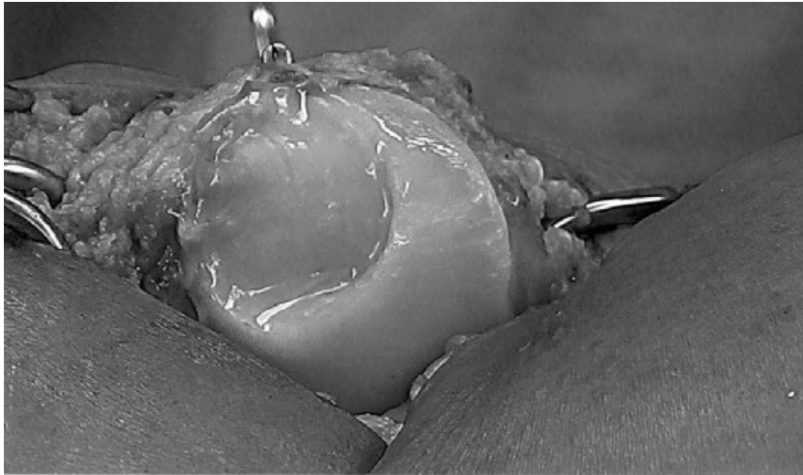
## **Cartilage defect after removal of damaged cartilage**



## **After implantation of MACI**

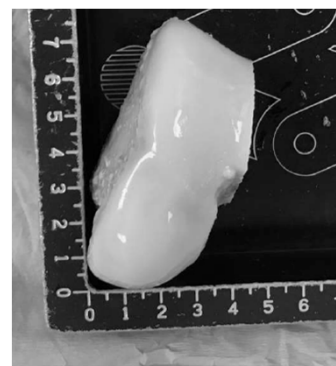


## MACI sealed with fibrin glue



## Osteochondral Allograft


- Goal: Replace defect with live chondrocytes in mature matrix with underlying bone
- Fresh, refrigerated grafts
  - ♦ Retain chondrocyte viability



Allograft View 1

## Osteochondral Allograft

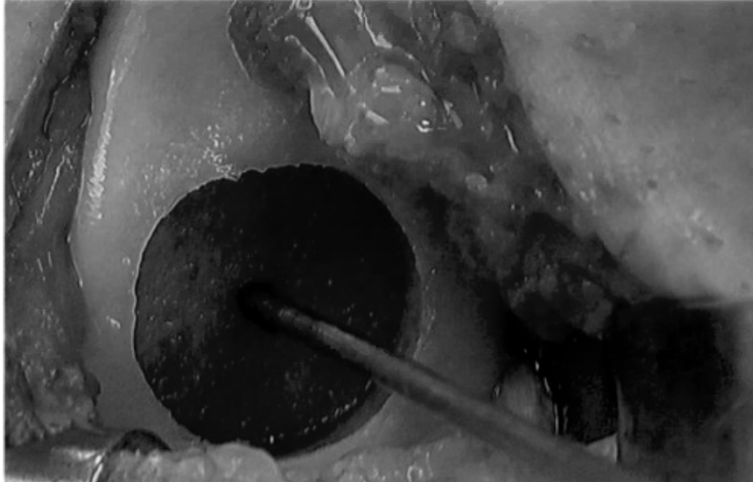
- Performed as shell (dowel) or bulk grafts
- Match size and radius of curvature of the condyle
- Pros: Address large defects, correct bone loss, use in revision or failed ACI
- Cons: Limited availability, high costs, potential risk of infection
- “Catastrophic” failure



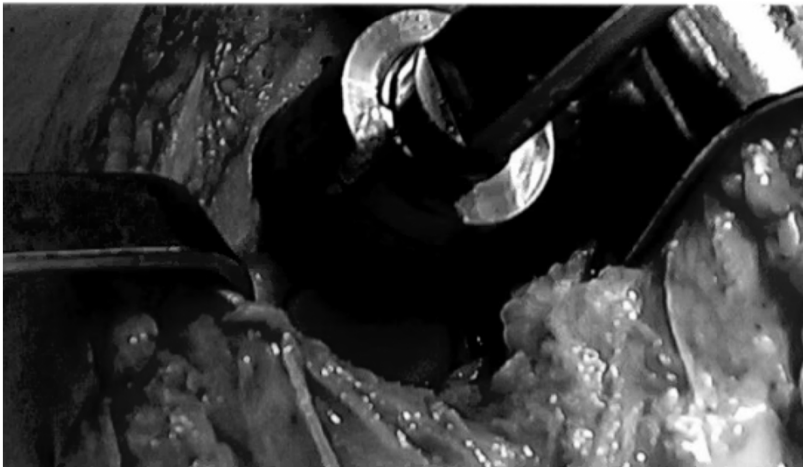
## Osteochondral Allograft



## Osteochondral Allograft



## Osteochondral Allograft



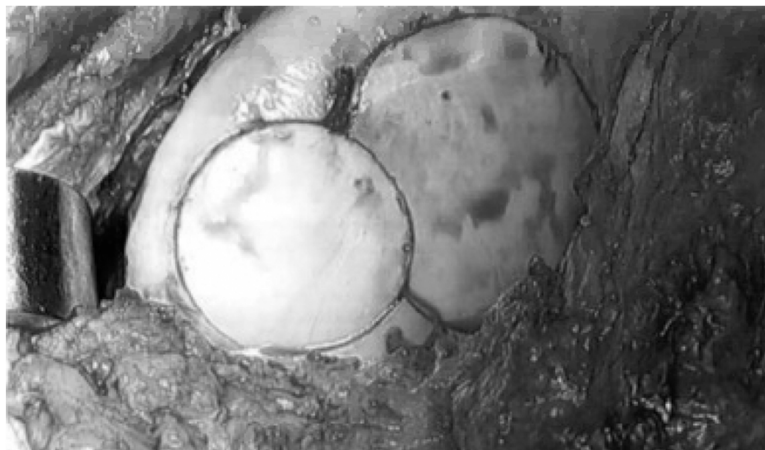


## Osteochondral Allograft

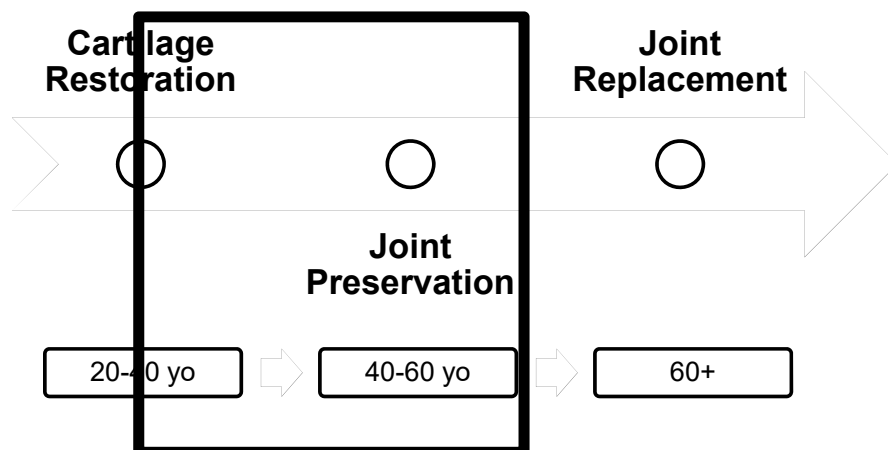


## “Snowman” Technique

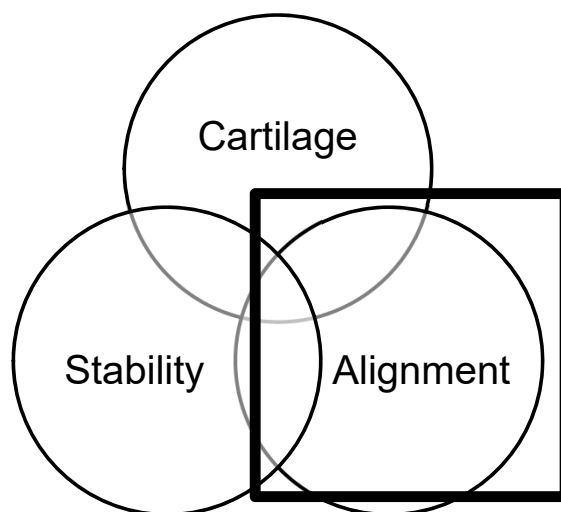
- Larger Defects



## Surgical Options in Knee OA

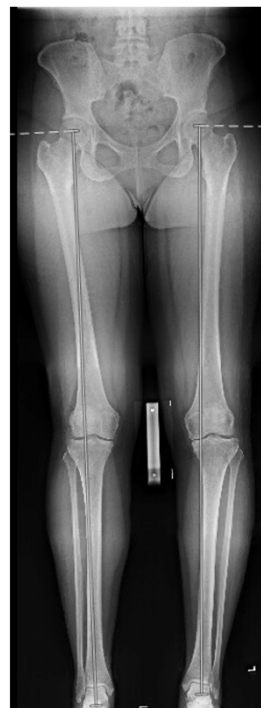

## Principles of Knee Joint Preservation



## Lower Limb Malalignment

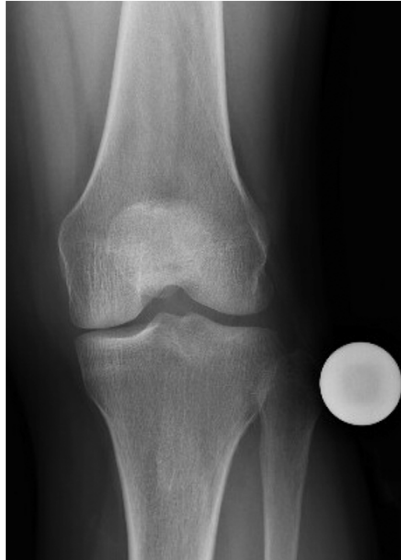- Angular deformity in the lower limb
  - ♦ Abnormal distribution of weight bearing stresses
  - ♦ Accelerate wear in medial or lateral compartments
- Corrective osteotomy used to re-distribute forces evenly
  - ♦ Often combined with cartilage restoration to improve mechanical environment for biologic healing



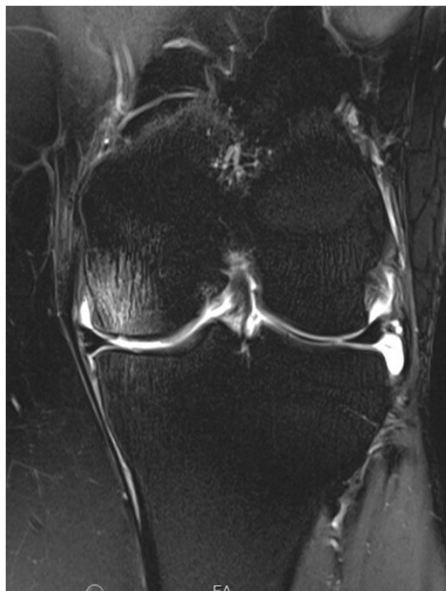## High Tibia Osteotomy Indications in Knee OA

	HTO	HTO vs. UKA	UKA
Age	<45	45-55	>55
OA Grade	KL 1-3	KL 4 → UKA	KL 3-4
Deformity	5 – 20° varus	>10° → HTO	≤10°
Activity	Any activity level		Low impact activities
Bottom line	More durable for laborer or runners – willing to tolerate some pain	Individualized discussion with patient	Better pain relief and functional outcomes

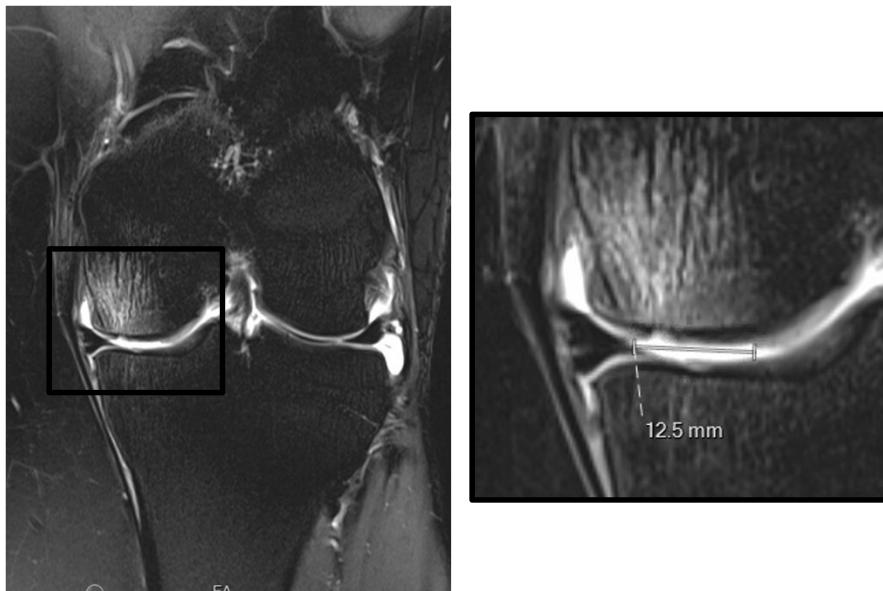
## Case Example



- 45 yo F worsening medial joint line pain
- Recurrent knee effusion
- Steroid injection provided 1 month relief

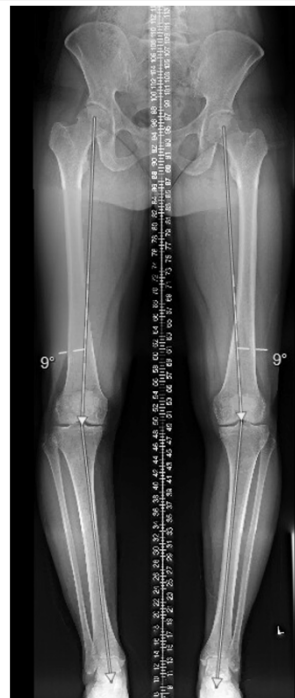

- MRI
  - ♦ Full thickness cartilage defect
  - ♦ Subchondral edema



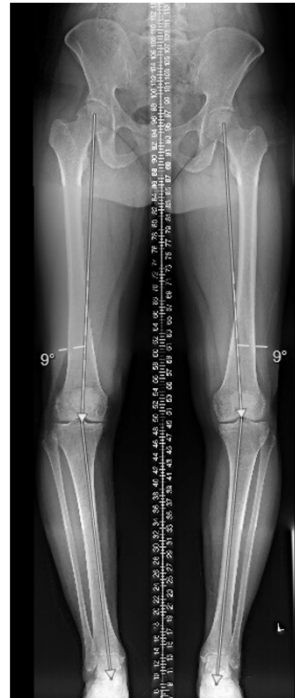## Full Length X-rays

- Varus Malalignment
- Dx?



## Full Length X-rays

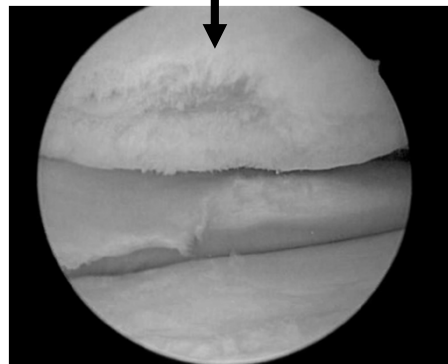
- Varus Malalignment
- Dx?
  - ♦ Medial compartment overload



## Treatment

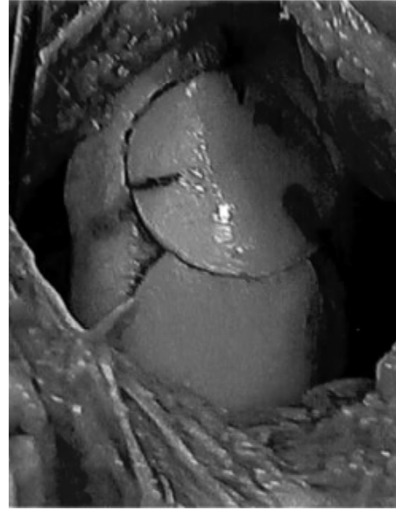
- Steroid injection
- Medial unloader brace
- Arthroscopic staging procedure
  - ♦ Chondroplasty, loose body removal

Medial femoral condyle

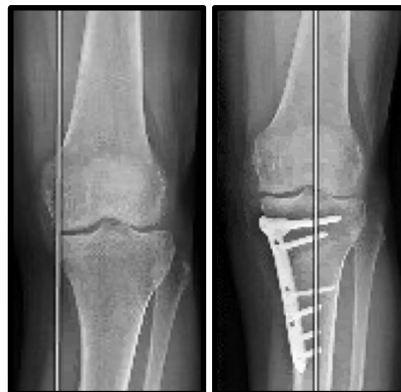
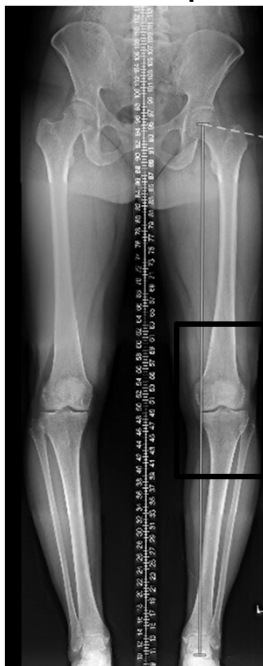
## Second-Stage

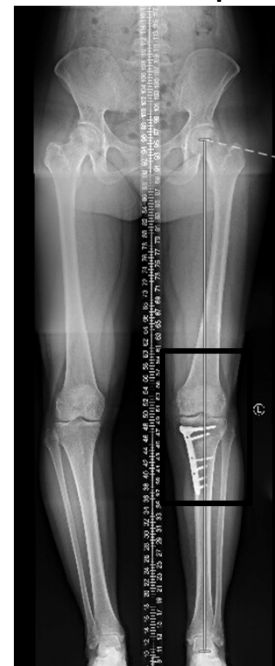- “Snowman”  
Osteochondral allograft
- Valgus producing high  
tibia osteotomy
  - ♦ Mechanical  
environment



Pre-op

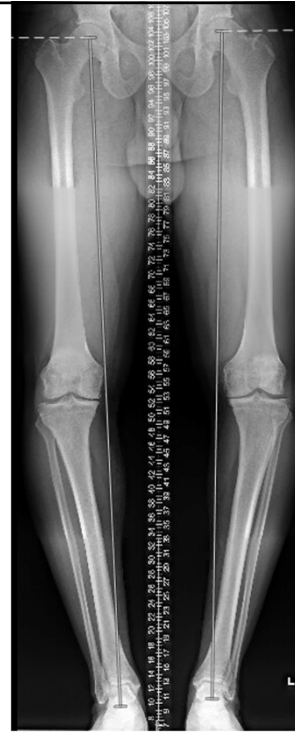

Post-op



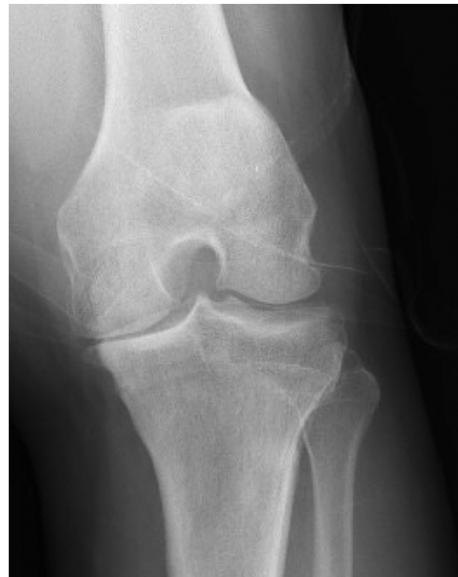## Case Example

- 44 M worsening bilateral knee pain
- Failed multiple conservative treatments
- Construction worker

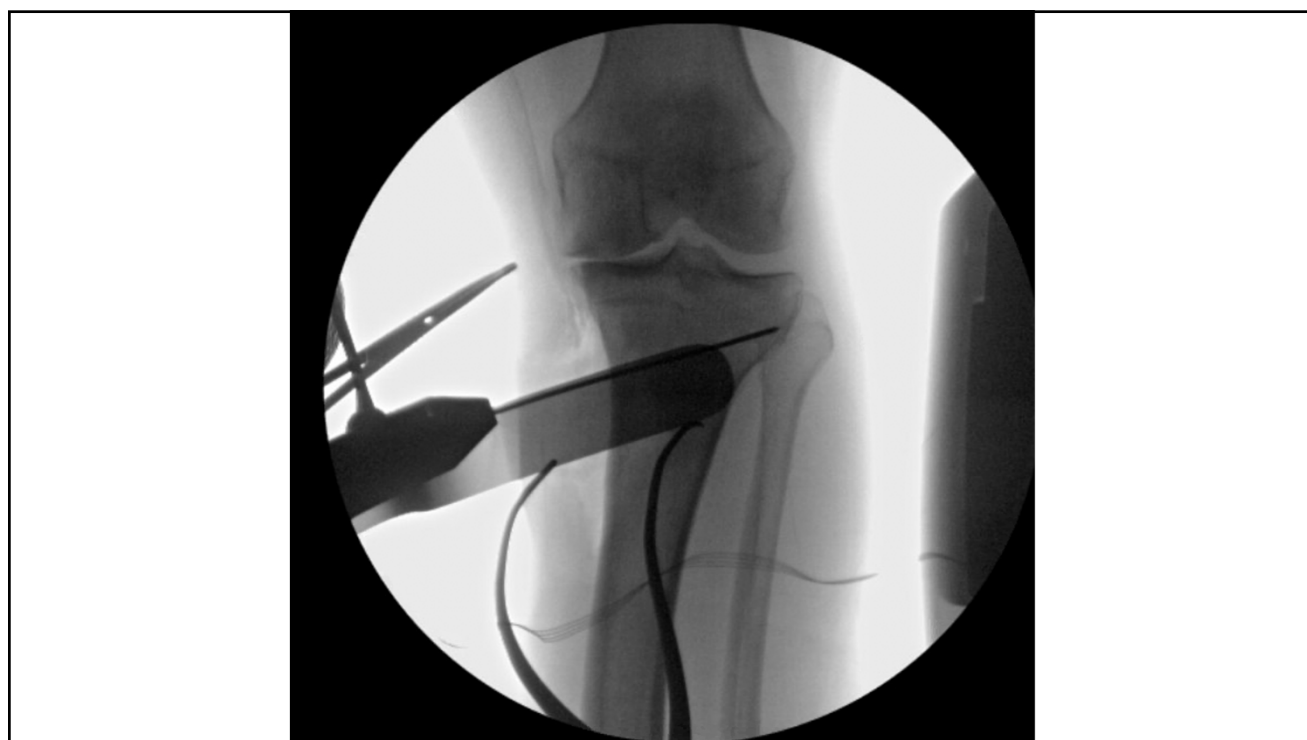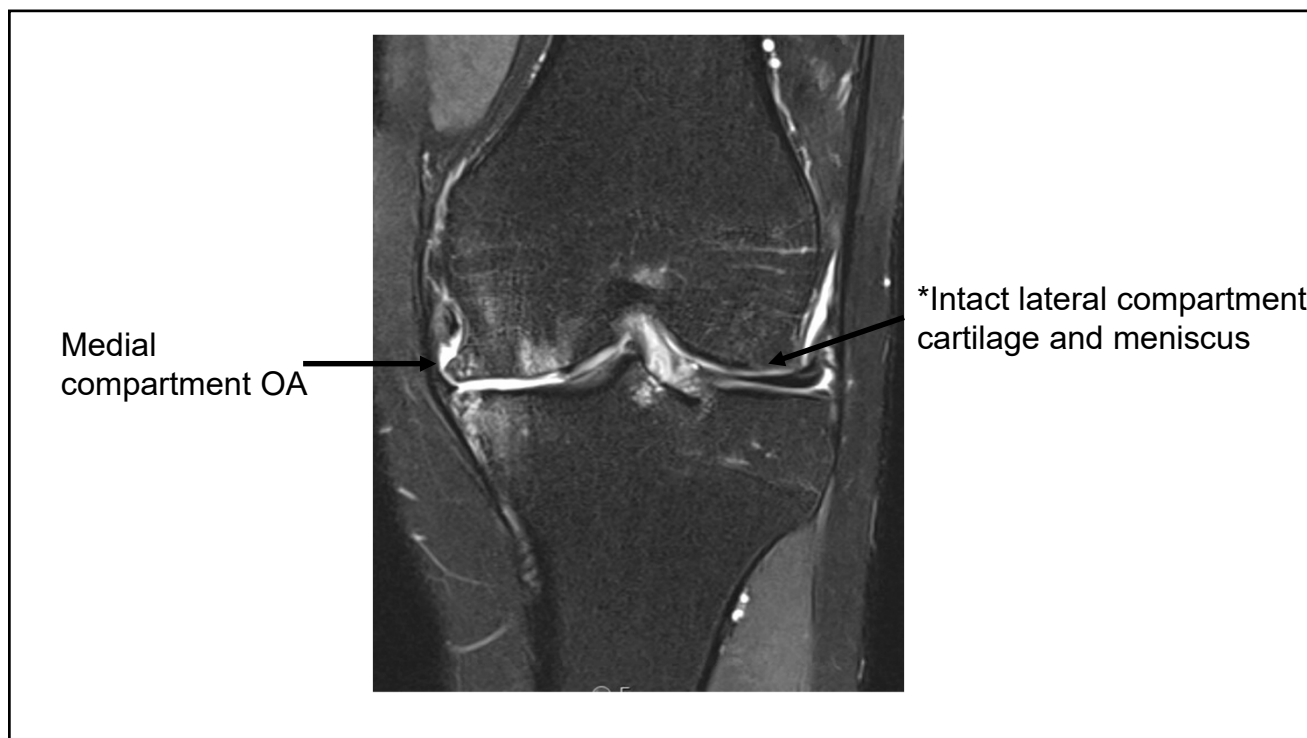


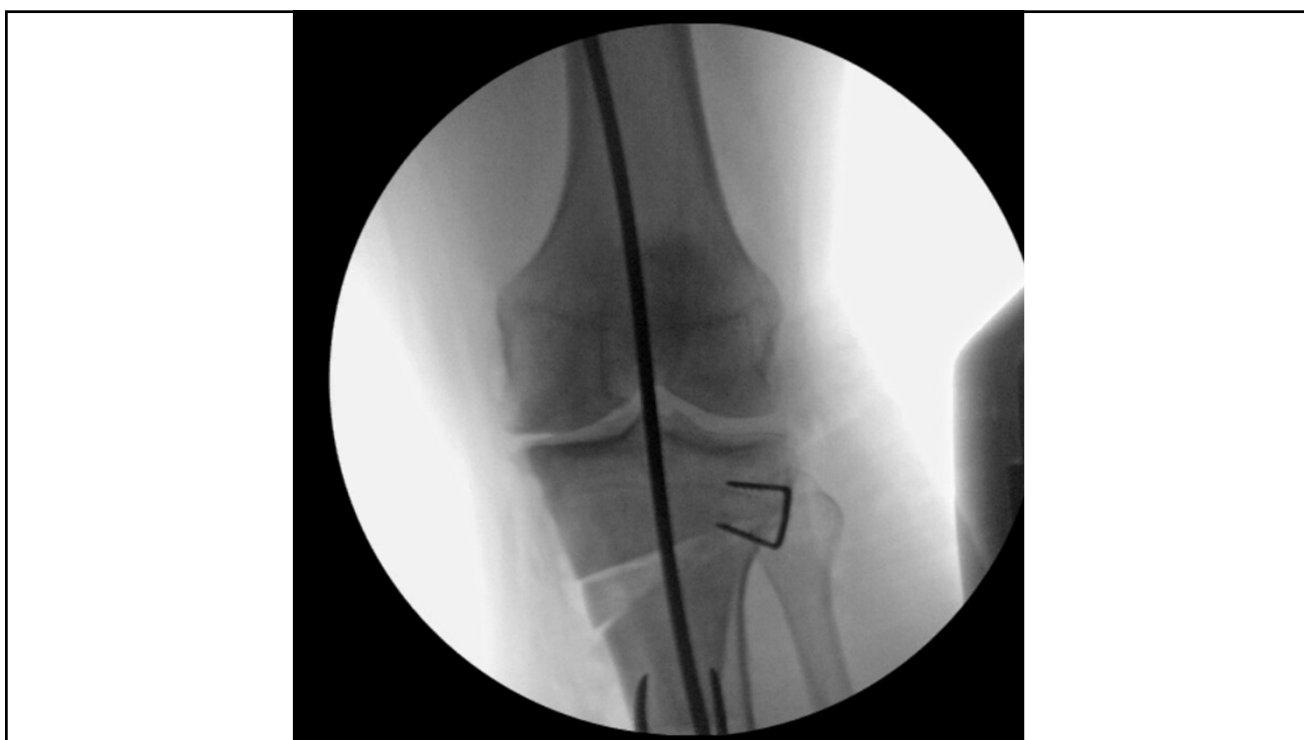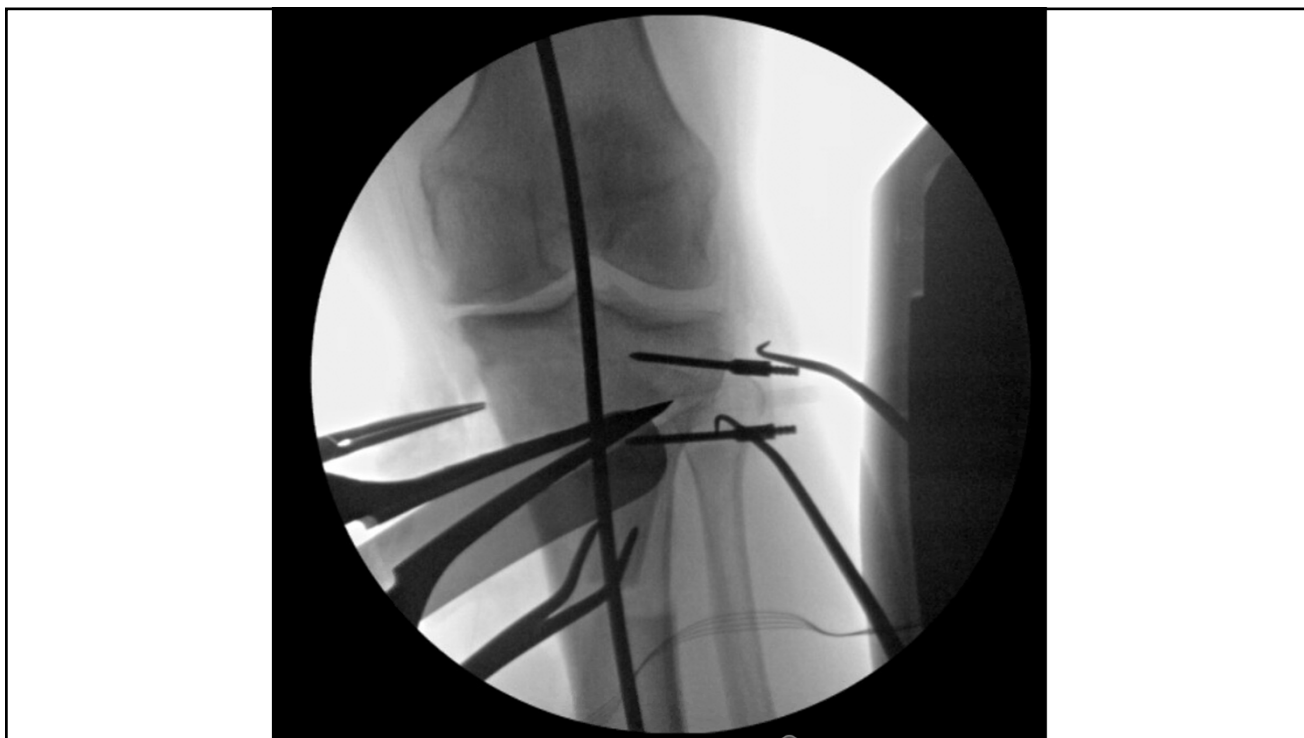## Case Example

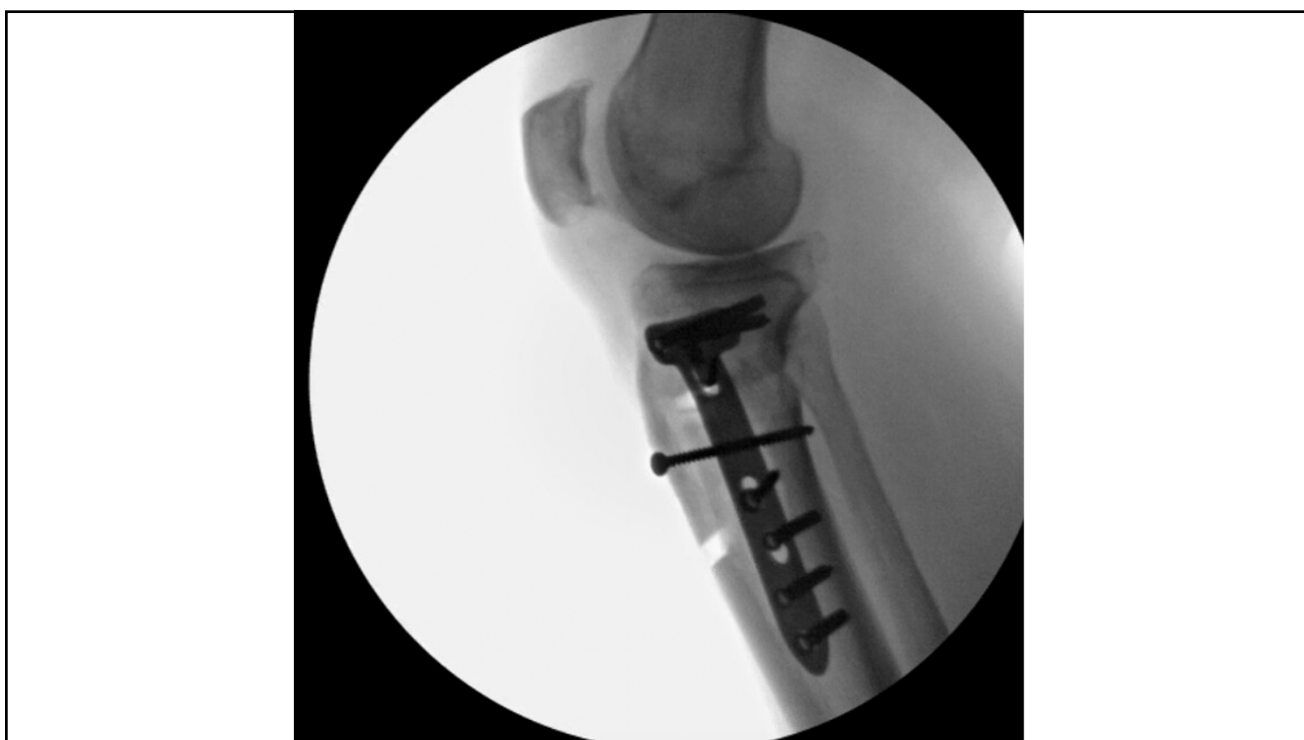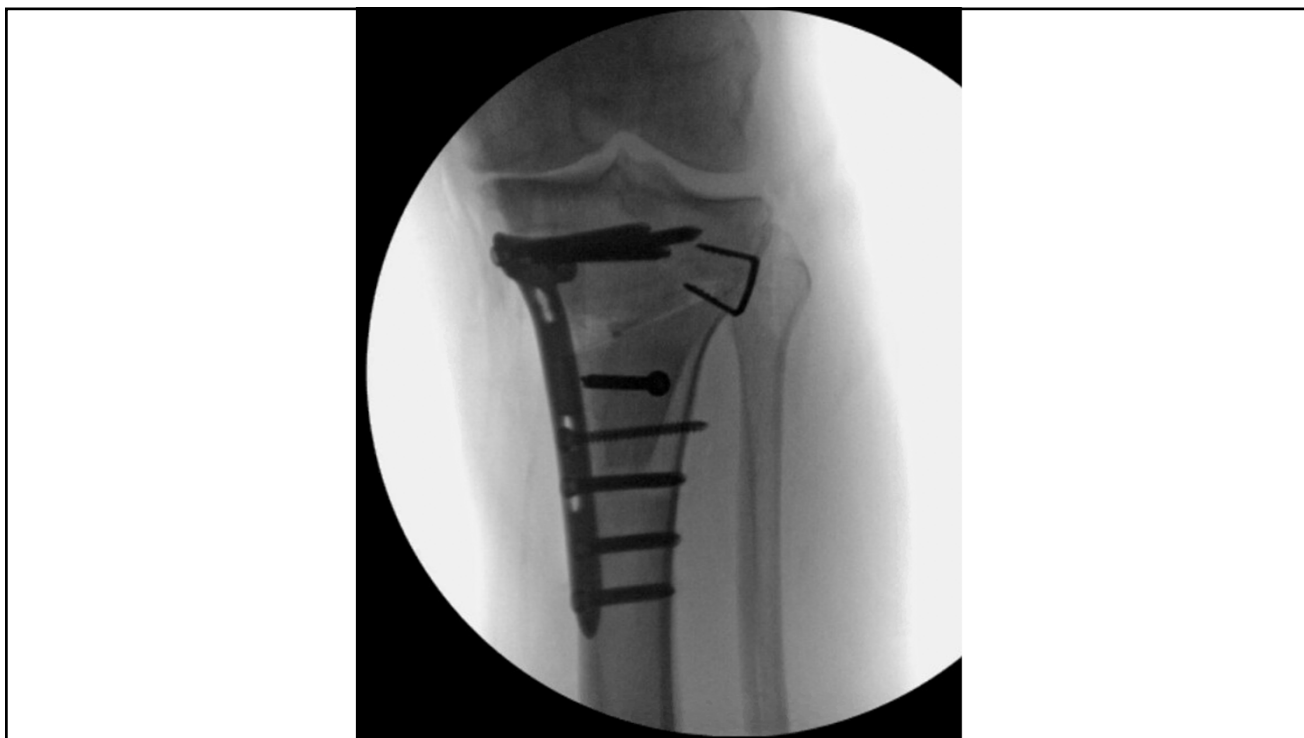- Rosenberg View
- Kellgren Lawrence Grade 3





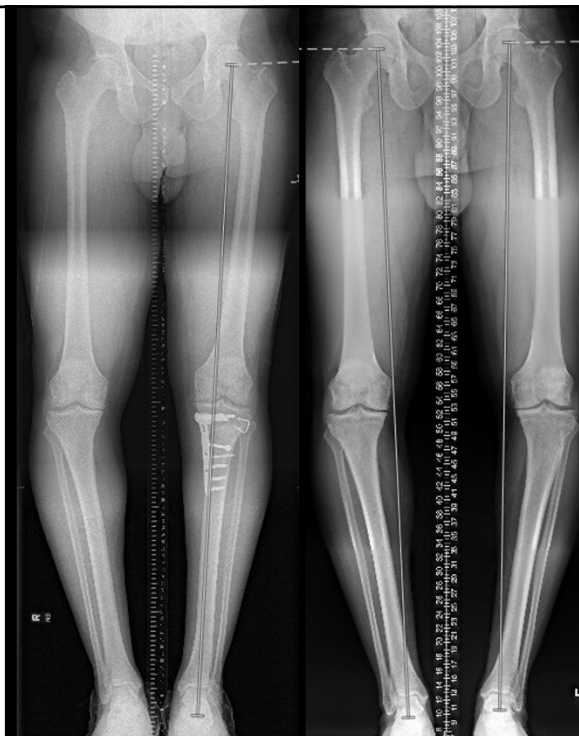
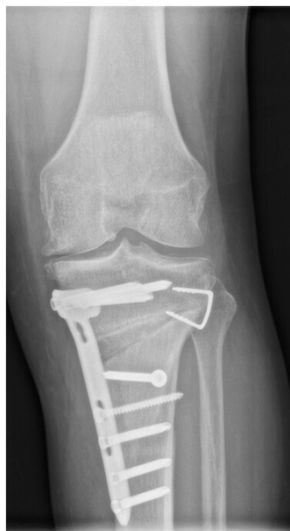




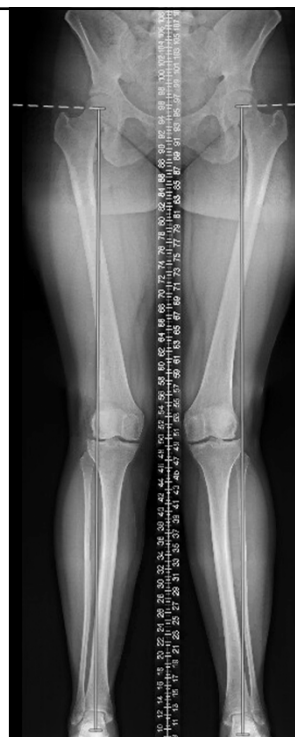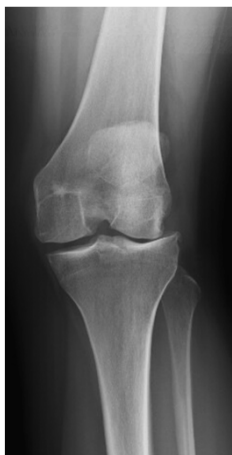## Case Example

- 5 months post-op



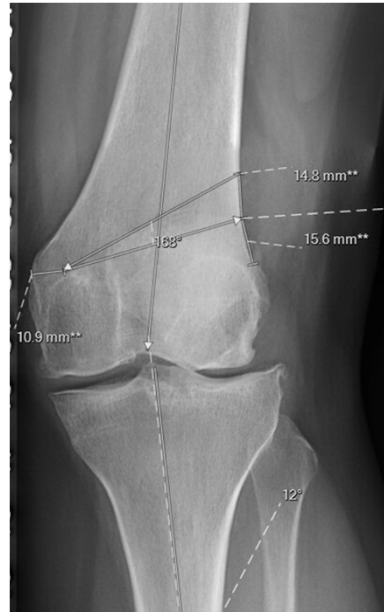## Valgus Malalignment

- 30 yo F
- Worsening pain
- Multiple knee arthroscopic surgeries
- Told that only option was TKA

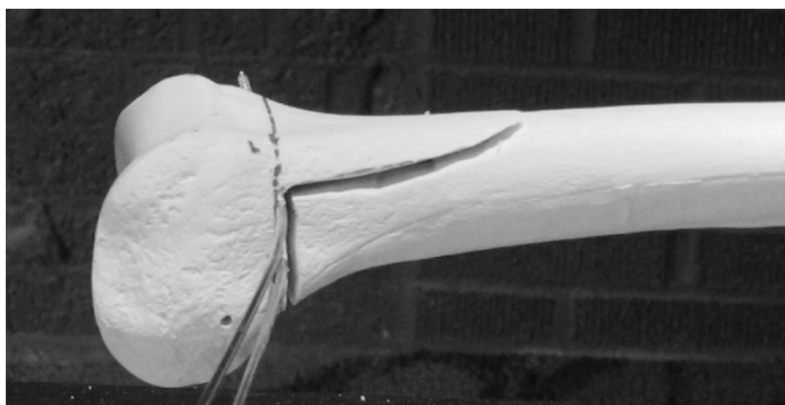

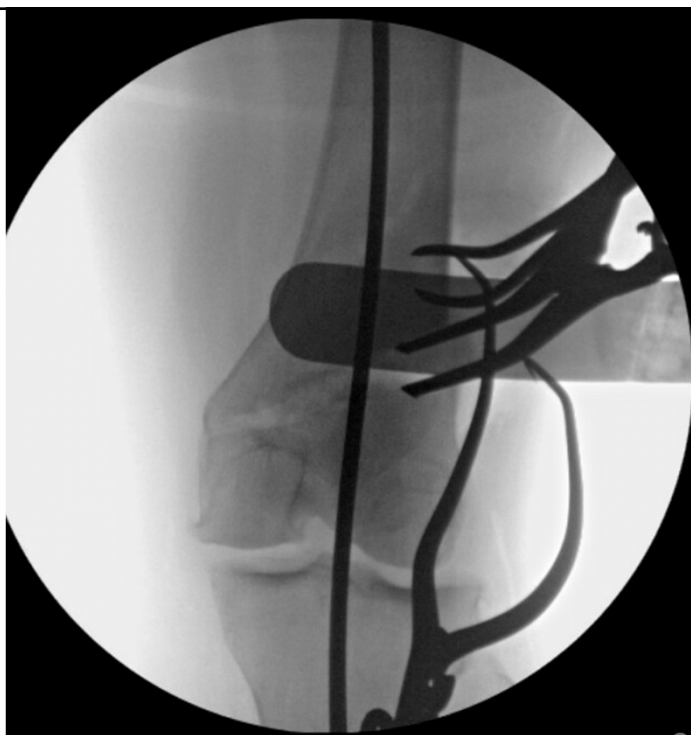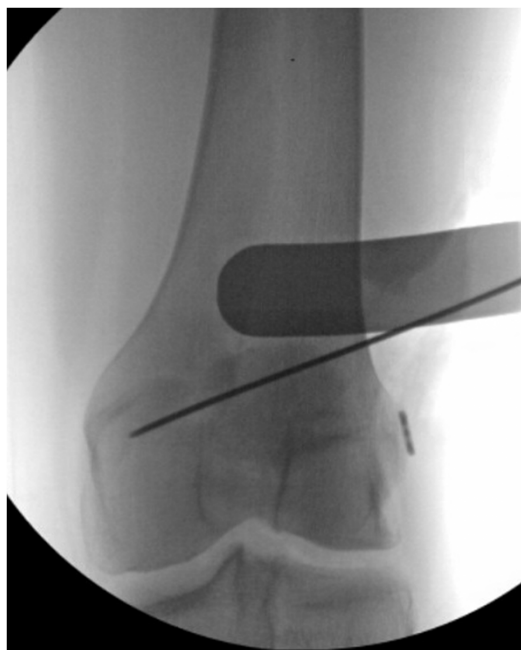## Distal Femur Osteotomy Templating

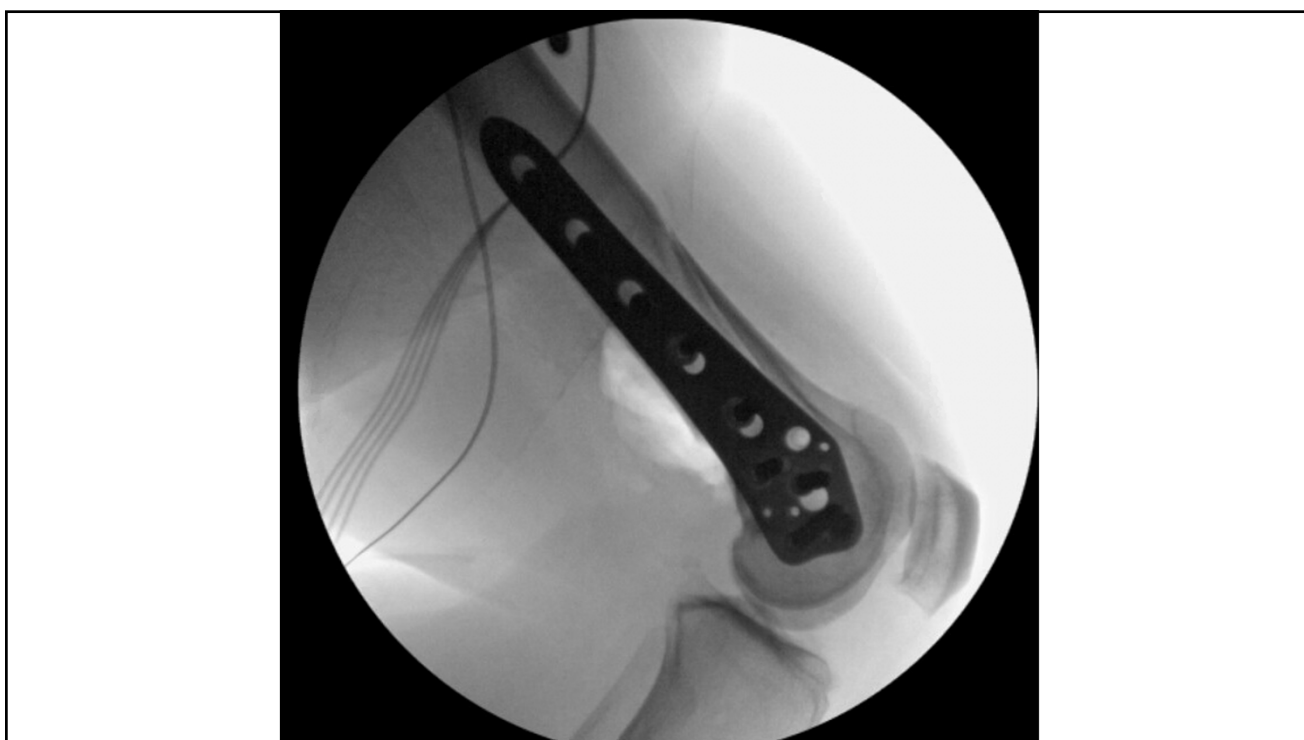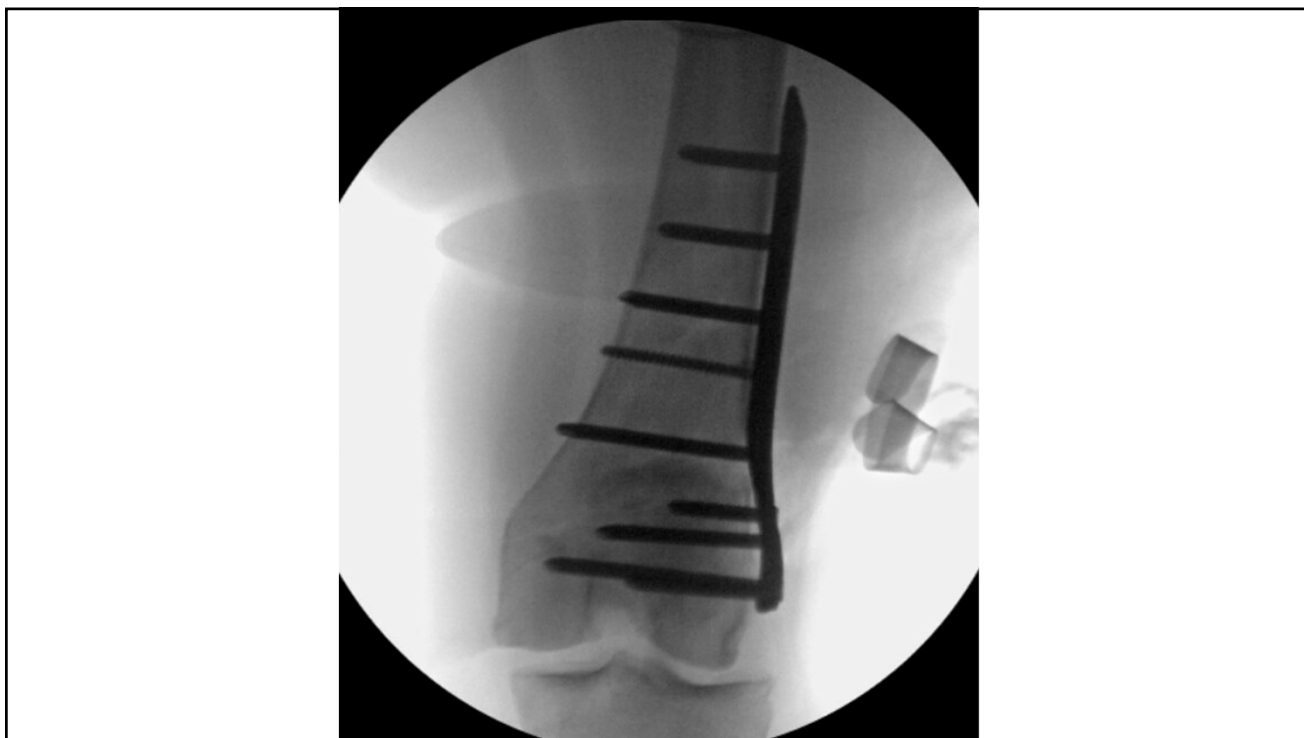- 12° Valgus
- Calculated 14.8 mm correction

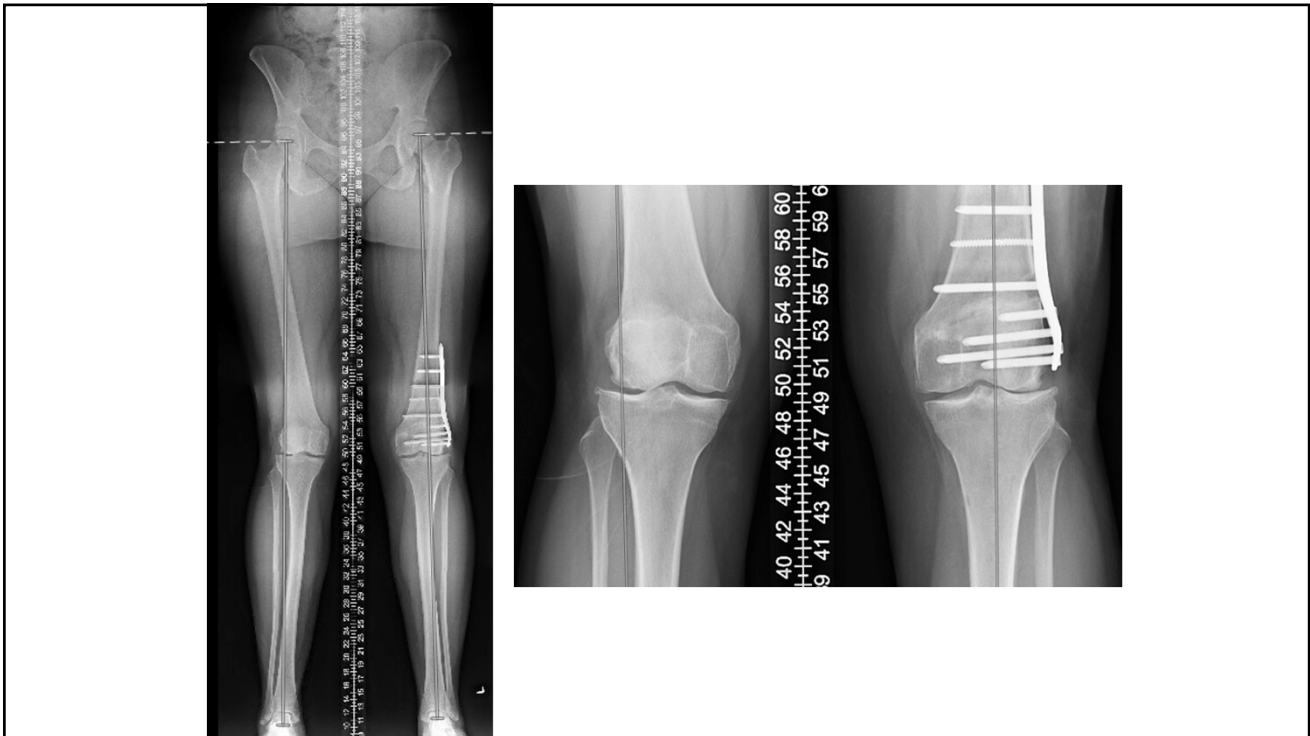


## Distal Femur Osteotomy Biplanar Technique









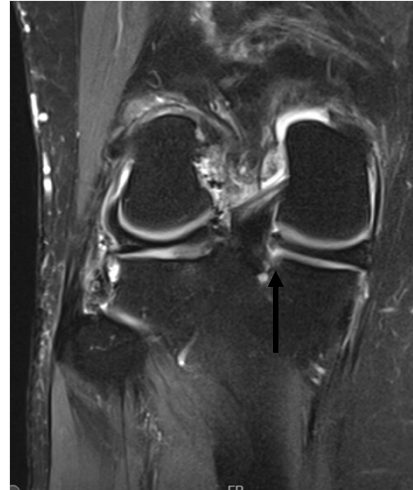
## Osteotomy Outcomes in Knee OA

- High tibial osteotomy for varus knee OA
  - ♦ 10-year survivorship 74-95%
  - ♦ 15-year survivorship 67-90%
  
- Distal femur osteotomy for valgus knee OA
  - ♦ 10-year mean survivorship 80%



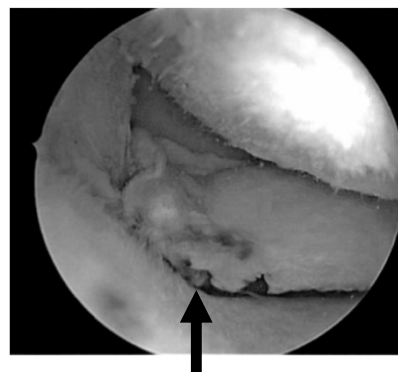
## Medial Meniscus Posterior Root Tears

- “The Silent Epidemic” in joint preservation
- Often missed on MRI and arthroscopy
- Can lead to rapid OA
  - ♦ Inability to resist hoop stresses
  - ♦ Meniscal extrusion
  - ♦ Cartilage breakdown
  - ♦ Insufficiency fractures
- Early Dx important



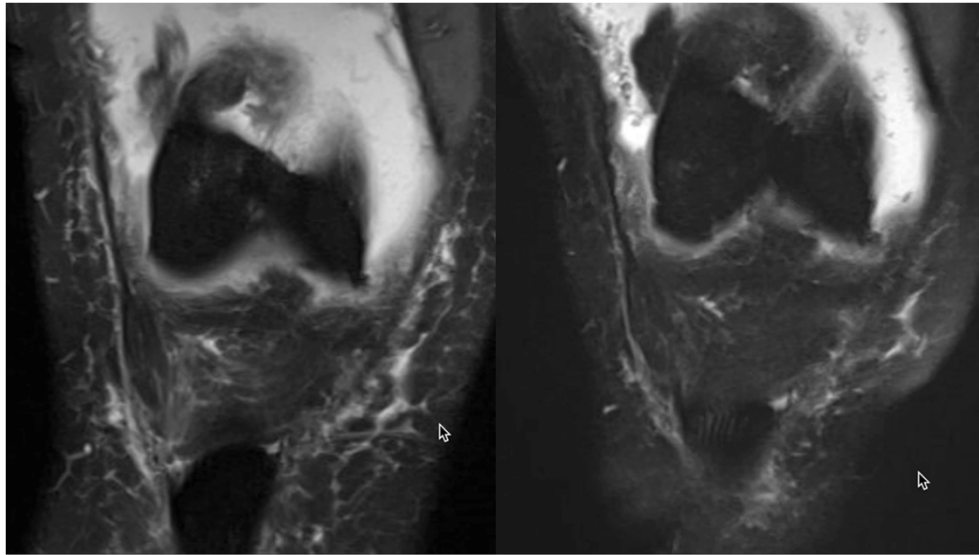
## Diagnosis

- 40-60yo F
  - ♦ Posteromedial knee pain
  - ♦ BMI 30-40
- Minor trauma
  - ♦ i.e. Stepping off curb
  - ♦ Felt a “pop”
  - ♦ Sudden severe pain
- + Joint effusion, Medial joint line tenderness



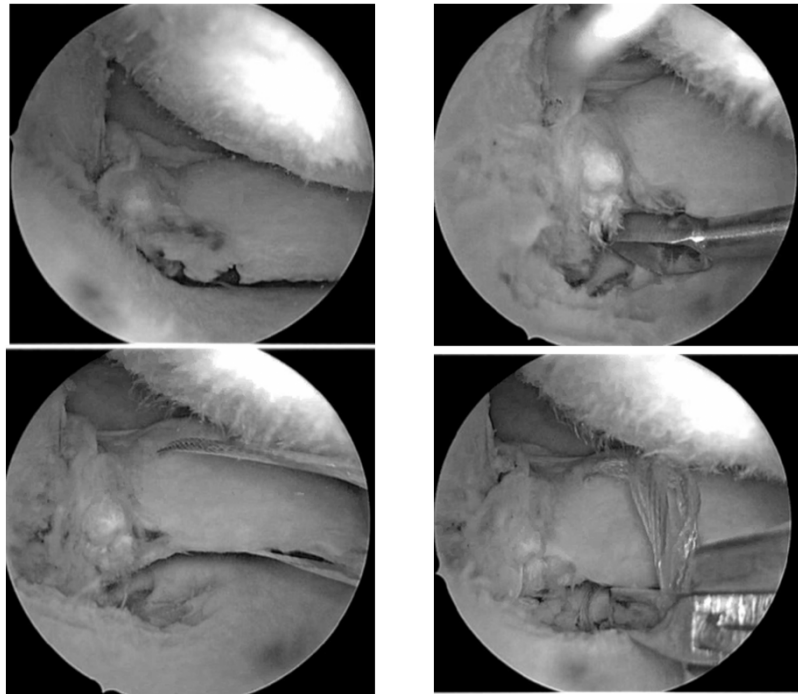
MRI: 7/26/19

10/27/2020




## Treatment

- Historically, treated conservatively or with partial meniscectomy
- Improved surgical techniques → Transtibial meniscus root repair
- Goal: Restore hoop stresses to minimize OA
- Risk of progression to OA over 10 years
  - ♦ Conservative – 95.1%
  - ♦ Partial meniscectomy – 99.3%
  - ♦ Meniscus repair – 53% (Newer techniques lower)

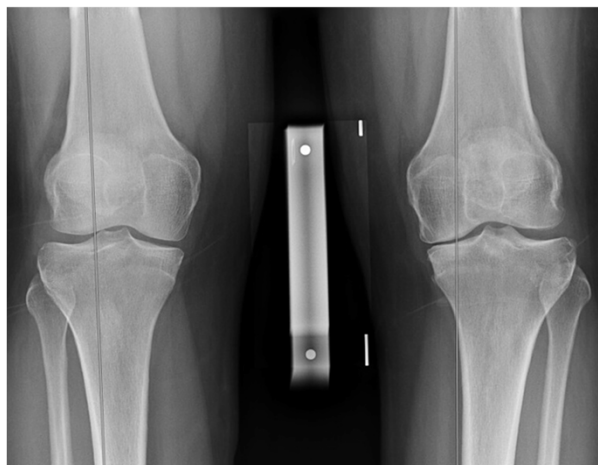
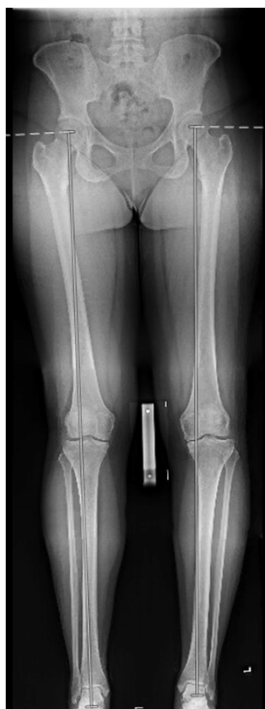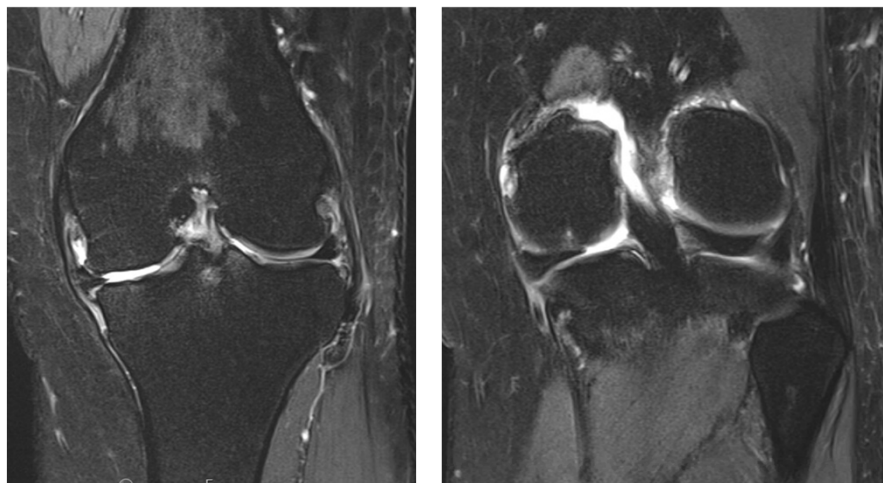


## Meniscus Root Repair

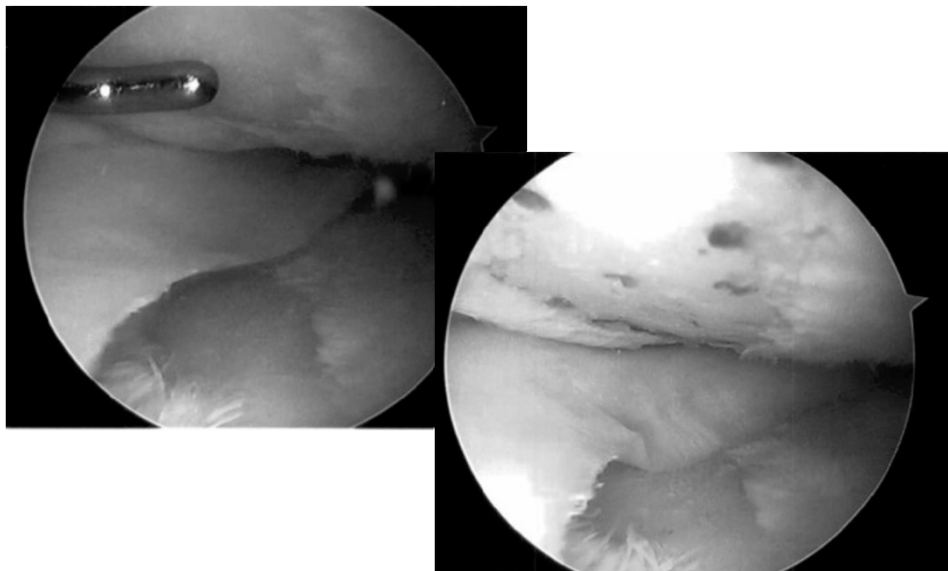
- Post-op
  - ♦ 4 weeks of Non-weight bearing
  - ♦ 2 weeks of slow progression to WB
- 1 year in medial unloader brace to protect repair



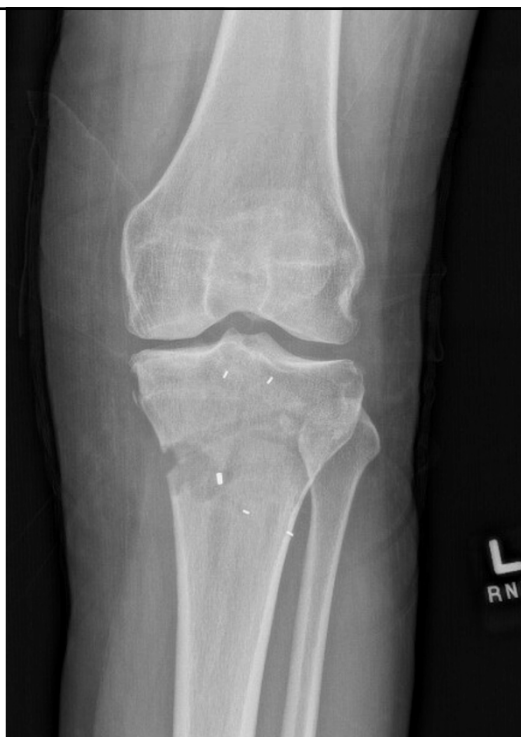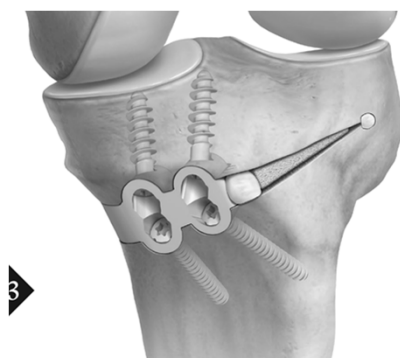
**Case Example:**  
**38yo F worsening medial joint pain**



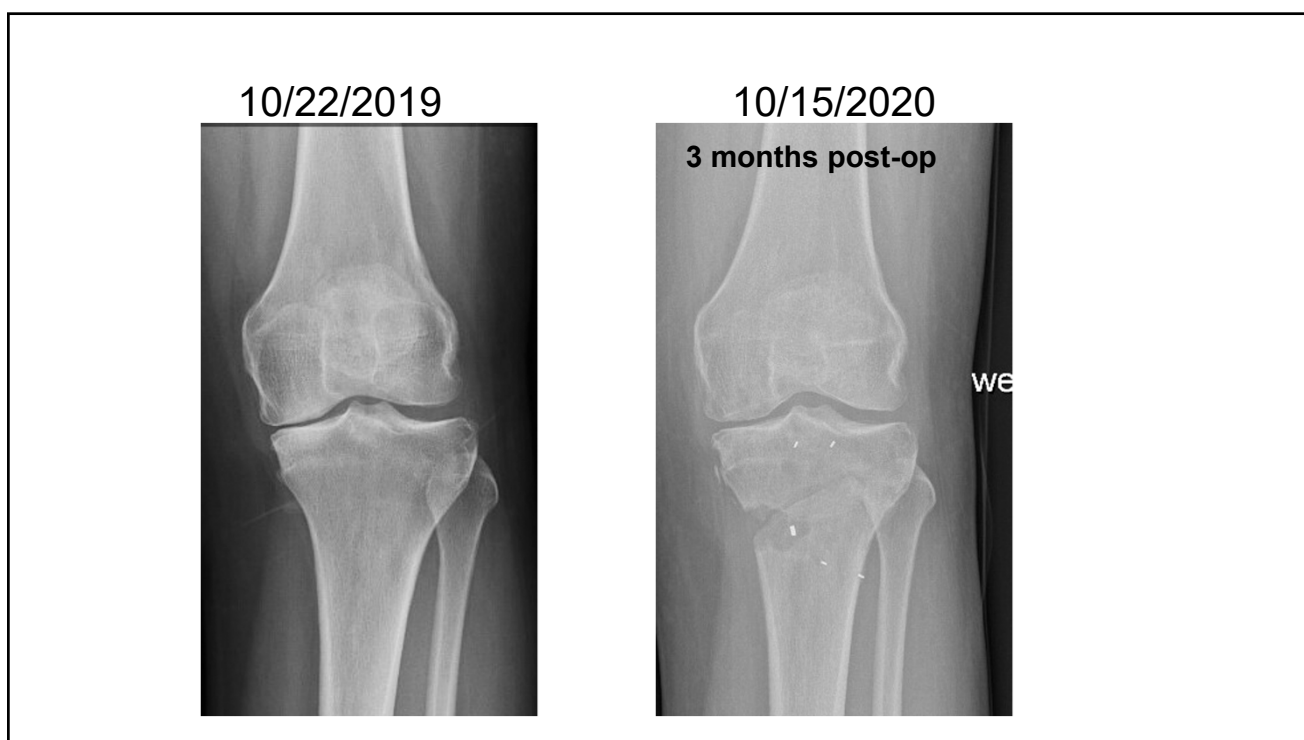
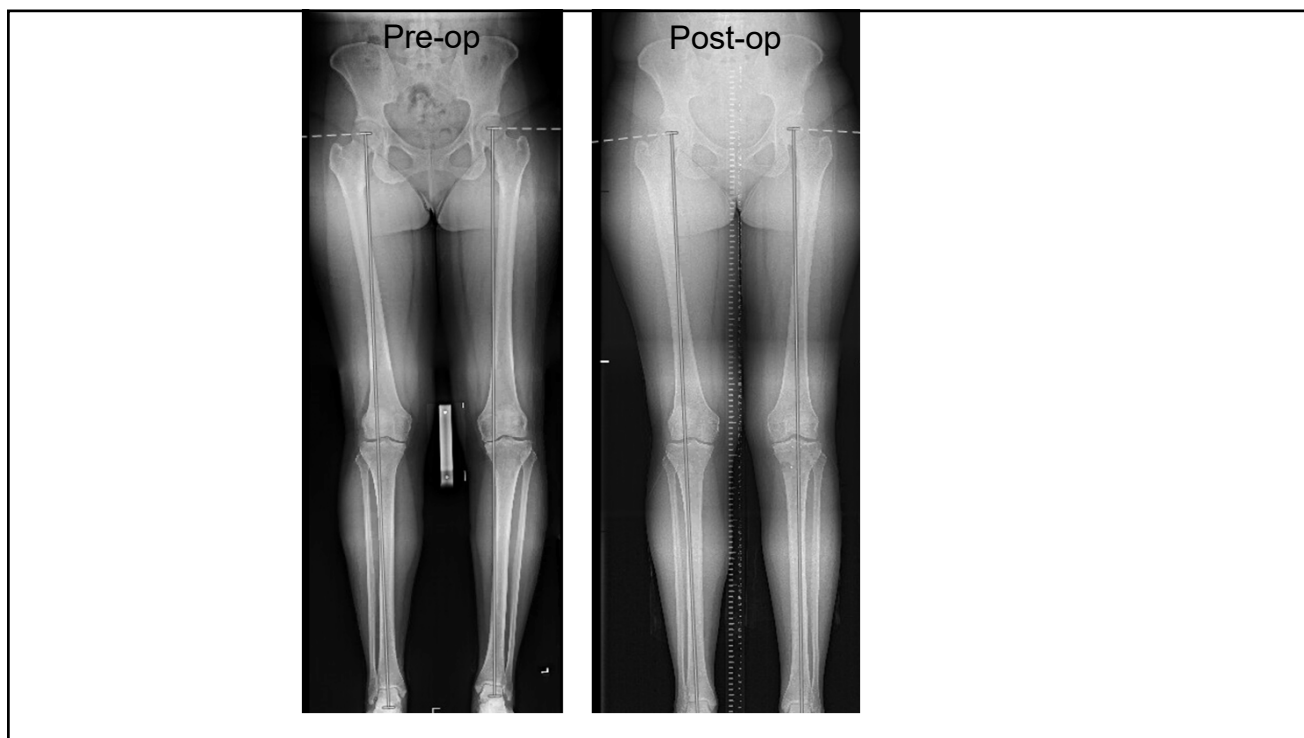
## Meniscus root repair + Microfracture + PRP



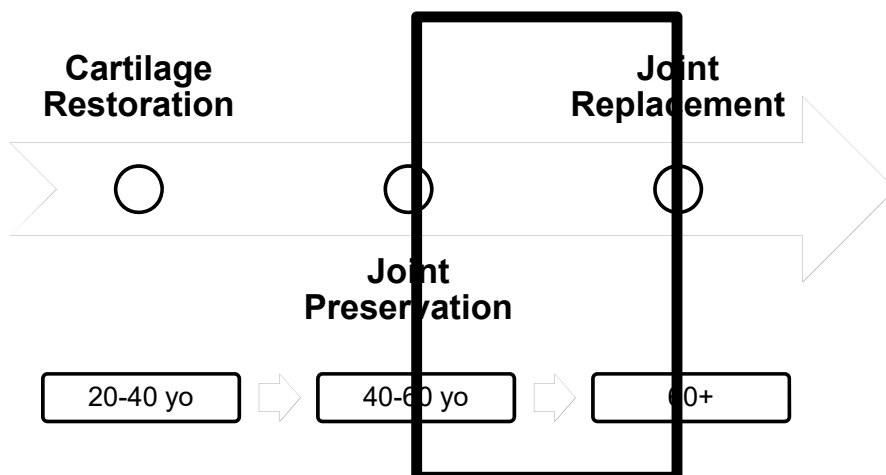
## Arthrex iBalance HTO



Polacek, Martin & Nyegaard, Cecilie & Høien, Fredrik. (2020). Day-Case Opening Wedge High Tibial Osteotomy With Intraosseous PEEK Implant. Arthroscopy, Sports Medicine, and Rehabilitation. 2. 10.1016/j.asmr.2020.01.005. - (CC BY-NC-ND 4.0)

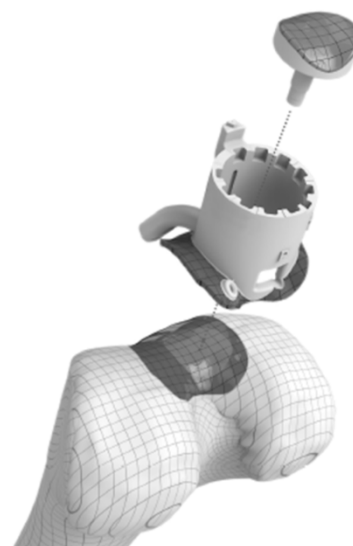


## Surgical Options in Knee OA




## Emerging Surgical Techniques

- Episealer Implant
  - ♦ Patient-specific implant based on MRI
  - ♦ Remove damaged bone and cartilage
  - ♦ Replace with cobalt-chrome alloy
- US Clinical trial starting at OSU Spring 2021



## Emerging Surgical Techniques



## Emerging Surgical Techniques

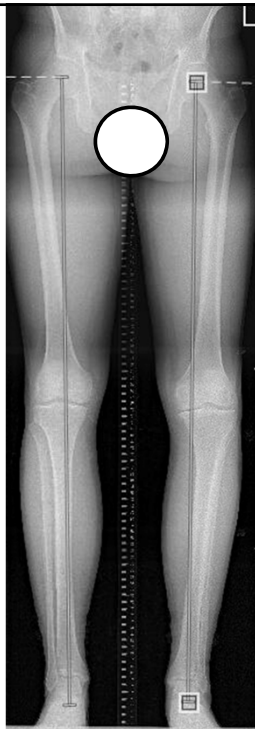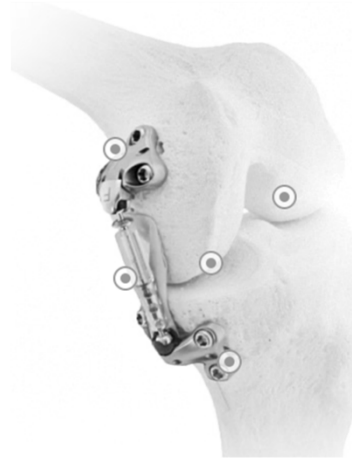
- NuSurface
  - ♦ Polycarbonate-urethane meniscus replacement device
  - ♦ Used in patients after meniscectomy
  - ♦ Mimics function of normal meniscus and redistributes load transmission across joint
- Approved in Europe since 2008
- Ongoing FDA clinical trial
  - ♦ First device implanted at OSU



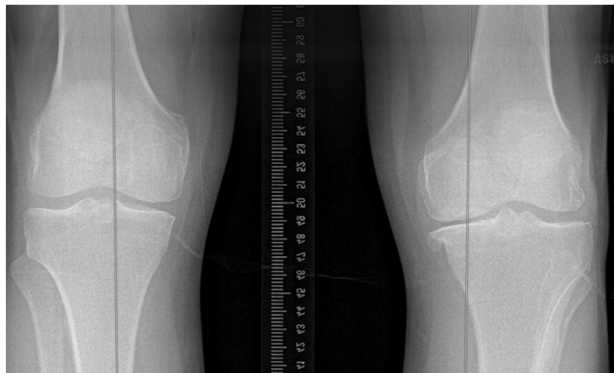

# Emerging Surgical Techniques

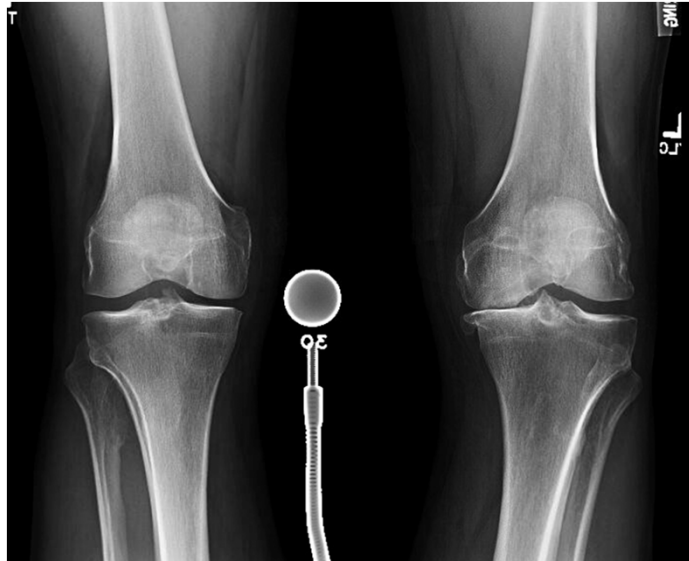- Moximed Atlas
  - ♦ Implantable joint unloader
- Ongoing US Clinical trial



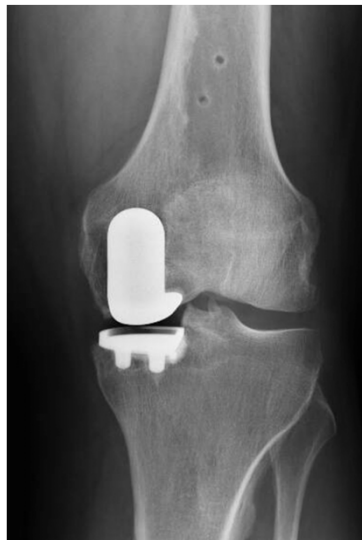Case Example: 58 yo M  
- Years of worsening pain  
- Previous conservative Tx  
- Wants to get back to working out



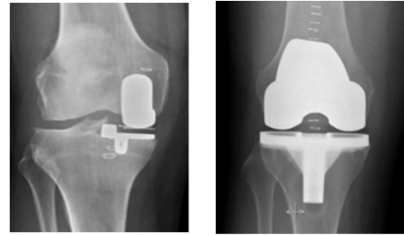
## Rosenberg View



## Robotic-assisted Partial Knee Arthroplasty



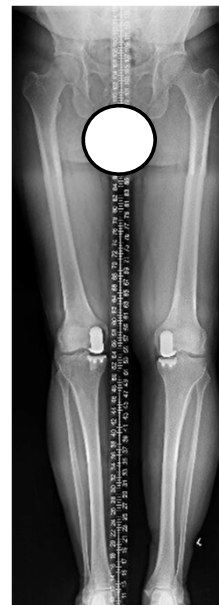## Advantages of UKA



- Compared to TKA
  - ♦ Less blood loss
  - ♦ Less morbidity (smaller incision, less pain)
  - ♦ Shorter hospital stay
  - ♦ Faster recovery and rehab
  - ♦ Preservation of normal knee kinematics (ACL, PCL, lateral and PF joints)

## Advantages of UKA

- Compared to HTO
  - ♦ Faster recovery and rehab
  - ♦ Higher initial success rates
  - ♦ Fewer short term complications
  - ♦ Longer durability
  - ♦ Easier to convert to TKA (Historically)



## **Intra-articular Injection Options**

- Corticosteroids
- Hyaluronic Acid
- Orthobiologics:
  - ♦ Platelet Rich Plasma (PRP)
  - ♦ Adipose derived stromal cells
  - ♦ Bone marrow derived mesenchymal stem cells
  - ♦ Amniotic-derived therapies

## **Corticosteroids Efficacy**

- Randomized controlled trials
  - ♦ Evidence that IA steroids are effective to reduce pain, but benefit over placebo is short-lived (4-6 weeks)
  - ♦ Inconsistent effects on functional outcomes
- Presence of an effusion is a good predictor for positive effect of Steroid (esp. with aspiration)

## **Corticosteroids Risks and Side Effects**

- Steroid flare
  - ♦ May begin 6-12h post-injection, last 1-3 days
- Inconclusive evidence
  - ♦ Accelerated disease progression
  - ♦ Osteonecrosis
  - ♦ Insufficiency fractures

## **Steroid Injections – Bottom Line**

- Consider in patients during “OA flare” with moderate to severe pain and large effusion
  - ♦ Short-term pain relief
- Minimum 3 months before repeat injection
- Counsel patients regarding no long-term benefit and risks of OA progression
  - ♦ Risk of disease progression may increase with repeated injections

## **Hyaluronic Acid**

- HA is naturally occurring glycosaminoglycan and component of Synovial Fluid and Cartilage matrix
- Acts as viscous lubricant during slow joint movements and as elastic shock absorber during rapid joint movement
- Functions through anti-inflammatory, anabolic, analgesic, and chondroprotective mechanisms
- Harvested from Rooster combs or via bacterial fermentation

## **Hyaluronic Acid Efficacy**

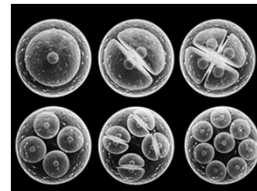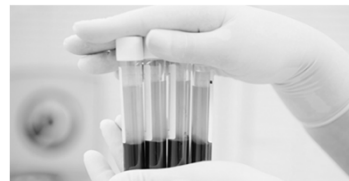
- Conflicting clinical data
- Meta-analyses
  - ♦ 2 concluded overall beneficial effect
  - ♦ 4 reported small benefit
  - ♦ 2 found no evidence to support use
- >50% studies industry funded → Risks of publication bias
- Adverse effects → transient local reaction 2-4% (higher rates with avian-based)

## Hyaluronic Acid Bottom Line

- Intra-articular injection of HA is safe with low risk of local reaction
  - ♦ Recommend 15 minutes icing immediately after injection
- May provide pain reduction in mild OA for up to 6 months
- Cost-effectiveness is questionable, especially in patients with moderate-severe OA

## Orthobiologics

- Platelet Rich Plasma (PRP)
- Adipose derived stromal cells
- Bone marrow derived mesenchymal stem cells
- Amniotic-based therapies



## What is PRP?

- Autologous concentration of human platelets in a small volume of plasma produced from a patient's own centrifugated blood
- Concentrated platelets contain increased amounts of growth and differentiation factors
- At concentrations >1,000,000 per microliter → improvements in bone and soft tissue healing properties have been demonstrated

## PRP in Knee OA

- Relatively safe procedure with minimal adverse effects (pain, effusion)
- Strong evidence that:
  - ♦ PRP may exert positive influence in patients with knee OA
  - ♦ RCTs demonstrate greater and longer efficacy for pain and function versus HA and placebo
  - ♦ Beneficial effect estimated to last up to 1 year with peak at 6 months
- Best results in younger patients with mild OA




# Stem Cell-Based Therapies

- Knee OA
  - ♦ Limitation of cartilage is inability to heal or regenerate
  - ♦ After injury → Typically fibrocartilage forms and can more easily break down leading to OA
- Mesenchymal Stem Cells or Medicinal signaling cells (MSCs) may provide biologic machinery to organize the complex processes involved in the regenerative process


## Stem Cell-Based Therapies

- Stem cells provide functions that can assist the healing:

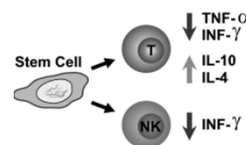
- ♦ Differentiate into terminal cells
- ♦ Reduce inflammation
- ♦ Secrete growth factors
- ♦ Encourage cell migration
- ♦ Coordinate tissue repair



Stem Cells (MSCs)



Guided tissue regeneration



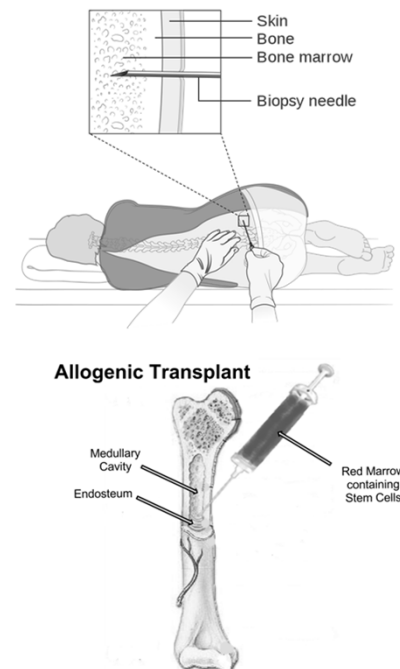
Regulate immune system to reduce inflammation

## Challenges of Stem Cell-Based Therapies

- Efficient isolation and delivery
- Unclear optimal number of cells needed to achieve regeneration
- Regulatory restrictions by FDA
  - ♦ Cannot expand or manipulate MSCs outside of the body
  - ♦ Only allow simple mechanical preparation (Centrifugation)

## Bone Marrow Derived Stem Cells

- Bone marrow aspirate concentrate (BMAC)
- Harvested from iliac crest, proximal tibia, or distal femur
- Centrifugation to concentrate MSCs
- Pros: Ease to harvest, large yield of cells
- Cons: Donor site pain, cost (procedure), effectiveness limited by patient health/age



## Adipose Derived Stem Cells

- Lipoaspirate from abdomen
- Mechanical process to wash out the lipids to retain stromal vascular fraction that is rich in stem cells
- Pros: No significant decline of cell number with age, ease of harvest, large cell yield
- Cons: Morbidity, cost (procedure)

## Stem Cells in Knee OA

- Promising pre-clinical data in animal studies
- Clinical studies report improvements in pain and function over baseline up to 2 years
  - ♦ Conclusions limited by small sample size, no control group, variable preparations and outcome measures
- Optimal cell dose and long-term durability unclear

## Amniotic-Derived Therapies

- Amniotic Membrane
  - ♦ Extra-cellular matrix components
  - ♦ Multiple collagen types, fibronectin, laminins, aggrecan, hyaluronic acid
- Amniotic-derived stem cells
  - ♦ Human amnion epithelial cells (hAECs)
  - ♦ Human amnion mesenchymal stromal cells (hAMSCs)
- Amniotic Fluid
- Recovered during C-section from consenting, healthy, pre-screened donors

## Amniotic-Derived Therapies

- **Bioactive characteristics**
  - ♦ Anti-microbial
  - ♦ Anti-tumorigenic
  - ♦ Anti-fibrotic
  - ♦ Anti-inflammatory
- **Clinical benefits**
  - ♦ Reduces pain and inflammation (ECM components)
  - ♦ Inhibits scarring (ECM components)
  - ♦ No immunogenicity (T cell suppression; monocyte inhibition)
  - ♦ Enhances wound healing (bioactive cytokines)

## Amniotic-Derived Therapies

- Long history of safety and efficacy in preventing fibrosis and scarring in wound healing
- Promising pre-clinical evidence for efficacy in knee OA
- Single clinical trial (200 patients with knee OA) demonstrates safe and effective versus saline and HA

## In Summary

- Get your patients moving → Exercise and weight loss are most important initial steps
- Consider Aquatic PT
- Several injectable options
  - ♦ OA Flare → Steroid
  - ♦ Mild OA → HA/Orthobiologics

# In Summary

