



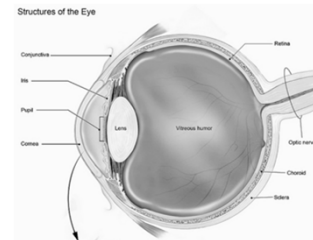
The Red Eye: Differential Diagnosis and Treatment

Tyler Oostra, MD
Assistant Professor - Clinical
Department of Ophthalmology
The Ohio State University Wexner Medical Center

MedNet21
Center for Continuing Medical Education

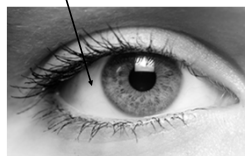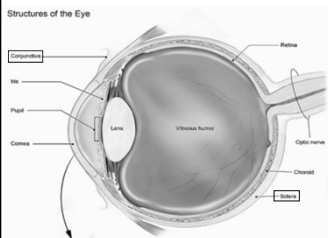
THE OHIO STATE UNIVERSITY
WEXNER MEDICAL CENTER

Brief Overview of Eye Anatomy



Author: <https://www.nei.nih.gov/photo>


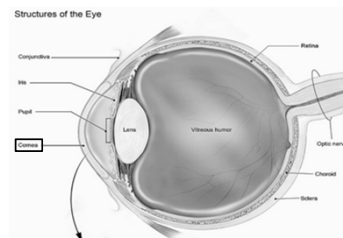
Conjunctiva & Sclera



Author: Laird Keiow (CC BY-SA 3.0)

Source: <https://www.nei.nih.gov/photo>

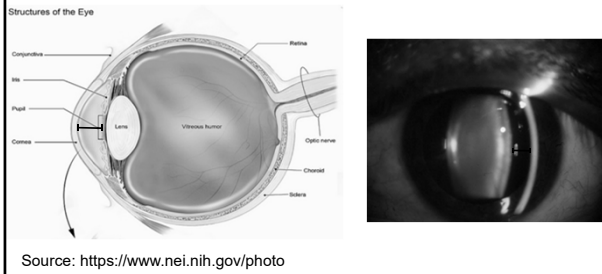
Cornea



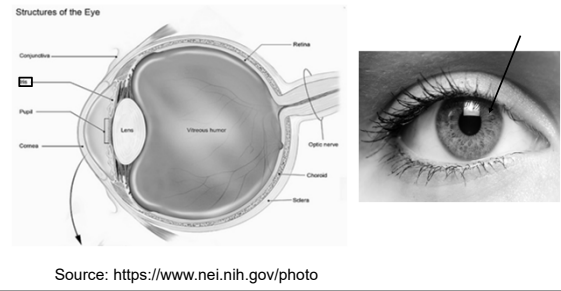
Author: Paul Savage (CC BY 2.0)

Source: <https://www.nei.nih.gov/photo>

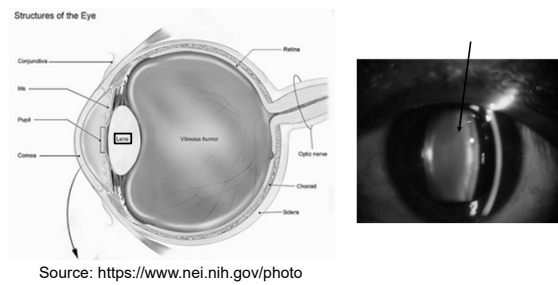
Anterior Chamber



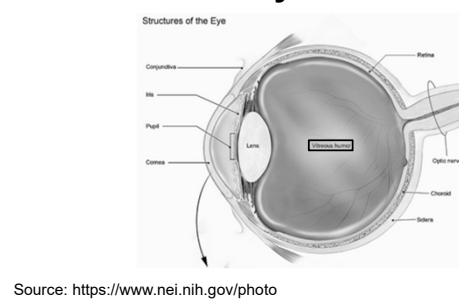
Iris



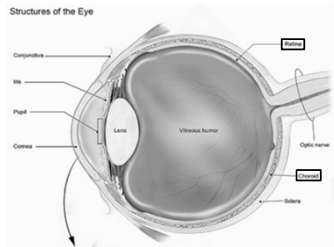
Lens



Vitreous Cavity

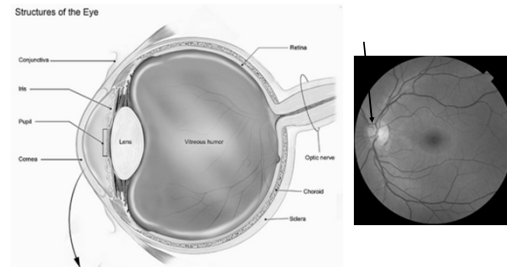


Retina & Choroid



Source: <https://www.nei.nih.gov/photo>

Optic Nerve



Source: <https://www.nei.nih.gov/photo>

Red Eye Differential

• Adnexal causes:

- Trichiasis, distichiasis, floppy eyelid syndrome, entropion/ectropion, lagophthalmos, blepharitis, meibomitis, rosacea, dacryocystitis, canaliculitis

• Conjunctival causes:

- Conjunctivitis (bacterial, viral, chemical, allergic/atopic/vernal, medication toxicity), subconjunctival hemorrhage, inflamed pinguecula, superior limbic keratoconjunctivitis, giant papillary conjunctivitis, conjunctival foreign body, cicatricial pemphigoid, Steven-Johnson syndrome, conjunctival neoplasia

Red Eye Differential

• Corneal causes:

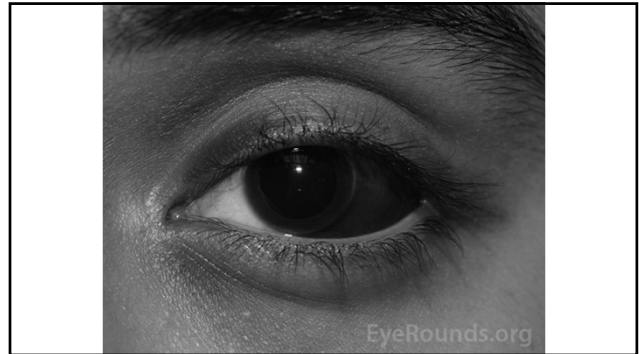- Infectious/inflammatory keratitis, recurrent corneal erosion, pterygium, neurotrophic keratopathy, contact-lens related problems, corneal foreign body, ultraviolet burn

• Other causes:

- Trauma, postoperative, dry-eye syndrome, endophthalmitis, anterior uveitis, episcleritis, scleritis, angle-closure glaucoma, carotid-cavernous fistula, cluster headache

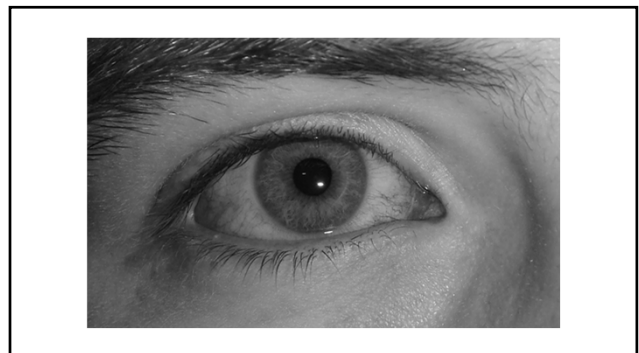
History and Exam

- Trauma?
- Pain?
- Discharge?
- Vision changes?
- Check visual acuity and pupils
- Assess for fluorescein uptake
- Measure intraocular pressure



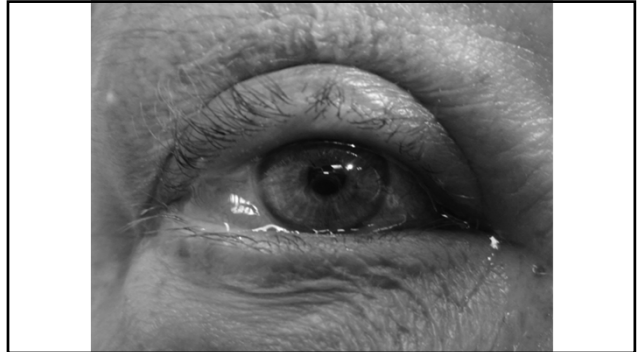Subconjunctival Hemorrhage

- History: trauma, valsalva, blood thinners
- Symptoms: no to minimal pain, redness
- Signs: blood within the subconjunctival space
- Treatment
 - Reassurance
 - Artificial tears
- Follow-up: as needed if fails to resolve over 2-3 weeks or recurs



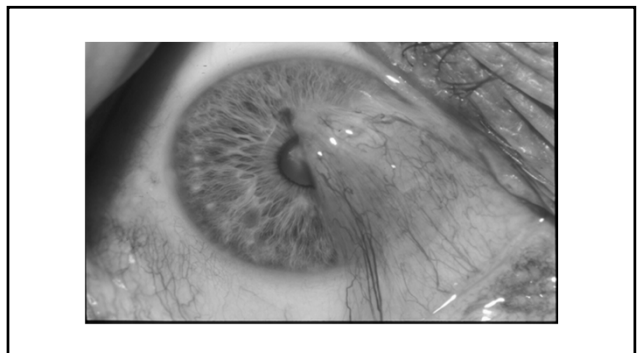
Viral Conjunctivitis

- Symptoms: redness, foreign body sensation, itching, burning, hx of recent URI or sick contacts
- Signs: eyelid redness and edema, conjunctival hyperemia and follicles, watery discharge, tender palpable preauricular lymph node
- Treatment
 - Supportive with artificial tears and cool compresses
 - Frequent hand washing, avoid touching eyes
- Follow-up: 2-3 weeks or sooner if worsens



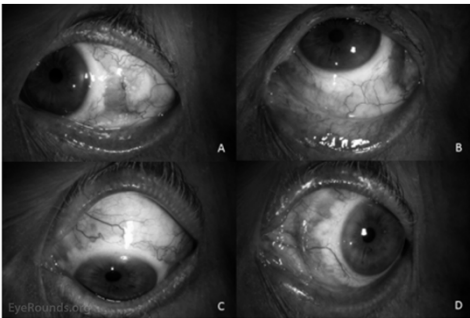
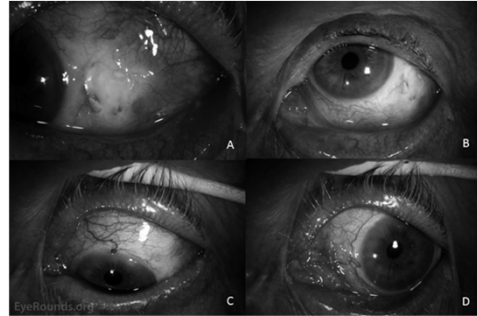
Allergic Conjunctivitis

- Symptoms: itching, burning, redness, hx of allergies
- Signs: eyelid redness and edema, chemosis, conjunctival hyperemia and papillae, watery discharge
- Treatment
 - Eliminate any inciting agent
 - Artificial tears and cool compresses
 - Topical antihistamine and mast cell stabilizing drops (ketotifen, epinastine, azelastine, olopatadine)
 - Oral antihistamines
- Follow-up: 2 weeks or sooner if worsens



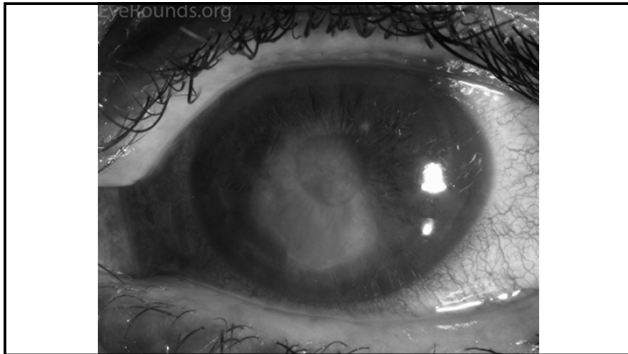Pterygium

- Symptoms: irritation, redness, decreased vision, hx of increased sunlight exposure or from equatorial region
- Signs: wing-shaped fold of fibrovascular tissue arising from interpalpebral conjunctiva and extending onto cornea
- Treatment
 - Lubrication with artificial tear drops or ointment
 - Mild topical steroid
 - Surgical removal
 - Protect eyes from sun, dust, and wind
- Follow-up: 3 months to assess for growth, sooner if affecting vision or causing persistent irritation



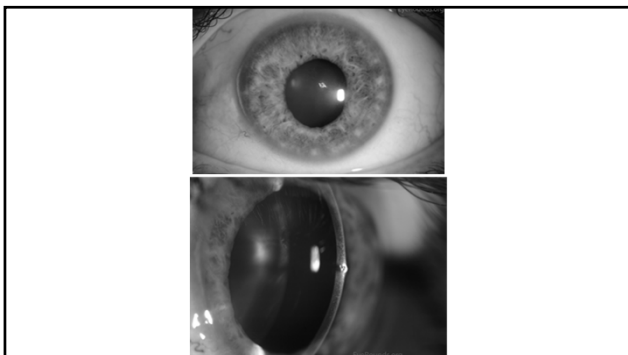
Scleritis

- Symptoms: severe pain, redness, decreased vision, recurrent episodes
- Signs: sectoral or diffuse inflammation of scleral vessels that does not blanch with phenylephrine
- Treatment
 - Systemic work-up for underlying disease (e.g. RA, GPA, lupus, PAN, HZO, syphilis, TB, sarcoid)
 - Systemic NSAIDs or steroids
 - Immunosuppressive therapy, typically in conjunction with a rheumatologist
 - Treat any underlying infectious etiology
- Follow-up: depends on severity of disease



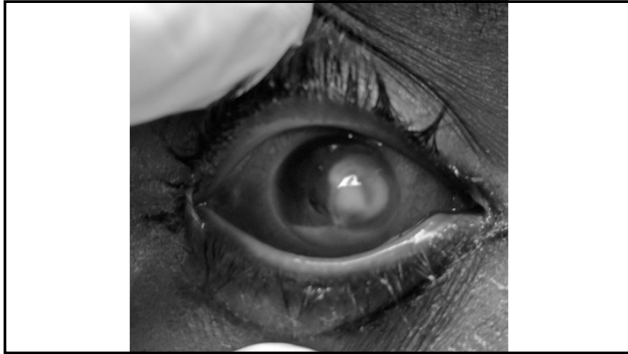
Corneal Abrasion

- Symptoms: sharp pain, photophobia, foreign body sensation, history of trauma
- Signs: epithelial defect that stains with fluorescein
- Treatment
 - Antibiotic drops or ointment (e.g. erythromycin, bacitracin, polymyxin B/trimethoprim)
 - If contact lens wearer, consider fluoroquinolone drops
 - No patching or anesthetic drops, no contact lens wear
- Follow-up: 1-5 days to ensure improvement or resolution



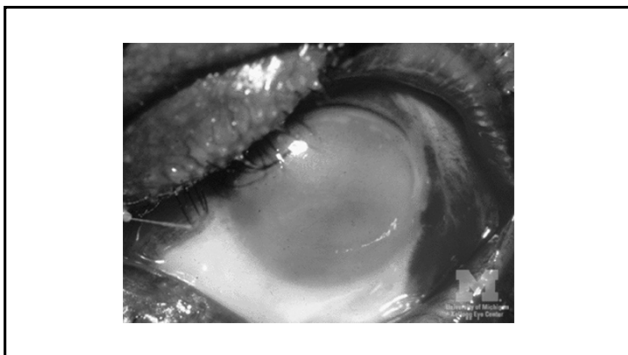
Corneal and Conjunctival Foreign Bodies

- Symptoms: foreign body sensation, tearing
- Signs: presence of foreign body, rust ring
- Treatment
 - Remove superficial foreign bodies with irrigation, cotton-tipped applicator, fine forceps, or foreign body spud
 - Treat similarly to corneal abrasion with antibiotic drops or ointment
- Refer if foreign body is not superficial or unable to remove easily



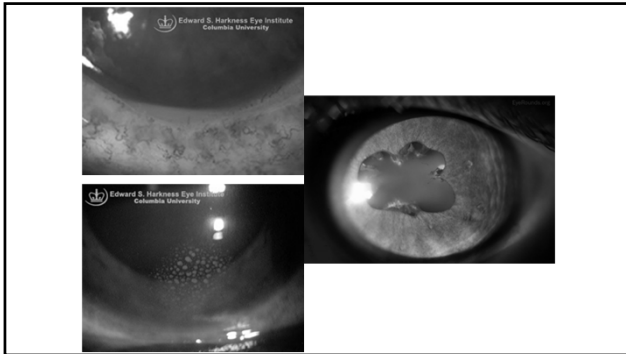
Corneal Ulcer

- Symptoms: redness, pain, photophobia, decreased vision, discharge
- Signs: white corneal infiltrate with overlying epithelial defect
- Treatment
 - Bacterial: fluoroquinolone drops (e.g. ciprofloxacin or moxifloxacin) for low risk ulcers, fortified antibiotics for higher risk ulcers
 - Cycloplegic drops
 - No patching or anesthetic drops, no contact lens wear
- Refer immediately



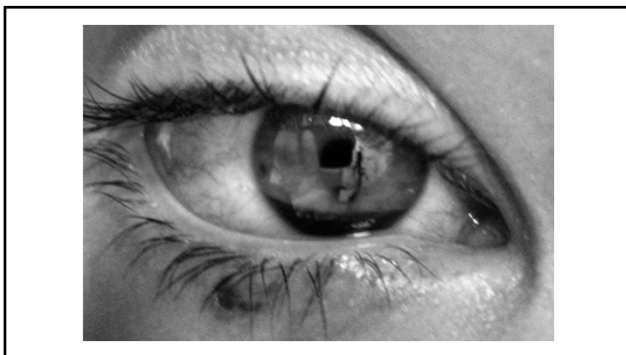Chemical Burn

- Symptoms: redness, pain, photophobia, decreased vision, history of chemical injury
- Signs: epithelial defect or corneal opacification, injection or blanching of conjunctival vessels, chemosis
- Treatment
 - Immediate copious irrigation with saline or Ringer lactate solution until neutral pH is achieved
 - Sweep conjunctival fornices, evert eyelids
 - Antibiotic ointment and cycloplegic drops
- Refer if vision is decreased



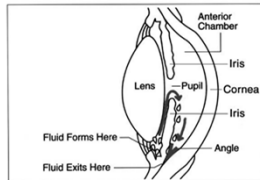
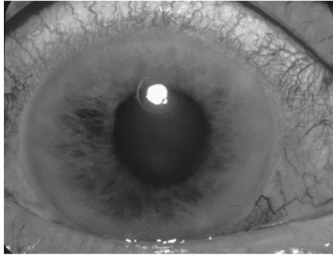
Anterior Uveitis

- Symptoms: dull throbbing pain, redness, photophobia, decrease vision
- Signs: white blood cells and flare in the anterior chamber, perilimbal injection, keratic precipitates, posterior synechiae
- Treatment
 - Cycloplegic drops
 - Steroid drops
 - Systemic work-up if recurrent or bilateral
- Follow-up: 1-7 days depending on severity



Hyphema

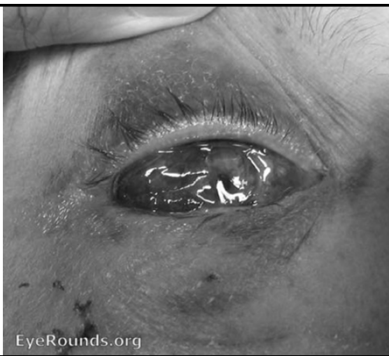- Symptoms: pain, decreased vision, history of blunt trauma
- Signs: blood in the anterior chamber
- Treatment
 - Bed rest, elevate head of bed, eye shield
 - No blood thinners
 - Cycloplegic drops
 - Steroid drops
 - IOP lowering drops as needed
- Refer immediately



Source: National Eye Institute

Acute Angle Closure Glaucoma

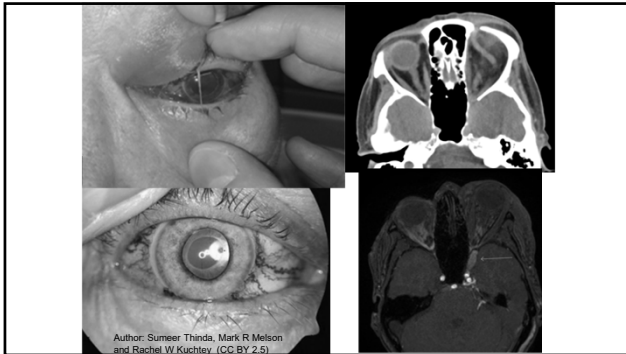
- Symptoms: pain, blurred vision with haloes around lights, headache, nausea/vomiting
- Signs: increased intraocular pressure, shallow anterior chamber, corneal edema, fixed mid-dilated pupil
- Treatment
 - Topical glaucoma medications (e.g. β -blockers, α -2 agonists)
 - Topical cholinergic agonists (e.g. pilocarpine)
 - Oral or intravenous acetazolamide
 - Dynamic gonioscopy
 - Laser peripheral iridotomy
- Refer immediately



EyeRounds.org

Corneal / Scleral Lacerations or Globe Rupture

- Symptoms: hx of trauma, pain, decreased vision, loss of fluid from the eye
- Signs: full thickness laceration, hemorrhagic chemosis, shallow or deep anterior chamber, peaked or irregular pupil
- Treatment
 - Surgical repair in the operating room
 - In the meantime: hard eye shield, NPO, pain and nausea control, IV access, systemic antibiotics, bedrest, tetanus prophylaxis
- Refer immediately



Carotid-Cavernous Fistula

- Symptoms: pain, redness, decreased vision, diplopia, tinnitus, history of trauma
- Signs: proptosis, “corkscrew” conjunctival vessels, chemosis, ocular bruit, cranial nerve palsies
- Treatment
 - Work-up with CTA or MRA
 - Neurosurgical evaluation for angiography and embolization
- Refer immediately

