



Guidelines for the Sidelines: Common Musculoskeletal Injuries in Sports

Timothy L. Miller, MD, FAAOS

Associate Professor, Department of Orthopaedic Surgery

Team Physician

Ohio State University Athletics, Capital University and Granville High School

The Ohio State University Wexner Medical Center

MedNet21


Center for Continuing Medical Education



THE OHIO STATE UNIVERSITY
WEXNER MEDICAL CENTER



The Impact of Sports Injuries



Sport is a preserver of health.

(Hippocrates)

Maintain participation and performance...

History and heritage of team physicians and Sports Medicine doctors



- 2,500 year-old tradition dating to ancient Greece
- Many techniques were developed from battle field care and applied in peacetime to the athlete.
- Herodicus, Galen, and Hippocrates
- 5th century BCE, Herodicus proposed the use of therapeutic exercise for the maintenance of health and the treatment of disease.
- Maintaining balance between strict diet, physical activity, and athletic training was the key to a good standard of health.

Knee Surg Sports Traumatol Arthrosc (2007) 15:315–318
DOI 10.1007/s00167-006-0149-z

SPORTS MEDICINE

Herodicus, the father of sports medicine

Anastasios D. Georgoulis · Irini-Sofia Klapidou ·
Lamprini Velogianni · Nicholas Stergiou ·
Arthur Boland



Whiteside et al. CJSM 2007; Georgoulis et al. KSSTA, 2007.; Snook G, AJSM, 1984.; Appelboom et al, AJSM 1988.

History and evolution of team physicians and Sports Medicine doctors



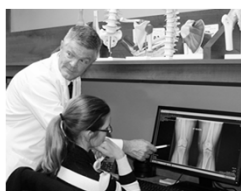Fundamental responsibility of the orthopaedic team physician:

“...To develop medical techniques that promote health and fitness while ensuring the safety and well-being of those who participate in athletic competition.”

Miller et al., CSMR, 2021.

Traditional roles and attitudes of orthopaedic team physicians

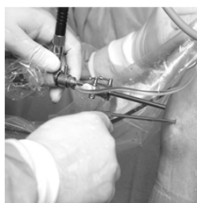Team Physician Quagmire



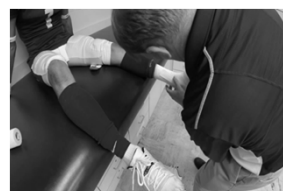Musculoskeletal specialist



THE team orthopaedist



Arthroscopist



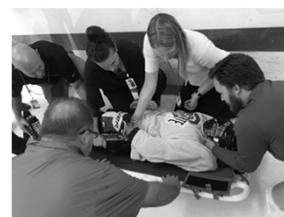Sideline Physician

Wojtys EM. Team Physician Quagmire. Sports Health. 2018.

Baggish AL, et al. Team Physician, Team Subspecialist: A Potential Scientific Conflict of Interest? MSSE, 2019.

Defining a Team Physician

- Duty to provide for the well-being of individual athletes—enabling each to realize his/her full potential.
- Possess special proficiency in the care of musculoskeletal injuries and medical conditions encountered in sports.
- Must actively integrate medical expertise with other healthcare providers and allied health professionals.
- Assumes ultimate responsibility for making medical decisions that affect the athlete's safe participation



Team Physician Consensus Statement

Team physician consensus statement. Am J Sports Med. 2000;28(3):440-441.

Qualifications of a team physician

National Athletic Trainers Association Guidelines for Appropriate Medical Coverage of Intercollegiate Athletics

- F
 - Determination of an athlete's readiness to participate (pre-participation evaluation and post-injury/illness return)
- E
 - Risk management and injury prevention
- E
 - Recognition, evaluation and immediate treatment of athletic injuries/illnesses
- C
 - Rehabilitation and reconditioning of athletic injuries
- A
 - Psychosocial intervention and referral
 - Nutritional aspects of injuries/illnesses
 - Health care administration
 - Professional development to maintain and improve knowledge and skills

competition and practice

Am J Sports Med. 2000.

NATA.org, 2021.



Guidelines for the Sidelines

- Acromioclavicular Joint Injuries
- Glenohumeral Joint Dislocations
- Patellar Dislocations
- ACL Tears



Sideline Evaluation & Management of the Acutely Dislocated Joint

Bryant J. Walrod, M.D. C. A. Q. Sports Medicine

Associate Professor - Clinical

Family and Community Medicine: Sports Medicine

Head Team Physician: Football, Ohio State Buckeyes

The Ohio State University Wexner Medical Center

AC Joint Injuries

Static stabilizers

AC ligaments

- Anteroposterior stability

CC ligaments

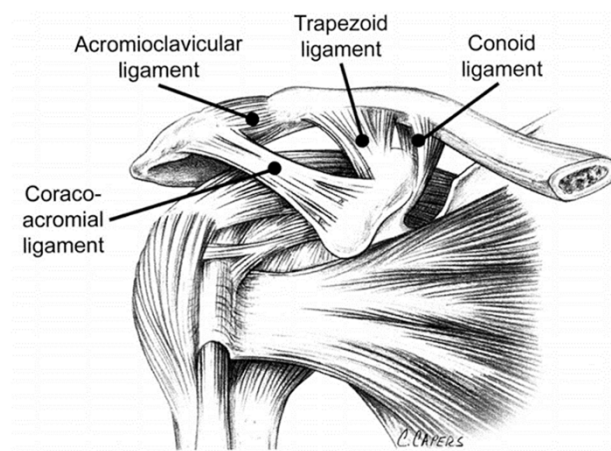
- Conoid, Trapezoid
- Superior/ Inferior stability

CA ligament

AC joint capsule

Dynamic stabilizers

- Deltoid, trapezius muscles



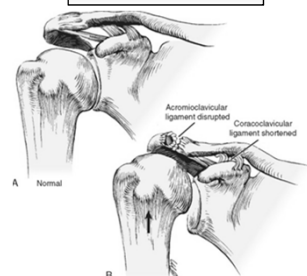
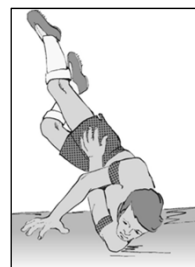AC Joint Injuries

Direct

- Fall onto lateral aspect of Shoulder
- Inferior displacement of the Scapula
- AC and CC ligament disruption

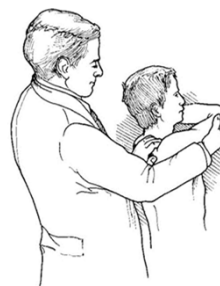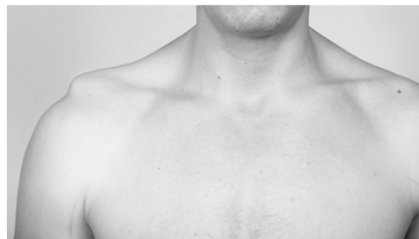
Indirect

- Fall onto elbow
- Proximal humerus driven into acromion
- Often spares the CC ligaments



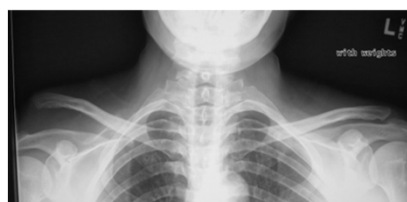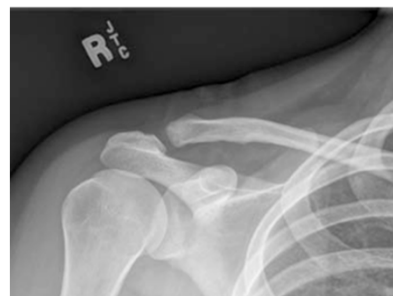AC Joint Injuries

- Inspection: Visible deformity
- Deformity reducible with proximal force on humerus
- Triad
 - 1) Direct TTP
 - 2) Pain with cross body adduction
 - 3) Relief with Lidocaine injection



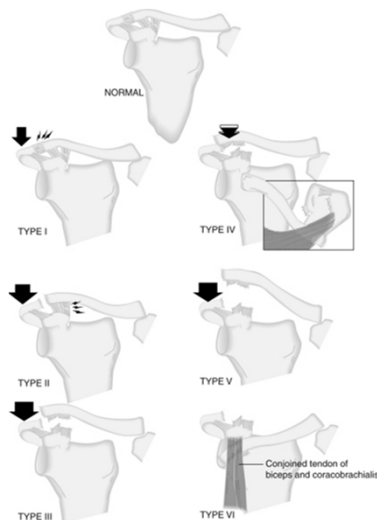
AC Joint Injuries

- Complete Shoulder Series
 - AP/ Grashey- overpenetrates AC joint.
 - Scapular Y
 - Axillary
 - A/P translation (Type IV)
- Zanca View
 - 10 deg cephalad tilt, 50% penetration
- Stress View
 - Type II vs Type III



AC Joint Injuries

- Radiographic Evaluation
- Rockwood Classification
 - Types I-VI
 - (Rockwood et al. 1984)
- Sequential Injury
 - AC ligaments
 - CC ligaments
 - Deltotrapezial Fascia



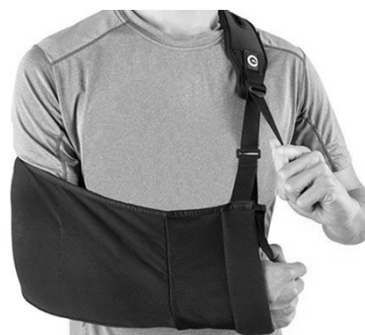AC Joint Injuries

Initial Treatment:

- Sling, ice, NSAID's, physical therapy
- Consider Lido/Corticosteroid Injection

Definitive Treatment

- Nonoperative
 - Type I-II (incomplete AC joint disruption)
 - Type III controversial
 - Surgery for elite throwing athletes.
 - Otherwise return to play in 2-6 weeks
- Operative



(Bishop et al., Sports Med Arth, 2006)



Guidelines for the Sidelines: Common Musculoskeletal Injuries in Sports

Timothy L. Miller, MD, FAAOS

*Associate Professor, Department of Orthopaedic Surgery
Team Physician*

*Ohio State University Athletics, Capital University and Granville High School
The Ohio State University Wexner Medical Center*

MedNet21
Center for Continuing Medical Education

THE OHIO STATE UNIVERSITY
WEXNER MEDICAL CENTER

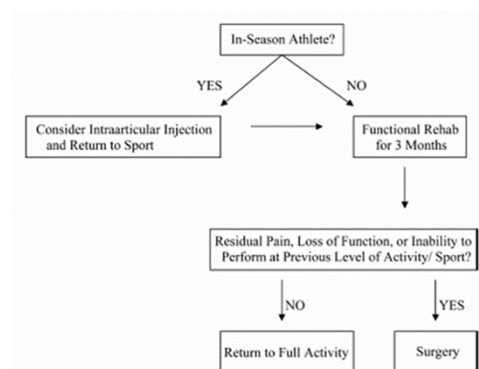
AC Joint Injuries

Surgery may be indicated for:

- Residual Instability
- Decreased Strength
- AC Joint Pain

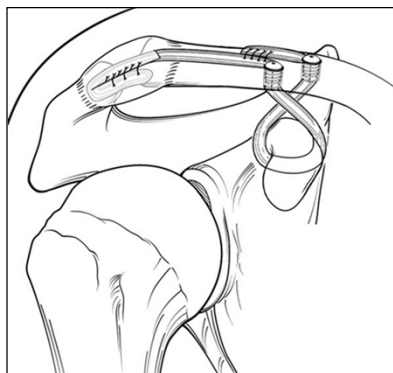
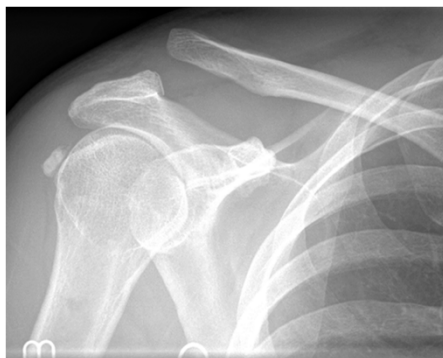Deciding Factors for Type III's

- Type of Sport
- Timing of Injury relative to athletic season
- Throwing demands
- Hand dominance



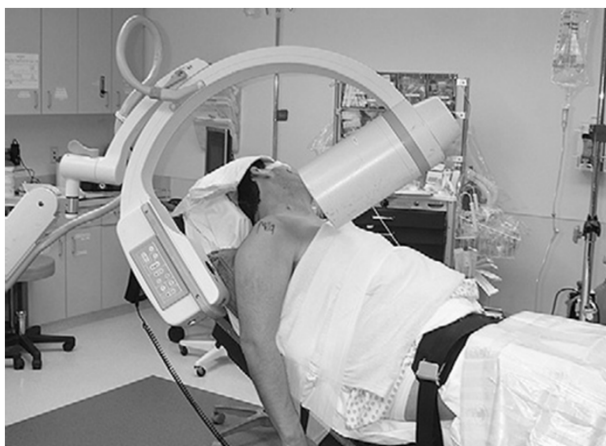Beitzel et al. Arthroscopy, 2013.

AC Joint Injuries

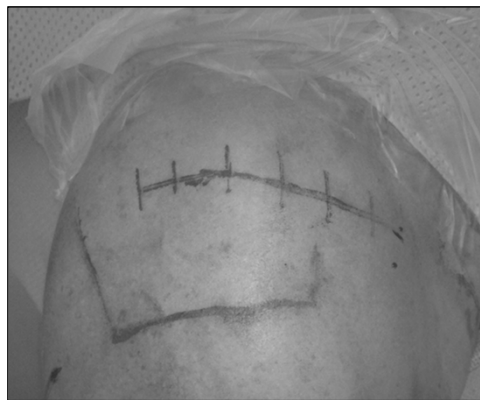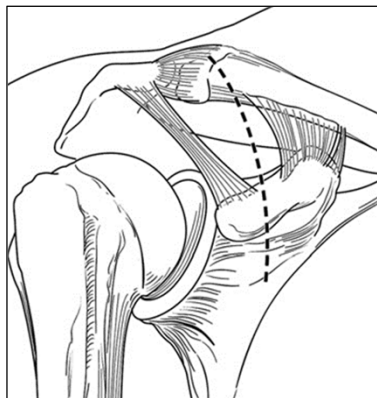


Division II collegiate quarterback with Grade III AC joint dislocation
Initially treated with PT/ rehab and injections.

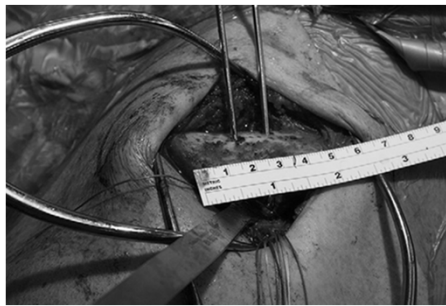
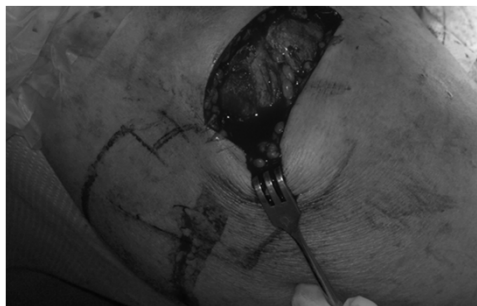AC Joint Injuries



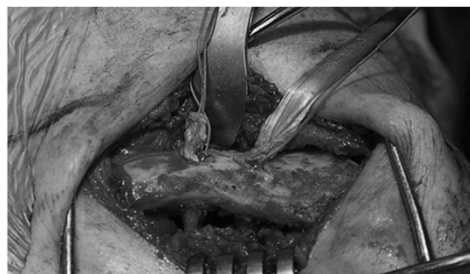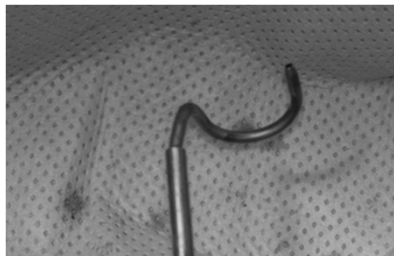
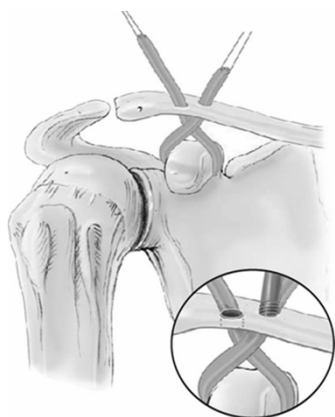
AC Joint Injuries



AC Joint Injuries



AC Joint Injuries



Sideline Evaluation & Management of the Acutely Dislocated Joint

Bryant J. Walrod, M.D. C. A. Q. Sports Medicine

Associate Professor - Clinical

Family and Community Medicine: Sports Medicine

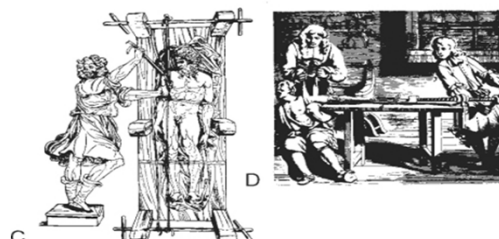
Head Team Physician: Football, Ohio State Buckeyes

The Ohio State University Wexner Medical Center

Glenohumeral Joint Dislocations



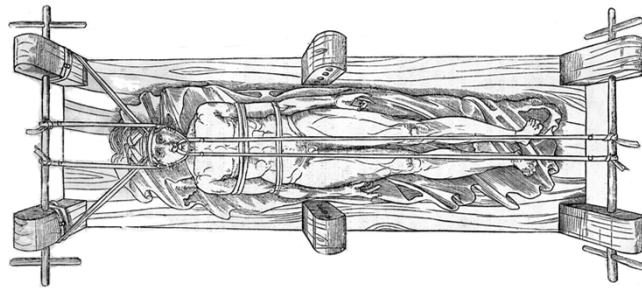
- "I have never known any physician [to] treat the case properly; some abandon the attempt altogether, and others hold opinions and practice the very reverse of what is proper."



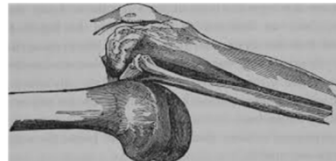- -Hippocrates
5th Century B.C.

Joint Dislocation: Goals

- **Avoid neurovascular complications**
- **Reduced the joint with as little trauma as possible**
 - “Zen of shoulder reduction”



Definitions



- **Dislocation**
 - **Complete** displacement of the bone from its normal joint position
 - May or may not need to be reduced
 - May be acute or chronic
- **Subluxation**
 - **Transient** displacement of a bone from its normal joint position
 - Does not need to be reduced
- **Separation**
 - Poor term: Consider acromioclavicular (AC) or sternoclavicular (SC) joint

Technique & Skill Considerations

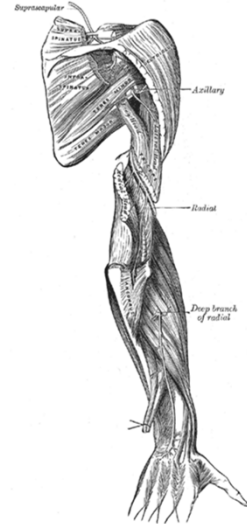
- Patient consent, or parental consent and patient assent in the case of **minors** should be obtained before any attempt at reduction
 - **Consent is often assumed**
 - Written consent **before the start of the school season**
- ATs should collaborate and consult with their supervising physicians
 - Specific criteria to be used in **determining joints for which an onsite reduction will be attempted**
- Physicians should educate ATs on the details of the selected reduction techniques
 - Determine, based upon the skill and experience of the AT, when he or she can attempt specific onsite reduction techniques

General Joint Dislocation Management Considerations

- History should be obtained
 - **Previous joint dislocations**
 - **Details of current injury**
 - Paresthesia
 - Numbness
 - Neck pain
 - **Concussion symptoms**
 - **Will need to be addressed later**
 - Other medical conditions that may affect injury management
- Comprehensive MSK assessment
 - **Include neurovascular examination**
- Reduction **should not** be undertaken if there are any signs of fracture

General Management Considerations

- Neurovascular examination
 - Sensory
 - Vascular
 - Motor
- All reduced joints should be immobilized
 - Temporary
 - Buddy tape, sling, knee immobilizer
- Refer for further treatment
 - Radiographs
- **Pediatric patients:**
 - Onsite reduction of a joint dislocation should not be attempted because a **fracture** is highly likely



Special considerations

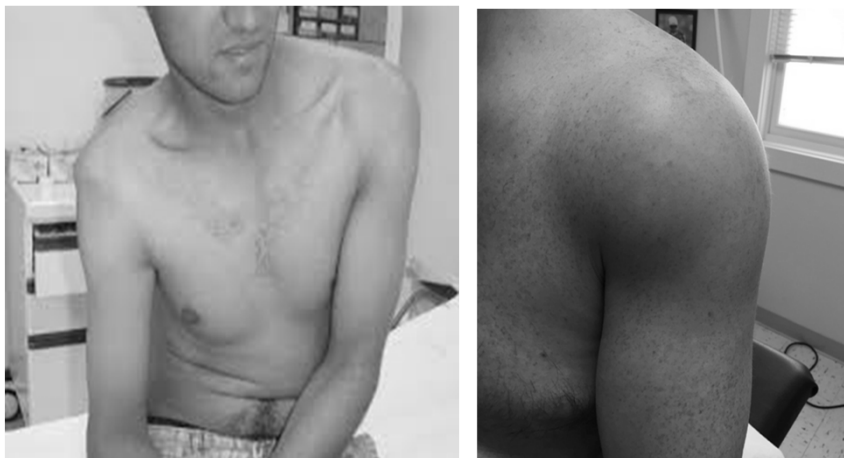- **Caution joint reductions**
 - **Diabetes (Type 1 and Type 2)**
 - Adhesive capsulitis
 - May be chronic dislocations
 - Dislocations resulting from **tonic-clonic** seizures
 - Posterior shoulder dislocation

Why reduce onsite?

- Crucial considerations
 - **Protect neurovascular structures**
 - **Reduce the joint**
- Avoid muscle spasm and contraction
- Reduces pain
- Less articular cartilage injury
- Reduce emergent need for radiographs

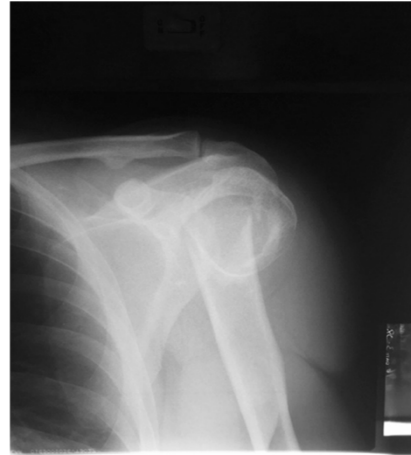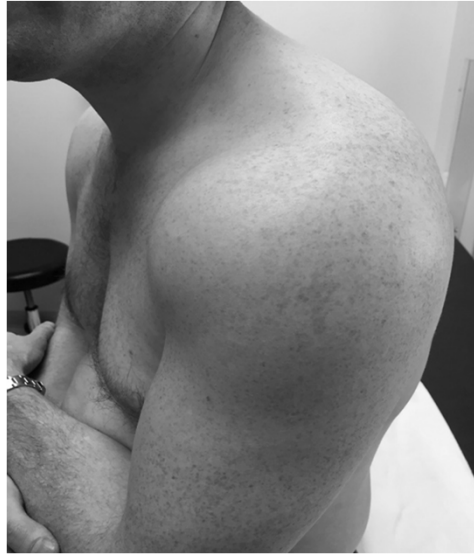- **Treatment for a dislocation with neurovascular compromise is:**
 - **REDUCTION**

Pearl



Fractures swell – dislocations do not

Fracture



Shoulder Dislocations

50% of **all** major joint dislocations

Incidence of anterior shoulder instability:

- 0.08/1000 person years
 - 0.51 football and rugby
 - 1.69 Military personal

Anterior: **95-97%**

Posterior: 2-4%

Inferior: <1% (luxatio erecta)



Epidemiology of Shoulder Dislocations Presenting to Emergency Departments in the United States

By Michael A. Zacchilli, MD, and Brett D. Owens, MD

Investigation performed at William Beaumont Army Medical Center, El Paso, Texas

Between '02-'06

- .23/1,000 person years
- 72% were in males
- Nearly 50% occur in ages 15-29 years



Injuries Associated with Traumatic Anterior Glenohumeral Dislocations

C.M. Robinson, BMedSci, FRCSEd, N. Shur, MBChB, T. Sharpe, FRACS, A. Ray, MBChB, and I.R. Murray, BMedSci, MRCSEd

Investigation performed at The Edinburgh Shoulder Clinic, Royal Infirmary of Edinburgh, Little France, Edinburgh, United Kingdom

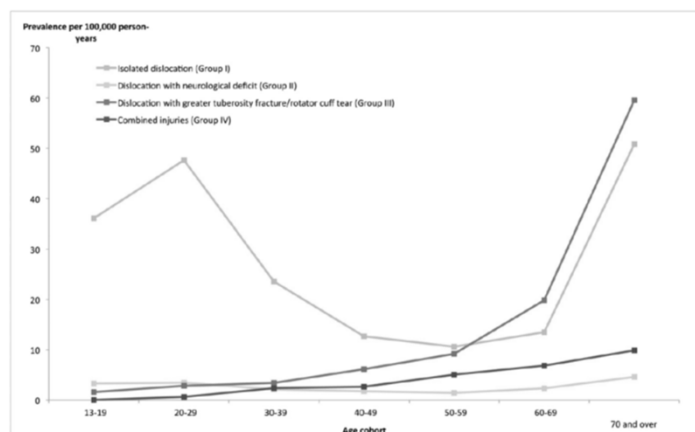



Fig. 1
Line graph showing the frequency of isolated dislocation, dislocation with neurological deficit, dislocation with greater tuberosity fracture or rotator cuff tear, and combined injuries, shown as age-defined groups.

Anatomy

Inherently unstable

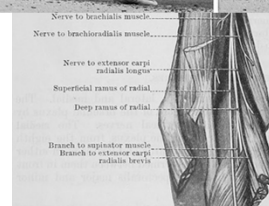
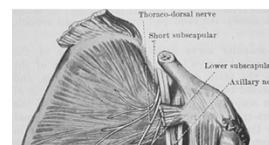


- Labrum
- Articular conformity
- Negative pressure

Dynamic stabilizers

- Rotator cuff

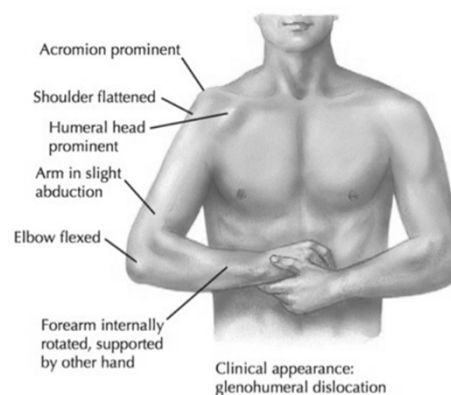
Axillary Nerve



Author: Johnmaxmena2 (CC BY-SA 4.0)

Anterior Dislocation

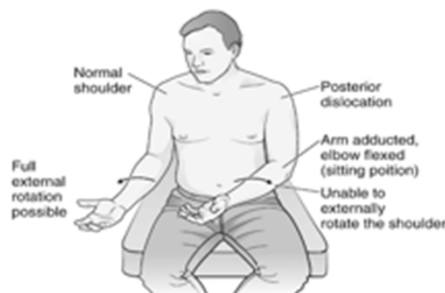- MOI: **Abduction & External Rotation**
- Feel the shoulder "Pop out of joint"
- Hold their arm in slight abduction
- Resists movement/guards
- May note a prominent humeral head in thin individuals
- Loss of normal contour of shoulder



Clinical appearance:
glenohumeral dislocation

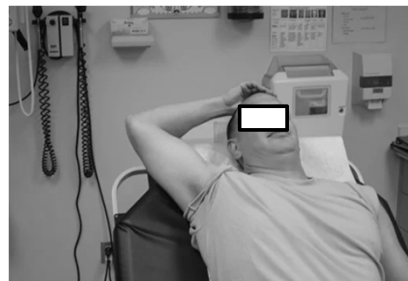Posterior Dislocation

- Axial loading to the anterior aspect of the shoulder
 - Offensive Lineman
 - Auto accident
- Violent muscle contraction:
 - 3 E's
 - Epilepsy
 - Electrocution
 - EtOH
- Arm is adducted and IR
- Does not want to allow **ER**
- Anterior shoulder is flat with prominent coracoid
- May go unrecognized



Inferior Dislocation

- MOI
 - Axial load to the arm while fully abducted
 - Forceful hyper-abduction
 - Grab an object above their head while falling
- Hold arm above their head
- Associated **neurologic dysfunction**:
 - Axillary nerve
- Associated **rotator cuff tears and greater tuberosity fractures**
- Highest rate of **vascular compromise** when compared to other directions of instability (3%)



Radiographic Imaging

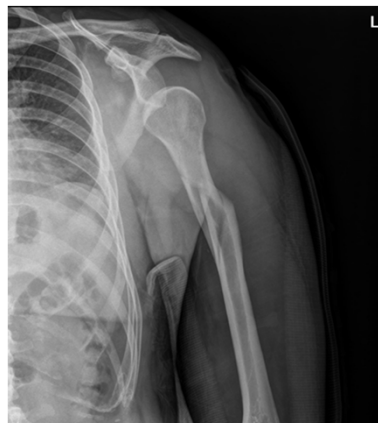Ideally obtain radiographs pre/post-reduction

- Confirm diagnosis
- Rule out associated fracture
- Iatrogenic post-reduction fracture

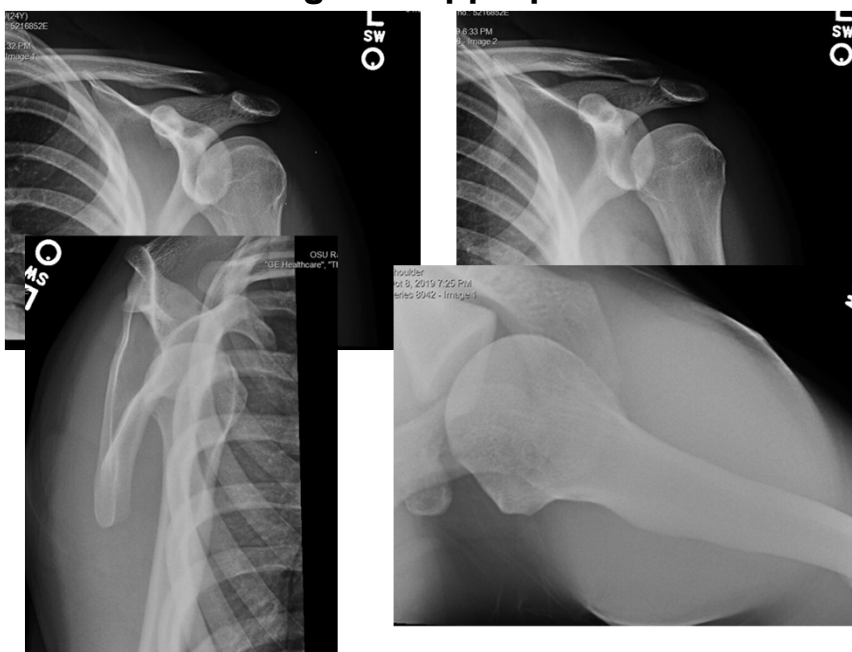
Fracture

- 25%
- Increased risk:
 - Age >40
 - First time dislocation
 - Trauma

Do not attempt to reduce if there is a fracture



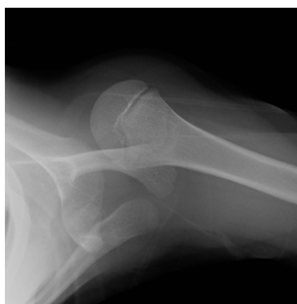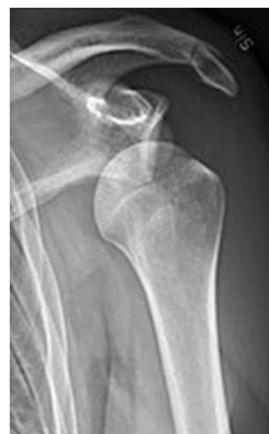Pearl - Need to get all appropriate views



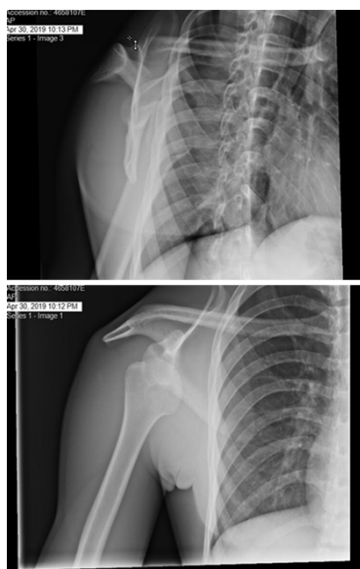Anterior Dislocation

▪ Anterior dislocation

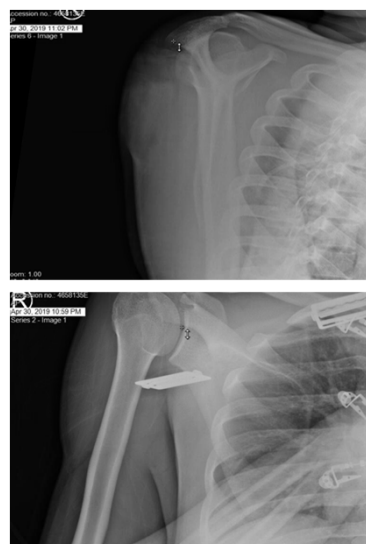
- **Axillary:** humeral head is anterior
- **Scapular view:** humeral head is anterior to the center of the Y



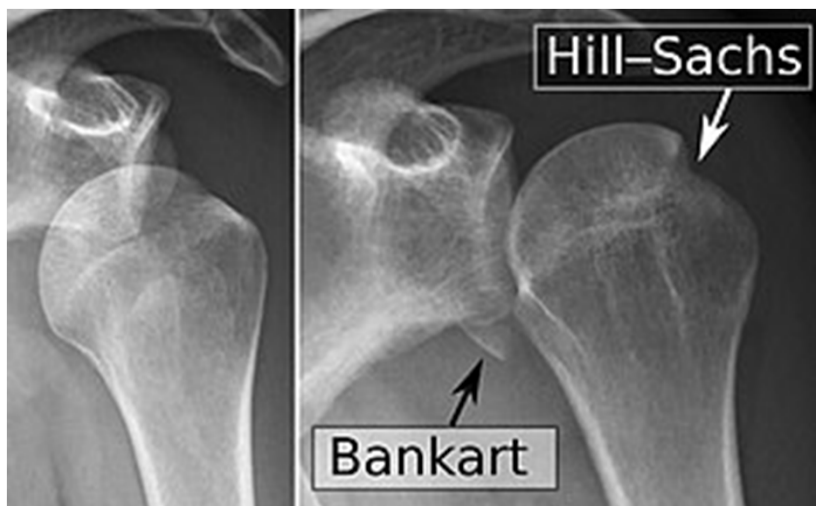
Pre-reduction



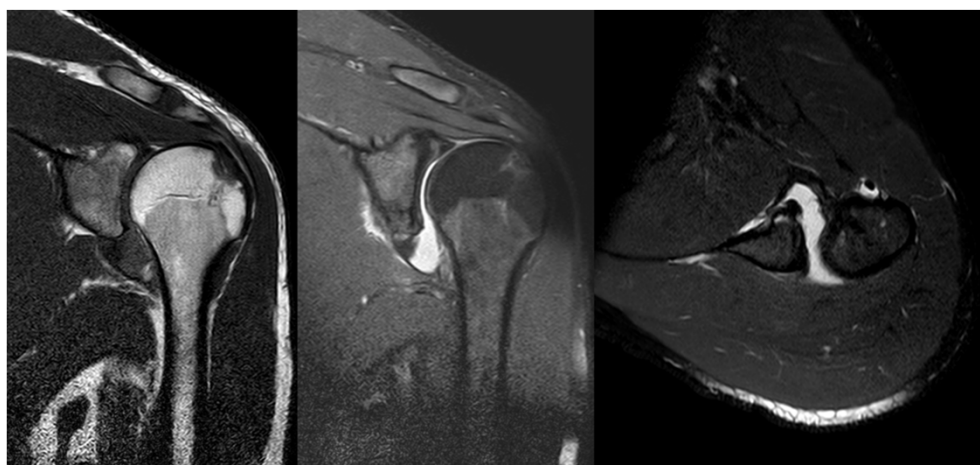
Post-reduction



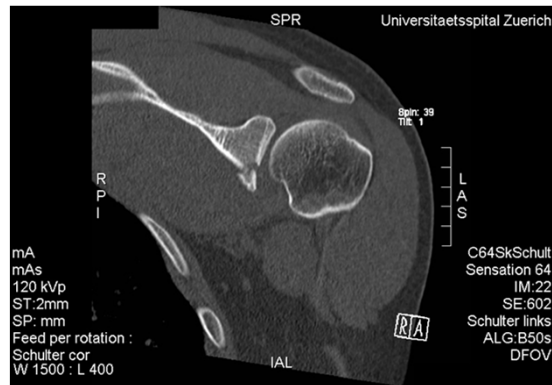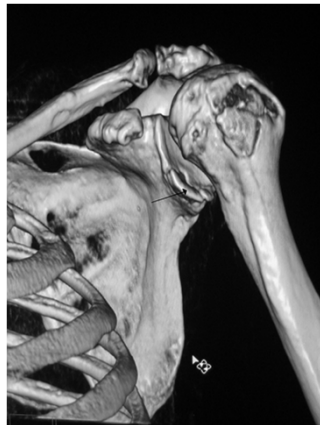Complications



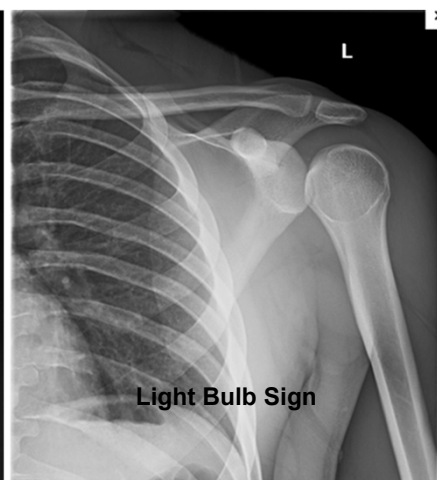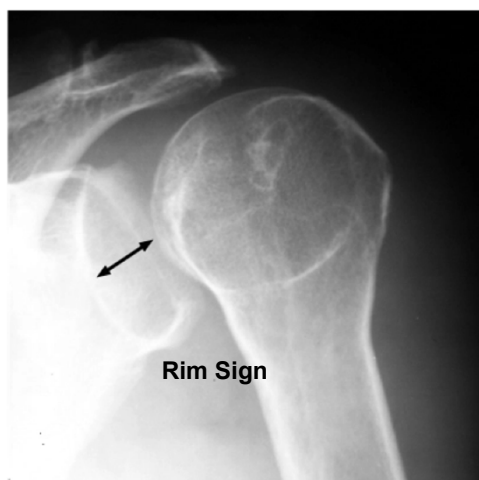Bankart & Hill-Sachs: MRI



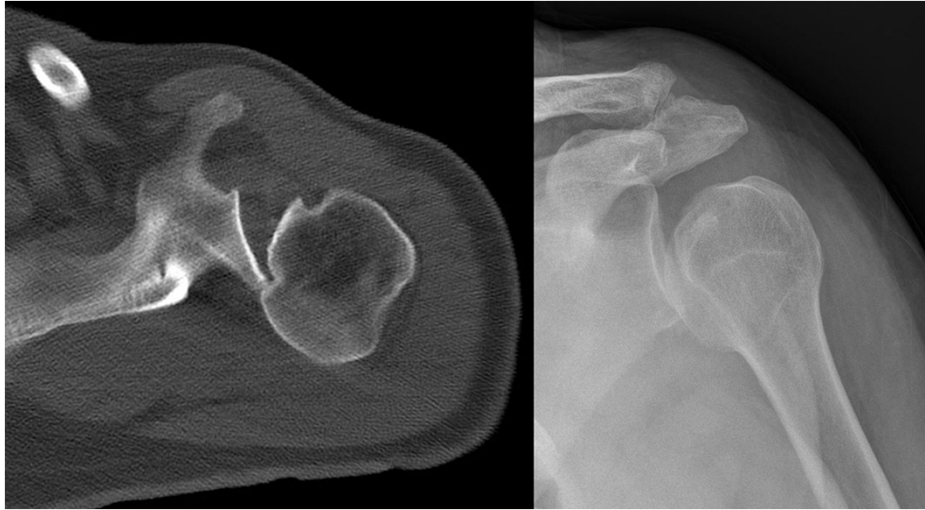Bankart & Hill-Sachs: CT



Posterior Dislocation Radiographs

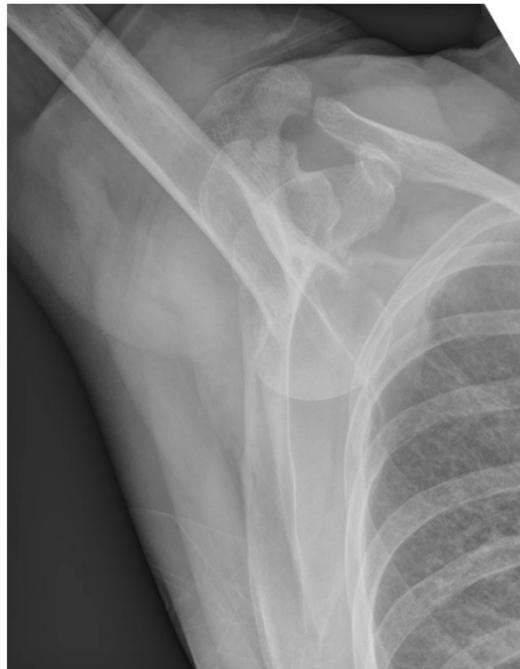

Reverse Hill-Sachs



Inferior Dislocation

Humeral head is
below the coracoid



Anesthesia/sedation

- **Consider intra articular lidocaine (20 ml 1%) pre-reduction over procedural sedation**
 - Consider US guidance
 - Equal rates of successful reduction
 - Shorter time to discharge from ED
 - No need for IV
 - Less expensive, less staff needed
- **Procedural anesthesia**
 - ED, Ortho
 - Fentanyl, Midazolam, Ketamine, Etomidate, Propofol

Results

	Succ ess Rate	Complicat ion Rate	Pain	Time to Reducti on	Time in ED
IV sedation	92%	16.4%	NS for all studies	2 of 3 studies in favor of IV sedation	3 of 3 in favor of intra- articular lidocaine, 2 reached significance
Intra- articular lidocaine	92%	0.9%			

Fitch & Kuhn Acad Emerg Med 2008

Anterior Reduction Techniques: 21 options

Scapular manipulation

Stimson

External Rotation

Milch

Sitting

Axial traction

Traction/counter traction

Fares

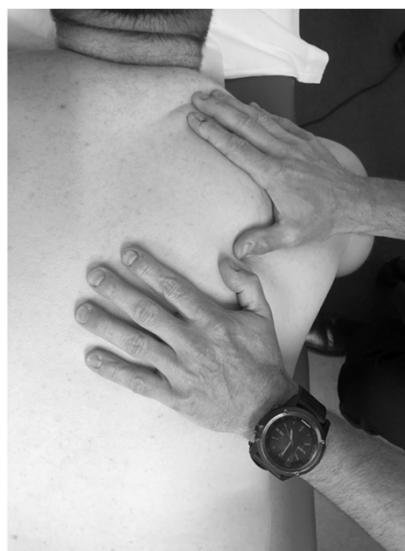Chair

Elbow



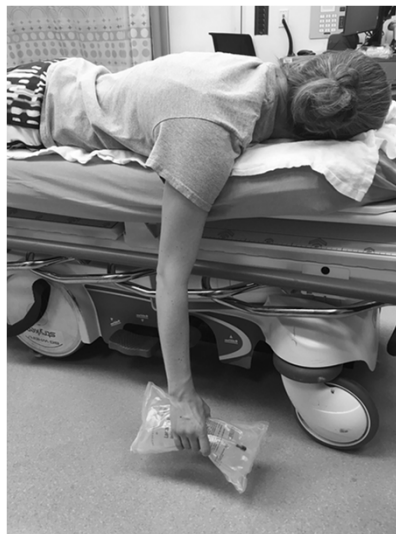Scapular Manipulation

- Upright or Prone
 - Affected arm is placed at 90° of forward flexion
 - Slight traction is applied
 - From a posterior approach place both hands around the scapular with the thumbs in an inferior lateral position
 - Rotate the inferior tip of the scapula medially and the superior aspect laterally to rotate the scapula
 - Have an assistant continue with gentle downward traction with slight external rotation of the humerus and elbow flexion to 90°
 - May be difficult in obese patients



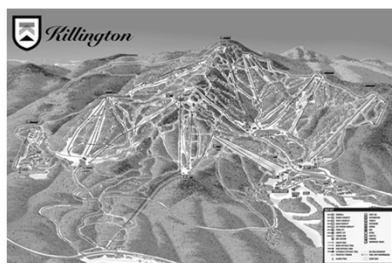
Stimson

- Prone on training table
- Affected arm hangs off of the stretcher in 90° of forward flexion
 - Relaxes biceps tendon
- Attach at 10 – 15# weight to the affected hand for counter traction
- Shoulder will usually reduce with in 20 -30 minutes



My Preferred Technique

Matt Gammons, M.D., James Russell, M.D.



Jim Russell, MD, is certified by the American College of Emergency Physicians and holds a certificate in Added Qualifications in Sports Medicine from the same organization.

A long-time Vermonter, Dr. Russell received his B.A. from the University of Vermont and his M.D. from the Medical College of Vermont. He completed his surgical residency at the Medical Center Hospital of Vermont and also in Emergency Medicine at the Institute of Emergency Medicine and Trauma in Milwaukee, Wisconsin. He was also an assistant coach for the U.S. Olympic Sailing Team from 1984 through 1988.

Dr. Russell has been associated with Killington Medical Clinic since 1986 and Vermont Orthopaedic Clinic since 1997.



Matthew Gammons, MD, is Medical Director of Killington Medical Clinic, iSPORT Training program of Vermont Orthopaedic Clinic, and Performance Improvement, a department of Rutland Regional Medical Center. He also serves as the Medical Director of Castleton University's Athletic Training Education and Athletic Programs. He is board-certified in family practice and sports medicine. His specialty is in non-operative musculoskeletal care.

He received a BS in Biomedical/Mechanical Engineering from the University of Vermont and then was awarded his MD at Ross University School of Medicine in Portsmouth, Dominica. He served his residency in family practice at Saginaw Cooperative Hospitals in Michigan. He also completed a fellowship in primary care sports medicine at the Medical College of Wisconsin in Milwaukee.

Dr. Gammons has been on staff at the Killington Medical Clinic and the VOC since 2004. Previously, he served as the Assistant Residency Director and the Director for Sports Medicine at St. Michael Family Practice Residency in Milwaukee.

In addition to having authored numerous sports medicine-related articles, papers and presentations, Dr. Gammons has been the recipient of several professional honors, including the Harry Galanty Young Investigators Award for Outstanding Research from the American Medical Society for Sports Medicine.

He also enjoys several sports team affiliations, including serving as team physician for the U.S. Ski and Snowboard teams.

Start with mild humeral traction & then add scapular manipulation

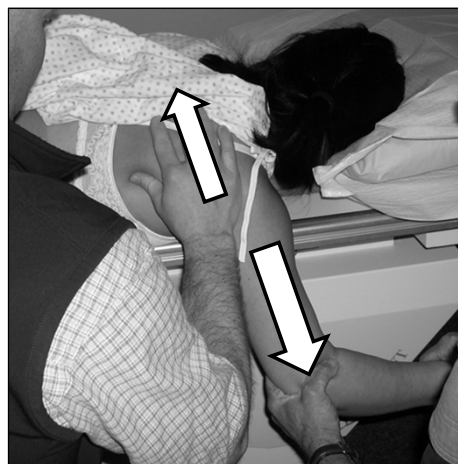

Pull down to disengage the locking mechanism (window shade)

Try to avoid letting the humeral head “clunk” in.

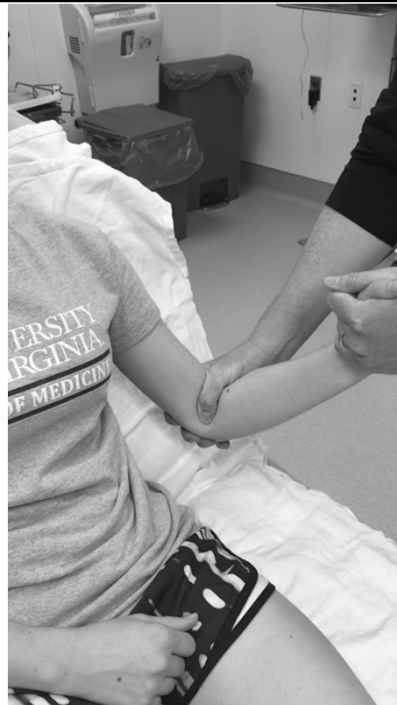If humeral head is hung upon glenoid the scapula moves with humeral traction and external rotation is blocked

- Apply increased traction and/or increase medial rotation of the scapula
- Consider forward flexion of the arm



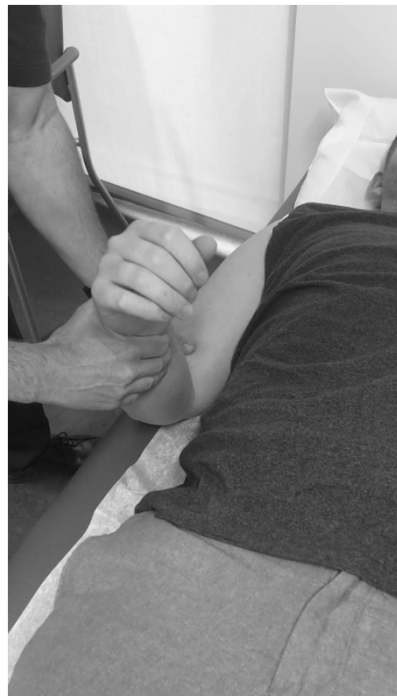Milch (75-95%)

- Apply gentle longitudinal traction in line with the humerus while maintaining external rotation
- Gentle abduction
- Stop if you feel resistance and then continue when patient relaxes



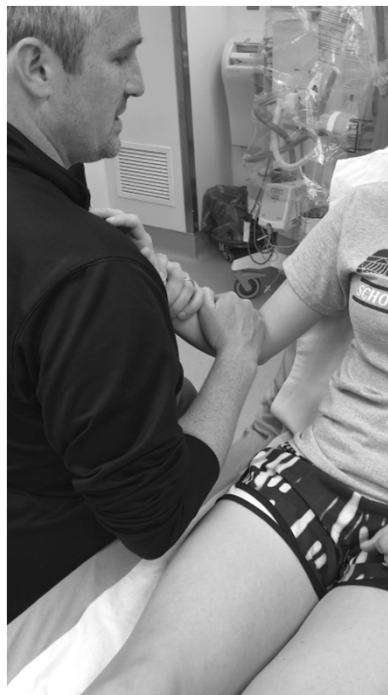External Rotation

- Supine on a stretcher
- Adduct affected arm and flex the elbow to 90°
- Consider forward flexing the shoulder to 20°
- Slowly and gently externally rotate the shoulder using the forearm as a lever
- Reduction typically occurs at 70 - 110° of ER
- **No traction is applied**



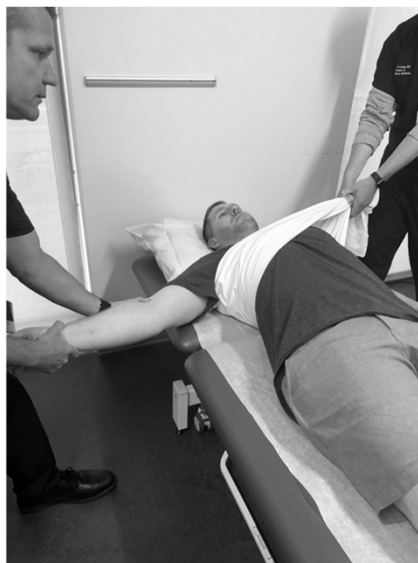Cunningham (sitting) Method

- Patient is seated facing the practitioner
- Hold the forearm and flex the shoulder to 90° with slight elbow flexion
- Place other arm on anterior chest wall to stabilize the shoulder
- Apply gentle longitudinal traction
- Consider IR or ER to assist with reduction



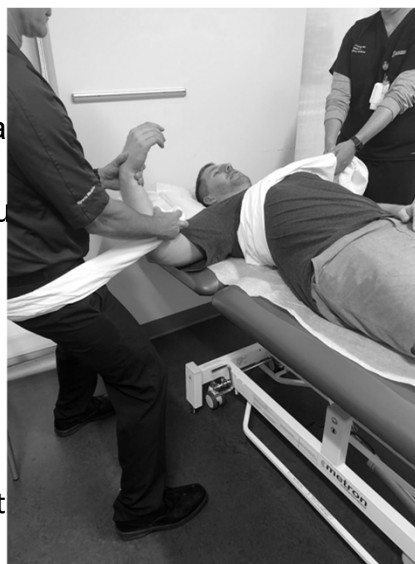Axial (Inline) Traction

- Supine with wheel locked cart
- Operator on affected side at patient's head
- Apply axial traction in line with the abducted arm
- Assistant can apply parallel counter traction by using a sheet wrapped diagonally around the affected shoulder




Traction/Countertraction: Matsen

- Two-person reduction technique
- Supine on a firmly locked stretcher
- Elevate bed to position of operators' ischia tuberosities
- Place a sheet over patient's upper chest, under the axilla of the affected shoulder and underneath the back
- Elbow in 90° of flexion
- Shoulder abducted to 90°
- Apply gentle traction: pull the flexed forearm towards you
 - Lean back pulling along the axis of dislocation
 - **Do not pull with your upper arm muscles**
- **Continuous gentle traction** is superior to forceful yanking



Chair Technique

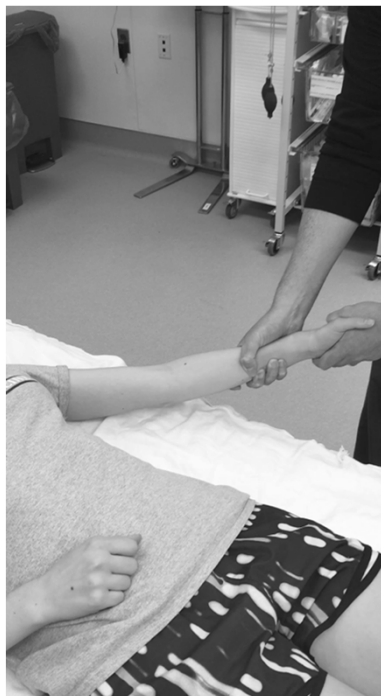- Patients are seated in a chair with a backrest as the fulcrum in the axilla
- A folded towel is placed for padding and to mirror the axillary nerve
- Hang dislocated arm () of the chair
- Elbow is flexed to 90°
- Provide gentle inferior



2012: Mahirogullari

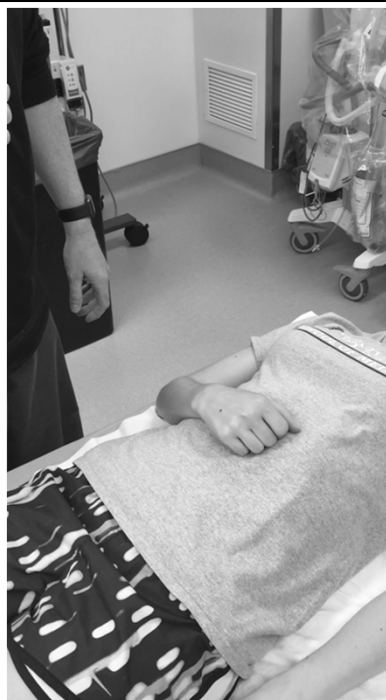Fares (FAST RELIABLE Safe)

- Patient supine
- Grasp the wrist of the patient
- Maintain the elbow in extension and the forearm in neutral
- Slowly abduct the arm in an oscillating movement
 - 5cm up and down
- Continuous application of longitudinal traction
- When arm is abducted past 90°, then begin ER
- Reduction typically occurs at 120°



Elbow Technique

- Supine position
- Hold patient's wrist with outer hand and apply gentle traction to keep the elbow straight
- Affected arm is then lifted to 45° of forward flexion and abduction
- Operator pushes the lateral surface of their elbow into the medial aspect of the patient's humerus



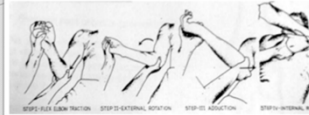Lo et al, 2/2019. J. of Emergency Medicine

Older techniques: not recommended

Kocher

- Adduct arm with elbow bent to 90°, ER to 70-85° until resistance is felt and then lift arm in sagittal plane and internally rotate
- High incidence of complications
 - Axillary nerve injury
 - Humeral neck and shaft fractures
 - Capsular damage

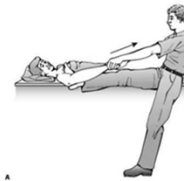Kocher's Technique



Hippocratic

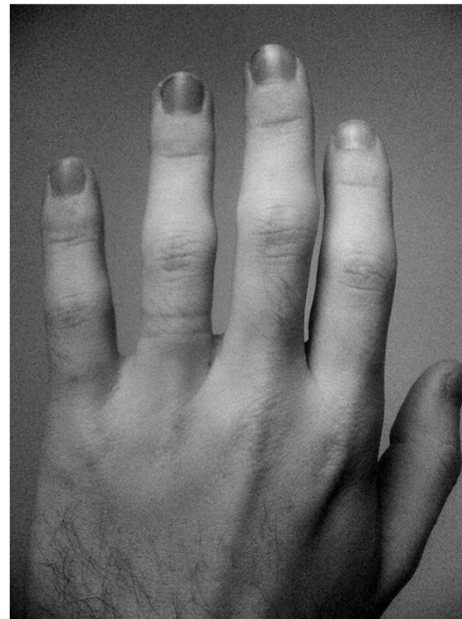
- High incidence of complications
- Place foot in padded axilla and apply counter traction

Hippocrates Method



Pearl

- Remove jewelry distal to the dislocation
- Fingers can swell after elbow and shoulder dislocations





Guidelines for the Sidelines: Common Musculoskeletal Injuries in Sports

Timothy L. Miller, MD, FAAOS

Associate Professor, Department of Orthopaedic Surgery

Team Physician

Ohio State University Athletics, Capital University and Granville High School

The Ohio State University Wexner Medical Center

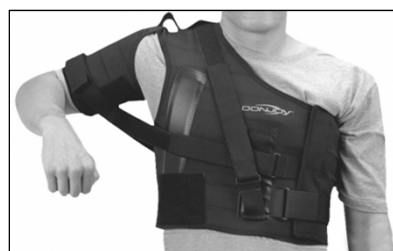MedNet21

Center for Continuing Medical Education

THE OHIO STATE UNIVERSITY
WEXNER MEDICAL CENTER

Glenohumeral Joint Dislocations

- Return to Play
 - Sport
 - Position
 - Bracing
 - Risk Factors
- Surgery vs Rehab
- Timing of Surgery
- Type of Procedure



Owens et al., JAAOS, 2012.

Dickens et al, AJSM, 2014.

Glenohumeral Joint Dislocations

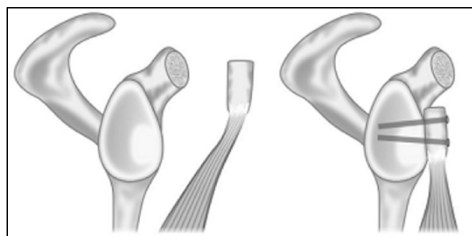
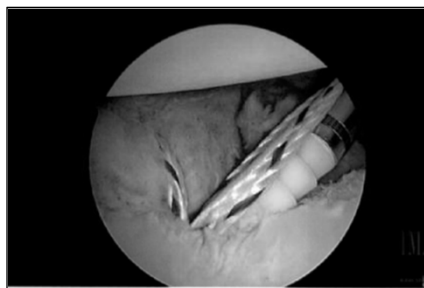- Bankart Repair/
Capsulorrhaphy

-Arthroscopic
-Open

- Latarjet Procedure

Brophy RH Clin Sports Med, 2013.

Owens et al. OJSM, 2015.



Shoulder Injuries in Athletes

- Shoulder injuries are extremely common in contact sports.
(Football, wrestling, hockey, and lacrosse)
- AC sprains can be very painful but rarely require surgery.
- Type III AC injuries may require surgery in a throwing athlete's dominant shoulder.
- Closed reduction of a glenohumeral dislocation can be performed prior to obtaining radiographs.
- Always get post-reduction radiographs including an axillary view or equivalent. (Velpau view or CT scan)
- Athletes can return to play in the same season following glenohumeral dislocation or AC joint sprain.



Sideline Evaluation & Management of the Acutely Dislocated Joint

Bryant J. Walrod, M.D. C. A. Q. Sports Medicine

Associate Professor - Clinical

Family and Community Medicine: Sports Medicine

Head Team Physician: Football, Ohio State Buckeyes

The Ohio State University Wexner Medical Center

MedNet21
Center for Continuing Medical Education

THE OHIO STATE UNIVERSITY
WEXNER MEDICAL CENTER

Guidelines for the Sidelines

- Patellar Dislocations
- ACL Tears
 - Risk Factors
 - On-field Evaluation
 - Sideline Treatment
 - Imaging workup
 - Surgery vs Nonop Treatment
 - Innovations in ACL Reconstruction



Background

2 - 3% of knee injuries

Women > men

Re-dislocation rates
up to 40%

Non-contact twisting
injury
Direct blow to medial
knee



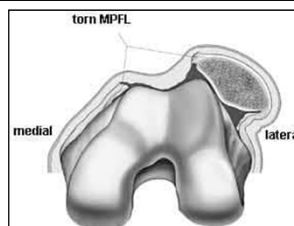
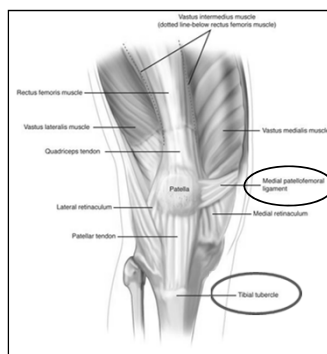
Patellar Dislocations

Bone:

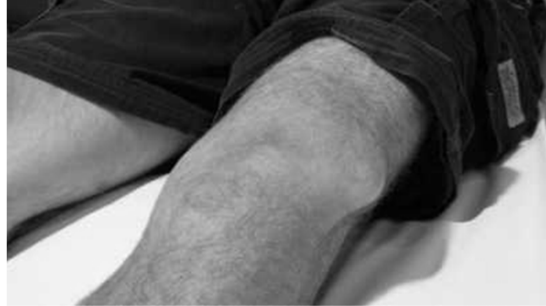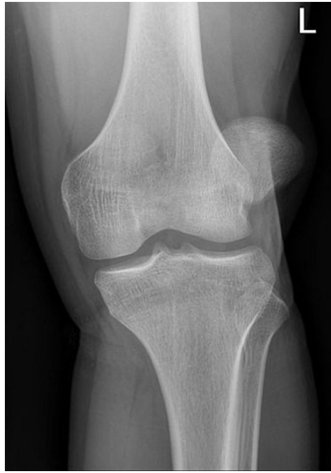- Patella Height
- Depth of the Trochlea
- Tibial Tubercle Position

Soft tissues:

- Medial Patellofemoral Ligament (MPFL)
- Lateral Patellar Retinaculum
- Oliveira V et al. Medial patellofemoral ligament anatomy: Is it a predisposing factor for lateral patellar dislocation? *Int Orthop.* 2014.

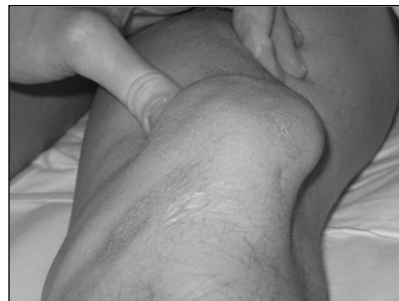

Patellar Dislocations



Patellar Dislocations- Risk Factors

- Generalized Ligamentous Laxity
- Trochlear dysplasia
- Patella alta
- Previous traumatic dislocation
- Early age at 1st subluxation
- Lateral Tibial Tubercle (TT/TG Index >20mm)
- Excessive valgus alignment
- Decrease quadriceps function



Redziniak et al., JBJS 2009.

Dislocation

- **Traumatic**

Medial force

- **Atraumatic**

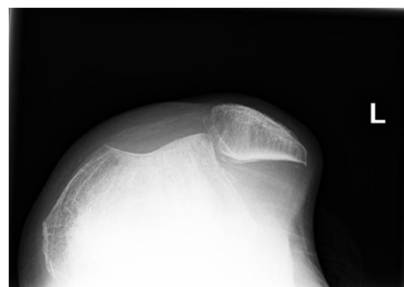
External tibial rotation

+

Internal femoral rotation

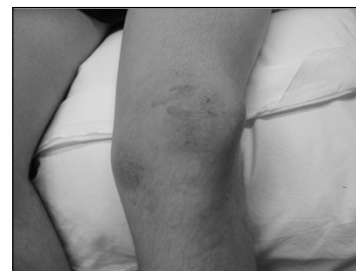- **Lateral direction**

- Mechanical axis is lateral



Patellar Dislocations

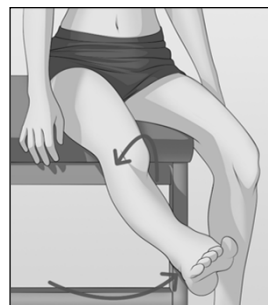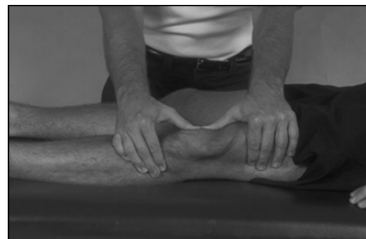- Acute anterior/ medial knee pain and swelling.
- Feeling of a pop or shift at the patella.
- Lateral patella deformity.
- “My knee (cap) dislocated.”
- May self-reduce.
- Difficulty extending knee.
- Difficulty bearing weight.
- History of prior patella instability episodes.



Diduch, D. Lateral Patellar Instability in the Skeletally Mature Patient: Evaluation and Surgical Management. JAAOS, 2018.

Patellar Dislocations

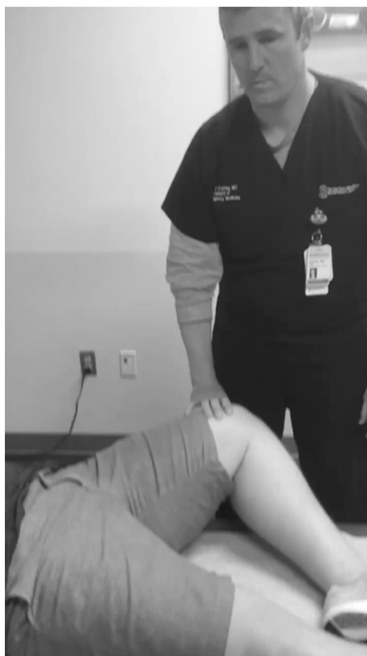- Deformity
- Neurovascular exam
- Able to bear weight?
- Swelling/ hemarthrosis
(May develop over hours.)
- Medial sided tenderness
- Patellar apprehension
- Increased lateral patellar translation.
- Confirm cruciate and collateral ligaments are stable.
- Confirm extensor mechanism is intact.



Zimmerer A, Recent developments in evaluation and treatment of lateral patellar instability. *J Exp Orthop*. 2018

Work up

- Plain film radiographs
 - AP, PA
 - **Sunrise and lateral**
- MRI after follow up



Patellar Dislocations

RICE it!

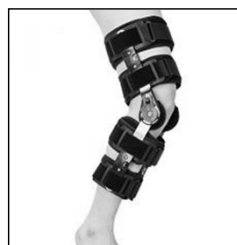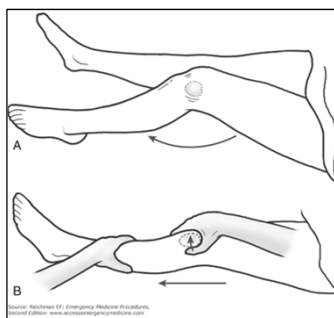
**Reduction, Remove from play,
and Rest**

Ice, Immobilize with brace

**Compression Wrap,
Crutches, and Consider
Aspiration**

Elevate, ED for xrays

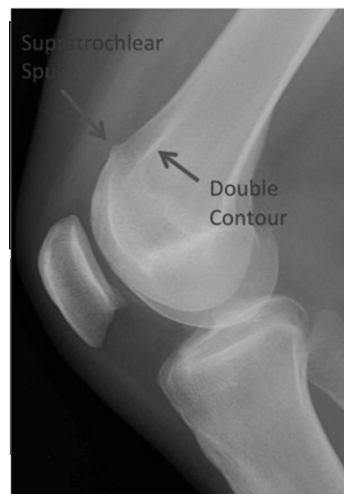Chun-Hao T et al. Primary traumatic patellar
dislocation. *J Orthop Surg Res.* 2012.



Patellar Dislocations

Radiographs:

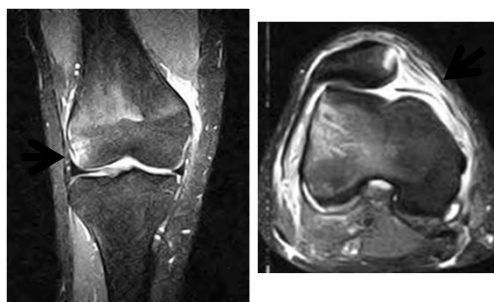
- Direction of dislocation
- Rule out fracture or loose body
- Evaluate overall lower extremity alignment
- Trochlear dysplasia
- Supratrochlear spur
- Patella height



Patellar Dislocations

MRI Scan:

- Bone bruises at medial patella and lateral femoral condyle
- MPFL tear
- Cartilage injuries
- Loose fragments

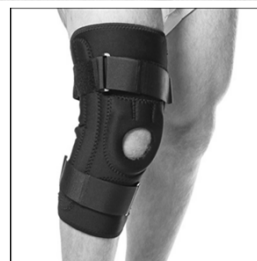

Diduch, D et al. Lateral Patellar Instability in the Skeletally Mature Patient: Evaluation and Surgical Management. JAAOS, 2018.

Patellar Dislocations

Non-Operative Treatment

- 1st line treatment
- Physical Therapy
 - Quad/ VMO Strengthening
- IT Band and Lateral retinaculum stretching
- Patellar Stabilization bracing
- Patellofemoral taping



50% recurrence rate

- Most significant risk factor is previous instability episode.

Redler, Lauren H. et al. Surgical Management of Patellofemoral Instability in the Skeletally Immature Patient. JAAOS, 2014.



Guidelines for the Sidelines: Common Musculoskeletal Injuries in Sports

Timothy L. Miller, MD, FAAOS

*Associate Professor, Department of Orthopaedic Surgery
Team Physician*

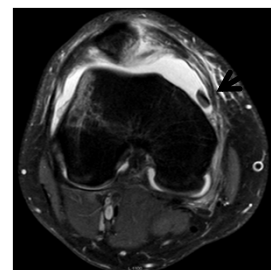
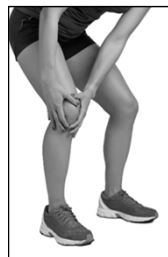*Ohio State University Athletics, Capital University and Granville High School
The Ohio State University Wexner Medical Center*

MedNet21
Center for Continuing Medical Education

THE OHIO STATE UNIVERSITY
WEXNER MEDICAL CENTER

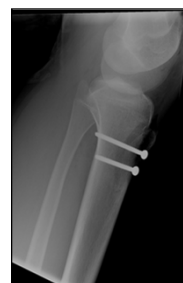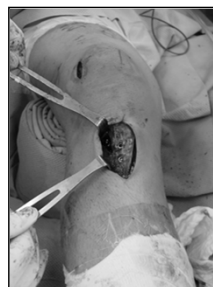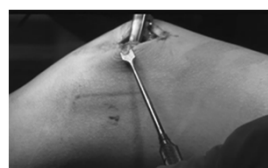
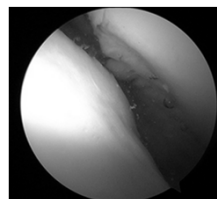
Patellar Dislocations

- Failed non-operative treatment
 - Recurrent patellofemoral instability
 - Incompetent medial checkrein ligaments (MPFL)
 - Osteochondral fragments
 - Inadequate bony constraint
- Sanchis-Alfonso, V. Guidelines for Medial Patellofemoral Ligament Reconstruction in Chronic Lateral Patellar Instability, *JAAOS*, 2014.
 - Mackay N et al *Orthop J Sports Med.* 2014



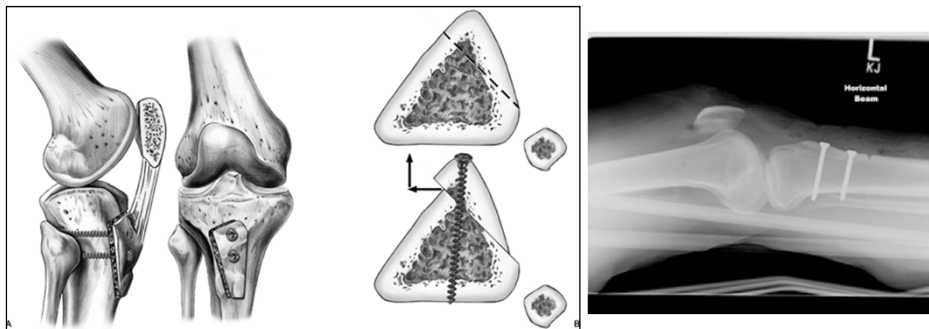
Patellar Dislocations

- Primary Medial Retinacular Repair
- MPFL Reconstruction (Auto or Allograft)
- Distal Realignment/ Tibial Tubercle Osteotomy



Smith TO, et al. KSSTA, 2007
Steiner, T. et. al, 2006, AJSM.

Tibial Tubercle Osteotomy



- Described by Fulkerson, Elmslie-Trillat
- Tubercle is shifted medially and anteriorly +/- distalization.
- Obliquity of cut determined by pathology being treated.
- Fixed using 4.5 mm cortical screws with lag technique

Enea D et al. Distalization and Medialization of Tibial Tuberosity for the Treatment of Potential Patellar Instability with Patella Alta. *Joints*. 2018.

Patellar Dislocations

- Acute 1st time dislocation
 - Unlikely to return to play same day.
- Recurrent instability
 - Possible if braced and pain allows.
- Knee must be fully rehabilitated with physical therapy and bracing.
 - Full ROM
 - Near full quadriceps strength
- Surgery is commonly required for recurrent instability and for loose fragments.
- Time to return to sports after surgery
 - 3-6 months.

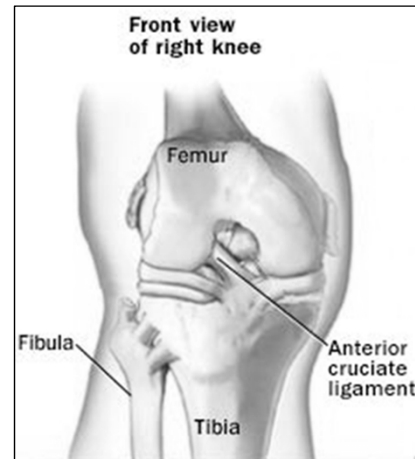


- Sanchis-Alfonso, V. Guidelines for Medial Patellofemoral Ligament Reconstruction in Chronic Lateral Patellar Instability, *JAAOS*, 2014.

ACL Tears

The ACL takes origin on the lateral wall of the femoral notch and inserts onto the central, anterior portion of the tibial plateau

Two functional bundles – anteromedial (AM) and posterolateral (PL) have been described



ACL Tears

The primary function:

Prevent anterior translation of the tibia relative to the femur

Secondary functions include:

Prevention of knee hyperextension

Resisting varus/valgus angulation

- Particularly if the collaterals are injured

Resisting internal tibial rotation relative to the femur near extension

ACL Tears

- The ACL is the most commonly reconstructed knee ligament – up to 250,000 per year in the US as of 2012
- Females are more commonly affected
2-8 x risk of males
- Those involved in cutting and pivoting sports are at highest risk

ACL Tears

- Noncontact, deceleration/ cutting move
- Feeling and/ or hearing a “Pop”
- Unable to continue playing or bear weight
- Immediate swelling



ACL Tears

History of knee problems pre-injury?

Injury

Mechanism – Contact?

Pop?

Swelling – Immediate? How large?

Acute hemarthrosis in otherwise healthy knee – think ACL!

Post-injury

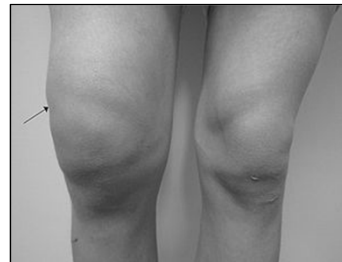Mechanical symptoms – locking, catching?

Feelings of instability?

ACL Tears

Complete lower extremity exam

- Strength, ROM, neurovascular, gait
- Beware of patella dislocation, can have similar clinical presentation

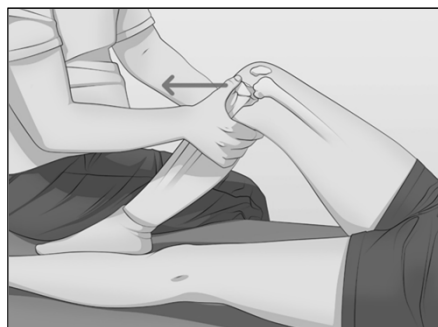


Ligamentous Exam

- ACL-Specific tests
- PCL, MCL, LCL, PLC

ACL Tears

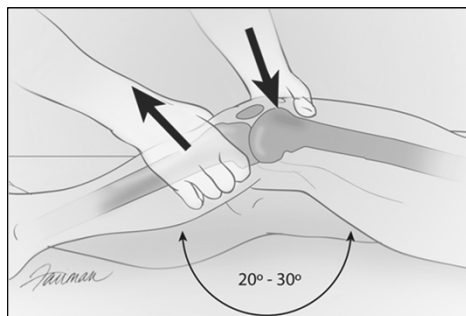
- Knee flexed 90 degrees
- Pull forward on the proximal tibia
- Always compare to uninjured knee.
- Not as sensitive as Lachman test
- Much more useful for posterior instability (PCL injury)



Anterior Drawer Test

ACL Tears

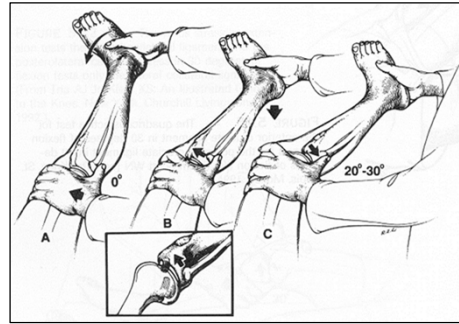
- Knee flexed 20-30°
- Hamstrings relaxed
- Stabilize femur, pull anteriorly on proximal tibia
- Evaluate Anterior Excursion / Endpoint
- Most sensitive exam for ACL tears



Lachman Test

ACL Tears

- Knee extended, valgus
Internal rotation
- With flexion, subluxated tibia reduces
- Graded: 0-3 (none, glide, shift, clunk)
- Difficult to elicit if hamstring spasm while patient is awake



Pivot Shift Test

ACL Tears

Contact Injuries:
25% of injuries
Result from a direct
blow to the knee or leg
Concurrent injuries
frequent



ACL Tears

Non-Contact Injuries:

75% of injuries

No direct trauma to the knee

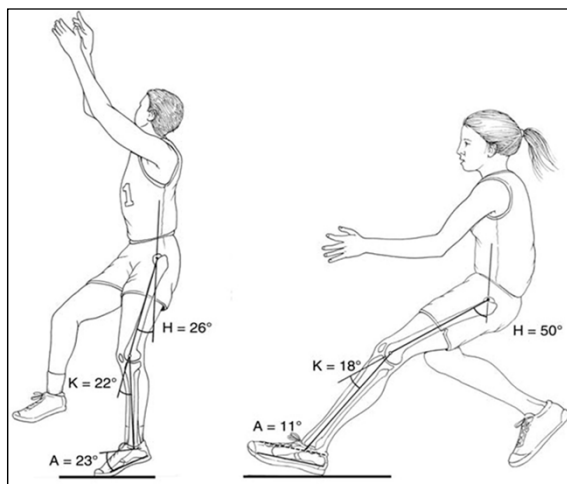
Typically during deceleration move:
stop, cut, or landing

Many factors contribute



ACL Tears

Safe



At Risk

Boden et al, JAAOS, 2010
Griffin et al, JAAOS 2000

ACL Tears

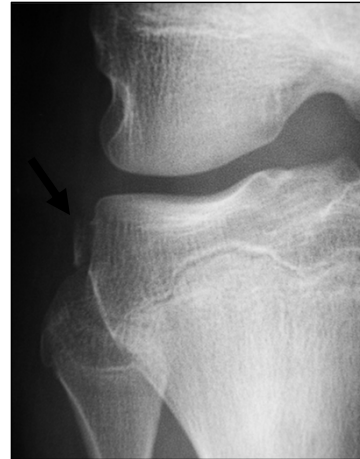
Radiographs

Critical to rule out other injuries
(fractures/ dislocations)

May see tibial spine avulsions in
the skeletally immature

Second Fracture

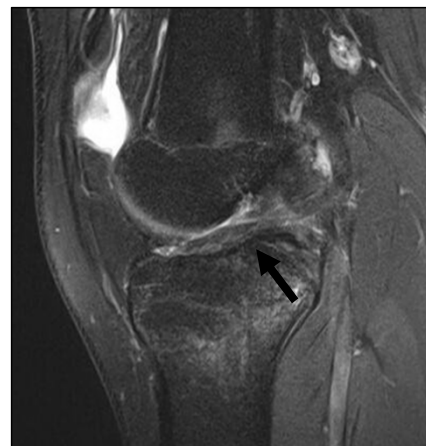- Pathognomonic for ACL tear



ACL Tears

MRI Scan:

- Most sensitive and specific test for evaluation of the ACL
- High T2 signal in intra-articular notch
- Discontinuity and inability to visualize remaining fibers



ACL Tears

Bone bruises

Lateral femoral condyle terminal sulcus

Posterior lateral tibial plateau

Meniscus tear

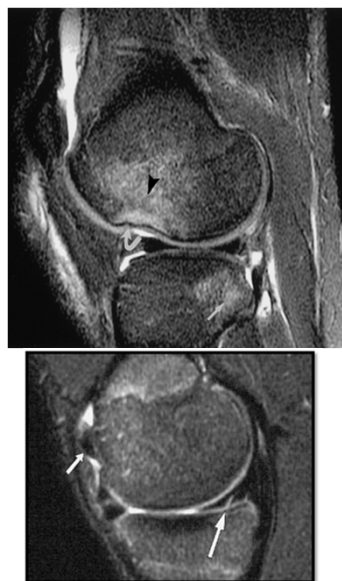
40% of index ACL injuries

Lateral meniscus more common in acute injuries

Medial meniscus in chronic injuries

MCL

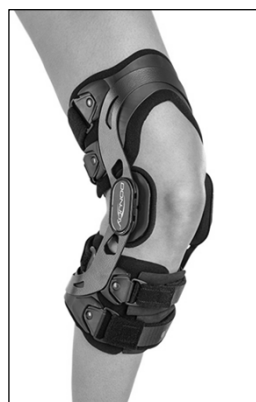Common, usually grade 1 or 2



ACL Tears

Non-Surgical Treatment:

- Includes PT and bracing
- Good option in some patients not wanting to return to cutting/ pivoting sports
- Some “copers” may do well without an ACL in all activities
- Prolonged ACL deficiency is associated with increased risk of meniscus tear and osteoarthritis.

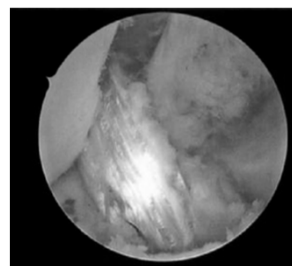
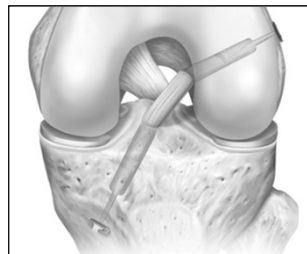


Eastlack et al, MSSE, 1999
Oiestad et al, AJSM, 2009
Neyret et al, RCO, 1988

ACL Tears

Surgical Treatment:

- Recommended in the majority of athletes wishing to return to cutting/ pivoting sports
- Timing
 - Usually 2-3 weeks post-injury
 - Pre-hab important to regain quadriceps strength.
- Graft choice
 - Patellar tendon
 - Hamstrings
 - Quadriceps tendon
 - Allograft



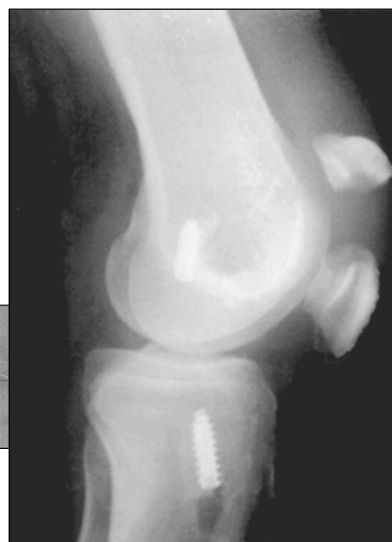
What we've previously used...

Benefits:

- Bone to bone healing
- Faster graft incorporation.
- Low failure rate
- Stable length over time

Risks:

- Anterior knee pain
- Anterior knee numbness
- Graft/ tunnel length mismatch
- Patella fracture



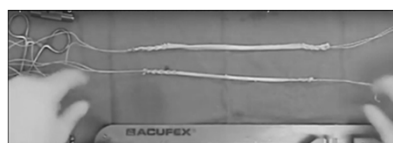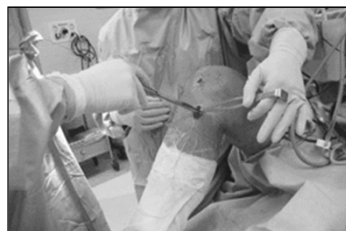Hamstrings Grafts

Benefits:

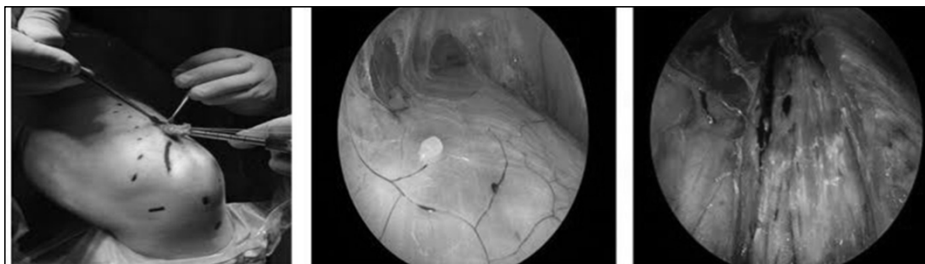
- Smaller incisions
- Less donor site pain
- Easier graft passage
- Graft/ Tunnel length match assured

Risks:

- Slower incorporation time
- Hamstring weakness
- Narrow tendons/ graft (< 8 mm)
- Graft lengthening/ laxity.
- Higher failure rate



What we've started to use...




Benefits:

- Larger, thicker tendon
- May be harvested with or without a bone plug
- Newly developed techniques allow minimally invasive graft harvest
- May be split for double bundle reconstruction.



Sheehan et al., BJSM, 2018. Fu et al., Arthroscopy, 2010

Comparing Autografts... Which one is the best?



- Highly debated
- No clear favorite
- Surgeon preference/ experience reigns

Shelton et al., JAAOS, 2011.

Factors to Consider in Anterior Cruciate Ligament Autograft Selection

Graft Type	Anterior Knee Pain	Anterior Knee Numbness	Failure Rate	Knee Tightness	Residual Weakness	Extension	Patient Satisfaction
BPTB	High	High	Low	High	Quadriceps muscle	High	High
Hamstring	Low	Low	Slightly higher	Slightly lower	Hamstrings	Low	High
Quadriceps	Low	Low	Low	High	Quadriceps muscle	Low	High

BPTB = bone–patellar tendon–bone

J Am Acad Orthop Surg 2011;19: 259-264

Allografts... Failure rate in young athletes

Risk Factors and Predictors of Subsequent ACL Injury in Either Knee After ACL Reconstruction

Prospective Analysis of 2488 Primary ACL Reconstructions From the MOON Cohort

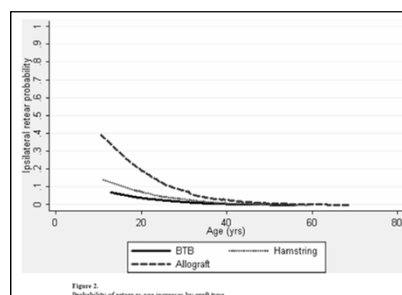
Christopher C. Kaeding,^{1,11} MD, Angela D. Pedroza,¹ MPH, Emily K. Reinke,⁸ PhD, Laura J. Huston,⁹ MS, MOON Consortium,¹ and Kurt P. Spindler,² MD
Investigation performed at the Ohio State University, Columbus, Ohio, USA, and Vanderbilt University Medical Center, Nashville, Tennessee, USA

Data from the MOON Group.
2488 subjects with primary ACL reconstruction and a minimum of 2-year follow-up.

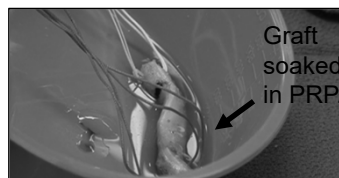
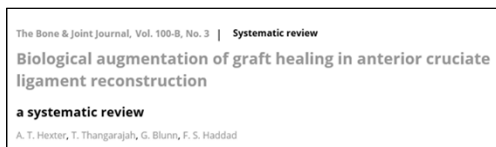Conclusion:

Younger age, higher activity level, and allograft type were key predictors of increased odds of graft failure.

Kaeding et al. AJSM 2015.



What some are using... Biologic Augmentation.



- Aim to stimulate or expedite osseous integration or intra-articular ligamentization.
- 5 categories of biologic interventions: growth factors, biomaterials, stem cells, gene therapy, and autologous tissue.
- Most interventions target the graft-tunnel interface and are applied intraoperatively.
- Platelet-rich plasma is the most commonly used and studied intervention.

ACL Tears

- No return to play same day!
- Vast majority require surgical reconstruction to regain stability for cutting sports.
- Knee must be fully rehabilitated with physical therapy.
 - Full ROM
 - Near full quadriceps strength (>80%)
- Time to return to sports after surgery:
 - 6-12 months.
- Running gait analysis?



Miller et al. 2019.

ACL Tears

Braces

- No data that braces are effective in prevention of ACL tears
- May prevent MCL injuries

Neuromuscular training programs

- Can reduce at risk positions
- Have been shown to reduce ACL injury risk in females to that of males

Griffin et al, JAAOS, 2000
Hewett et al, J Knee Surg, 2005
Magnussen et al, AJSM 2018

Knee Injuries in Sports

- Patellar dislocations and ACL tears are both common in sports.
- ACL tear leads to immediate effusion; Patellar dislocation swelling may take several hours to develop.
- Both present with history of a feeling a pop and instability.
- Radiographic evaluation is crucial to rule out fracture or dislocation.
- Patella instability may be treated nonoperatively but has a high rate of recurrence.
- ACL tears are most commonly non-contact injuries.
- ACL tears nearly always require surgical reconstruction.
- Many graft options exist. None are perfect.