

## Monkeypox

**Christina Liscynsky, MD**  
*Associate Professor - Clinical  
 Department of Internal Medicine  
 Division of Infectious Diseases*

*The Ohio State University Wexner Medical Center*

**MedNet21**  
Center for University Medical Education

**THE OHIO STATE UNIVERSITY**  
WEXNER MEDICAL CENTER

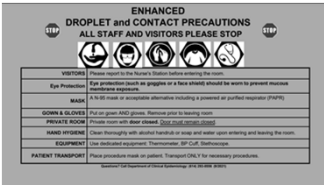
## Monkeypox Virus (MPXV)

- Orthopoxvirus
  - Same family as smallpox, but smallpox only replicates in humans (no animal reservoir)
  - MPXV is a zoonotic disease; animal reservoir unknown but suspected to be small mammals
- Brick-shaped enveloped virus measuring 200–250 nm
- Replicates in the cytoplasm, not the nucleus
- West African (WA) and Congo Basin (CB) clades
  - Two clades identified through genomic sequencing
  - WA and CB MPXV differ in virulence
  - genetically distinct
- It is suggested that WA MPXV is attenuated and less transmissible than CB

Brown K, Saghat P. Human Monkeypox: Current State of Knowledge and Implications for the Future. *Tropical Medicine and Infectious Disease*. 2021; 1(1):8. <https://doi.org/10.3390/tropicalmed1110008>

## Transmission

- Direct contact with lesion material or from exposure to respiratory secretions
- HCW PPE use for suspected or confirmed cases
  - N95 or equivalent
  - eye protection
  - gown
  - gloves



## Isolation

### Enhanced Contact and Droplet Precautions

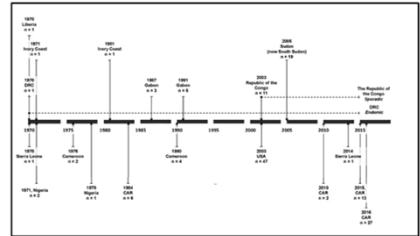
- Inpatient
  - Place patient in single patient room with a dedicated bathroom. Keep the door closed.
  - Patient should wear a mask during transport
  - Cover any skin lesions with a sheet or gown
- Outpatient
  - Should not leave the home except for medical care
  - Avoid contact with animals
  - Minimize contact with others to the extent possible
- Precautions should be maintained until all lesions have crusted, those crusts have separated, and a fresh layer of healthy skin has formed underneath

## Cleaning

- Standard, hospital approved disinfectants are efficacious
- Soiled laundry (e.g., bedding, towels, personal clothing) should never be shaken or handled in manner that may disperse infectious particles. Linens should be carefully placed into appropriate receptacles while wearing appropriate PPE

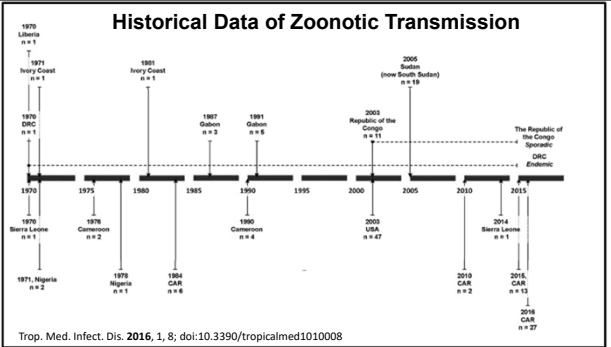
## Historical Data of Zoonotic Transmission

- 1958 – discovered in Danish Lab monkey outbreak (captive primates)
- 1970- recognized as Human disease in 9mo in Zaire (now DRC)
- Endemic to regions of West Africa and the Congo basin



Trop. Med. Infect. Dis. 2016, 1, 8; doi:10.3390/tropicalmed1010008

## Historical Data of Zoonotic Transmission



Trop. Med. Infect. Dis. 2016, 1, 8; doi:10.3390/tropicalmed1010008

## 2003 USA Epidemic

- May 24 - Wisconsin Division of Public Health was notified of a 3yo girl (Patient 1) hospitalized with cellulitis and fever after a bite from Prairie Dog 1 on May 13.
- The prairie dog had been purchased on May 11 at a swap meet and became ill on May 13 with ocular discharge, lymphadenopathy, and papular skin lesions.
- The animal died on May 20
- Enlarged submandibular lymph node was submitted for bacterial culture00



Reed KD, Miskis JW, Graham MB, et al. The detection of monkeypox in humans in the Western Hemisphere. *N Engl J Med.* 2004;350(4):342-350. doi:10.1056/NEJMo032299  
[https://en.wikipedia.org/wiki/Prairie\\_dog#/media/File:prairie\\_dog,\\_Washington\\_DC\\_1.jpg](https://en.wikipedia.org/wiki/Prairie_dog#/media/File:prairie_dog,_Washington_DC_1.jpg)

## 2003 USA Epidemic

Patient 4 - distributor of exotic animals as a side job

- May 18 - bitten and scratched by a prairie dog
- May 23 - a nodular skin lesion developed at the scratch site.
- May 26- fever, chills, sweats, and lymphadenopathy
- May 31- hospitalized.
  - Illness reported to Health Department
- June 3 -determined that he had sold two prairie dogs to the index patient's family at the swap meet



[https://en.wikipedia.org/wiki/Prairie\\_dog#/media/File:Canisys\\_Labradorius\\_Fragrant\\_Dog\\_Devon\\_England-Beag](https://en.wikipedia.org/wiki/Prairie_dog#/media/File:Canisys_Labradorius_Fragrant_Dog_Devon_England-Beag)

## Laboratory Investigation

- June 2 -electron-microscopical evidence of a poxvirus in a skin lesion from Patient 2 (mother of Patient 1), who became ill on May 26
- June 4 - orthopoxvirus was visualized by negative stain electron microscopy of cell-culture supernatants from Patient 2 and Prairie Dog 1. Confirmatory testing of tissue and skin-biopsy specimens performed from Patient 4 (Distributor 2) and Patients 7 and 8 revealed monkeypox-virus DNA signatures.
- June 7- the complete sequence of the hemagglutinin(HA) gene derived from the virus from Distributor 2 proved identical to HA gene sequences derived from one of two reference monkeypox-virus clades.
- June 9 - Tissue PCR analyses and virus-culture supernatants from Patient 2 and Prairie Dog 1 were positive for monkeypox-virus DNA signatures.

Figures: Laboratory-confirmed cases of monkeypox were confirmed by means of viral culture (C), polymerase-chain-reaction assay (PCR), electron microscopy (EM), and immunohistochemical analysis (IHC). Rounded rectangles denote distributors, rectangles households, octagons pet stores, and circles veterinary clinics.

*N Engl J Med.* 2004;350(4):342-350

**Distributor 1 in northeastern Illinois received and distributed exotic animals including African rodents and prairie dogs**

**Distributor 2 in southeastern Wisconsin purchased 39 prairie dogs from Distributor 1 between April 15 and May 17 and transported ill giant Gambian rat on May 3**

Patient 4  
Onset of illness, May 23  
C, PCR, EM

Patient 5  
Onset of illness, May 25

**Distributor 2 in southeastern Wisconsin purchased 39 prairie dogs from Distributor 1 between April 15 and May 17 and transported ill giant Gambian rat on May 3**

Patient 4  
Onset of illness, May 23  
C, PCR, EM

Patient 5  
Onset of illness, May 25

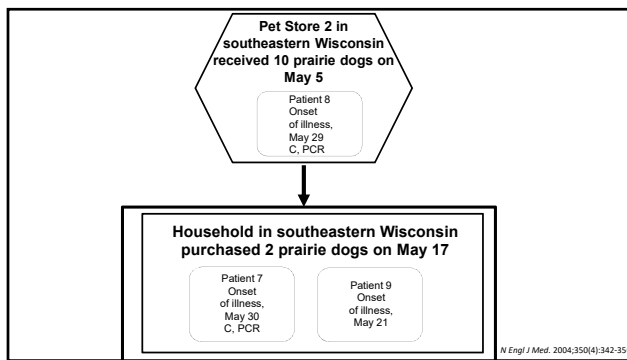
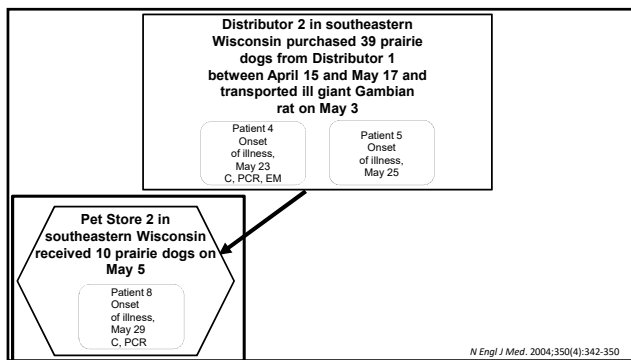
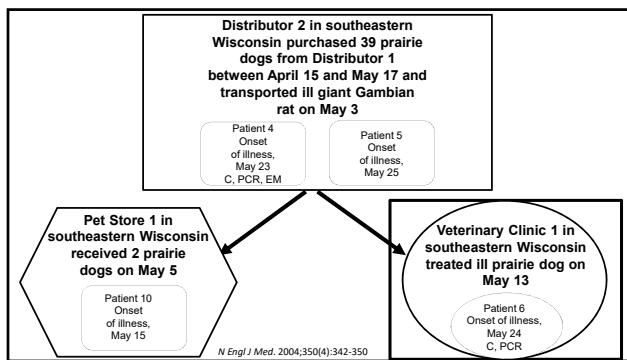
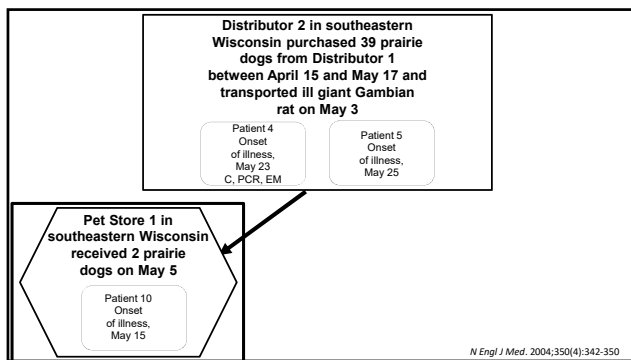
**Household in northwestern Wisconsin purchased 2 prairie dogs on May 11**

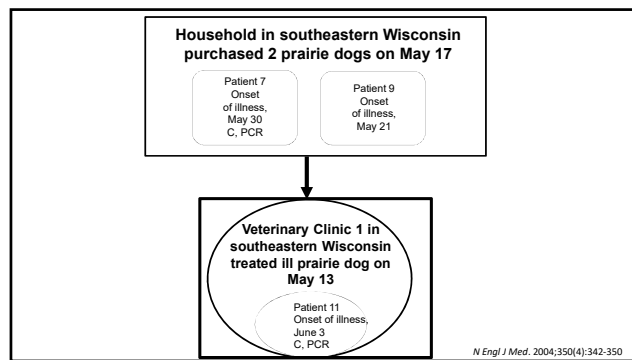
Patient 1  
Onset of illness, May 16  
IHC

Patient 2  
Onset of illness, May 26  
C, PCR, EM, IHC


Patient 3  
Onset of illness, May 31  
C, EM

*N Engl J Med.* 2004;350(4):342-350





## 2003 USA epidemic



- Consistent with the origin in a rodent from or near Ghana, gene sequences from the strain responsible for the U.S. outbreak were most closely linked to the West African clade.
- 6/11 patients were born after 1972, after routine vaccination against smallpox was discontinued among civilians
- MPX spread to five states with a total of 47 cases; zero deaths
- Initial response included restricting the capture, sale, and interstate movement of prairie dogs or domestically-bred African rodents, but CDC's restriction on African rodent importation remains in place today

[https://upload.wikimedia.org/wikipedia/commons/thumb/0/0c/Cricetomys\\_gambianus\\_as\\_a\\_captive\\_pet.jpg/1280px-Cricetomys\\_gambianus\\_as\\_a\\_captive\\_pet.jpg](https://upload.wikimedia.org/wikipedia/commons/thumb/0/0c/Cricetomys_gambianus_as_a_captive_pet.jpg/1280px-Cricetomys_gambianus_as_a_captive_pet.jpg)

## 2021 - Texas

- July 13- ED physician in Dallas evaluated a male with a 2-week history of fever, cough, and fatigue, followed by onset of a diffuse rash.
- Less than 1 week earlier, the patient had been in Nigeria for a large social gathering
- Because of the extensive pustular rash on his face, hospital staff members immediately placed the patient in an airborne isolation room, where he was managed with airborne and contact precautions plus eye protection
- Patient treated with Tecovirimat
- 32 day hospitalization - Hospital discharge delayed until a remaining lesion tested negative for *Monkeypox virus* DNA by PCR

Rao AK, Schulte J, Chen T, et al. Monkeypox in a Traveler Returning from Nigeria — Dallas, Texas, July 2021. *MMWR Morb Mortal Wkly Rep* 2022;71:509–516. DOI: <http://dx.doi.org/10.15585/mmwr.mm7114a1externalicon>

## 2021 Texas

- Dallas patient - arrived in Nigeria on June 25 and stayed in 3 urban centers<sup>1</sup>
- June 30 - diarrhea, vomiting, cough, subjective fever, fatigue
- July 8 - 1 day before boarding the first of two return flights, the patient developed a purulent rash confined to a covered part of his body. After a brief layover in the Atlanta airport, boarded a domestic flight to Dallas, and then a ride-share vehicle to his residence, where he lives alone.
- 223 contacts identified – no transmission
- Second travel related case identified in US in November 2021 Maryland<sup>2</sup>
- During September 2018–May 2021, 6 unrelated persons traveling from Nigeria received diagnoses of MPX in non-African countries: United Kingdom (4) and Israel (1) and Singapore (1)

1. Rao AK, Schulte J, Chen T, et al. Monkeypox in a Traveler Returning from Nigeria — Dallas, Texas, July 2021. *MMWR Morb Mortal Wkly Rep* 2022;71:509–516. DOI: <http://dx.doi.org/10.15585/mmwr.mm7114a1externalicon>

2. <https://www.who.int/emergencies/diseases/nipah/news/2021-don344>

## 2022 United Kingdom

- The United Kingdom Health Security Agency (UKHSA) announced a confirmed monkeypox case on May 7, 2022, in a traveler returning from Nigeria
- May 14 and 16 - UKHSA announced a second unrelated cluster of two cases and a third clustered group of four cases identified at sexual health clinics

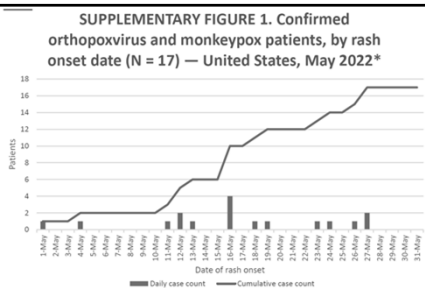
## 2022 United States

### Massachusetts

- May 4 – patient with anogenital rash 3 days after returning from international travel
- Rash progressed to vesicles and pustules and spread to the face and trunk
- May 12 hospitalized for management of refractory perianal pain from the rash.
- Prompted by UKHSA's announcement, MPX testing pursued
- May 17 - confirmed *Orthopoxvirus* locally
- May 18- CDC confirmed *Monkeypox virus* West African clade

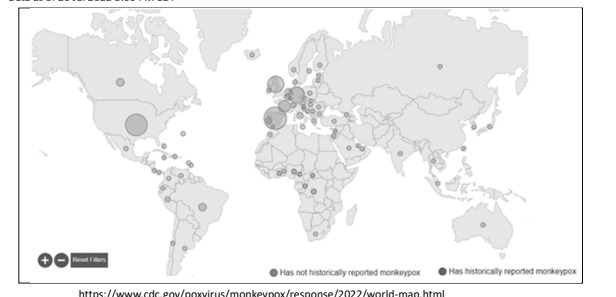
### New York

- May 4 – returning traveler with oral lesion and perianal rash; STI testing neg;
- May 19 – after MPX announcement from Mass, testing confirmed MPX



Title : SUPPLEMENTARY FIGURE 1. Confirmed orthopoxvirus and monkeypox patients, by rash onset date (N = 17) — United States, May 2022\*  
 Corporate Author(s) : Centers for Disease Control and Prevention (U.S.) Published Date : 06/03/2022  
 Series : MMWR Morbidity and mortality weekly report, Vol. 71, June 3, 2022  
 Source : Morha JF, Opatk W, Whitford T, et al. Monkeypox Outbreak — New States, May 2022. MMWR Morb Mortal Wkly Rep. ePub: 3 June 2022.  
 URL: <https://stacks.cdc.gov/view/stc/12705>

## 2022 Monkeypox Outbreak Global Map



### 2022 Monkeypox Outbreak Global Map Case Counts

	Confirmed Cases	Locations
Total	19,188	76
Countries that have not historically reported MPX	18,861	70
Countries that have not historically reported MPX	327	6

<https://www.cdc.gov/poxvirus/monkeypox/response/2022/world-map.html>

### 2022 U.S. Case Count

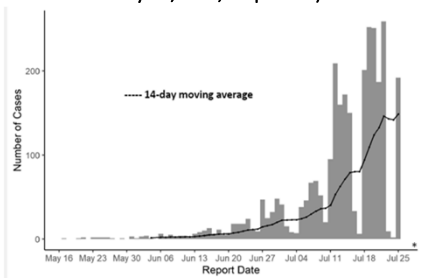
Updated July 25, 2022 at 2pm EST

- Total: 3,487 cases among U.S. residents
- 45 states, District of Columbia, and Puerto Rico
  - 3 cases in people residing outside of U.S.

State	Case Count
New York	990
California	356
Illinois	344
Florida	273
Georgia	268
Texas	220
Ohio	15

CDC COCA Call slide desk – 7.26.22

### CDC Epi Curve (Official counts as of July 25, 2022, at 2pm EST)



CDC COCA Call slide desk – 7.26.22



### Monkeypox

**Leama Ajaka, MD**

Infectious Disease Fellow, PGY-5  
Department of Internal Medicine  
Division of Infectious Diseases

The Ohio State University Wexner Medical Center

MedNet21

THE OHIO STATE UNIVERSITY  
WEXNER MEDICAL CENTER

## Risk Factors

- Contact with someone who was diagnosed with monkeypox, or had a rash concerning for monkeypox
- Skin-to-skin contact with someone in a social network experiencing monkeypox activity (eg. gay, bisexual or other MSM)
- Traveled to a country with confirmed cases of monkeypox
- Contact with a dead or live wild animal or exotic pet that exists only in Africa or used a product derived from such animals
- Any person can acquire and spread monkeypox, regardless of sexual orientation or gender-identity

## Signs and Symptoms

- Fever
- Chills
- Headache
- Muscle aches, backache
- Lymphadenopathy
- Pustular rash over skin and mucosal surfaces (variable appearance)
- Illness is self limited, typically lasting 2-4 weeks
- Can be mild to severe

## Observational Data

- April 27-June 24 2022
- 43 sites in 16 countries (majority Europe)
- 98% in this cohort – gay or bisexual men
- 5% received treatment
- Clinical signs and symptoms
  - 95% with rash
  - 62% fever
  - 41% lethargy
  - 31% myalgia
  - 27% HA 56% lymphadenopathy

Thornhill JP, Barkati S, Walmsley S, et al. Monkeypox Virus Infection in Humans across 16 Countries - April-June 2022 [published online ahead of print, 2022 Jul 21]. *N Engl J Med*. 2022;10.1056/NEJMoa2207323. doi:10.1056/NEJMoa2207323

## Skin Lesions

- |   |   |
|---|---|
| <ul style="list-style-type: none"> <li>• Site of skin lesions</li> <li>• 73% Anogenital area</li> <li>• 25% Face</li> <li>• 55% Trunk or limbs</li> <li>• 10% Palms or soles</li> </ul> | <ul style="list-style-type: none"> <li>• Site of positive monkeypox viral PCR N= 528</li> <li>• Skin or anogenital lesion = 512</li> <li>• Nose or throat swab = 138</li> <li>• Blood = 35</li> <li>• Urine = 14</li> <li>• Semen = 29</li> </ul> |
|---|---|

Thornhill JP, Barkati S, Walmsley S, et al. Monkeypox Virus Infection in Humans across 16 Countries - April-June 2022 [published online ahead of print, 2022 Jul 21]. *N Engl J Med*. 2022;10.1056/NEJMoa2207323. doi:10.1056/NEJMoa2207323



### Clinical Course –Inpatients

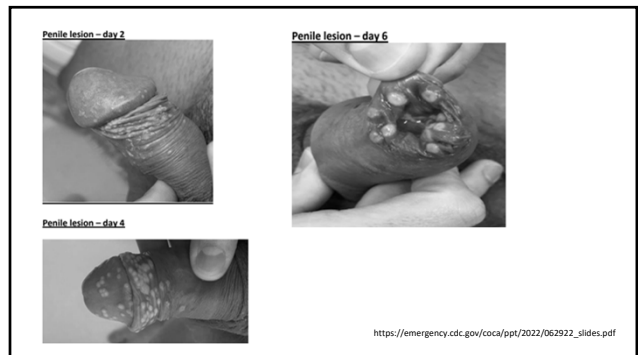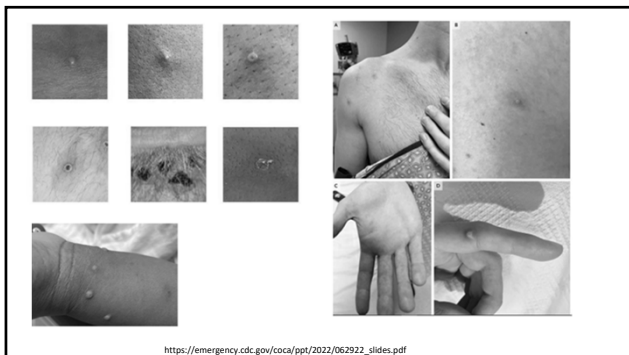
Admission Reason	Patients
Pain management	21
Soft-tissue superinfection	18
Severe pharyngitis	5
Eye lesions treatment	2
Acute kidney injury	2
Myocarditis	2
Infection control purposes	13

Thornhill JP, Barkati S, Walmsley S, et al. Monkeypox Virus Infection in Humans across 16 Countries - April-June 2022 [published online ahead of print, 2022 Jul 21]. *N Engl J Med.* 2022;10.1056/NEJMoa2207323. doi:10.1056/NEJMoa2207323

### Clinical Course –treatment

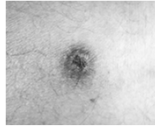
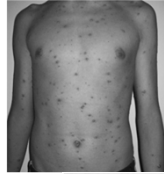- 5% of patients treated
  - Cidofovir =12
  - Tecovirimat = 8
  - Vaccinia immune globulin = 1
  - Other =2

Thornhill JP, Barkati S, Walmsley S, et al. Monkeypox Virus Infection in Humans across 16 Countries - April-June 2022 [published online ahead of print, 2022 Jul 21]. *N Engl J Med.* 2022;10.1056/NEJMoa2207323. doi:10.1056/NEJMoa2207323



## Differential Diagnosis

- HSV, VZV
- Syphilis
- Disseminated gonococcal infection
- Molluscum contagiosum
- Measles
- Scabies
- Rickettsialpox
- Smallpox
- Bacterial folliculitis
- Drug related eruption



[https://en.wikipedia.org/wiki/Chickenpox#/media/File:Varicella\\_Aranzales.jpg](https://en.wikipedia.org/wiki/Chickenpox#/media/File:Varicella_Aranzales.jpg)  
[https://en.wikipedia.org/wiki/Rickettsialpox#/media/File:Rickettsialpox\\_lesion.jpg](https://en.wikipedia.org/wiki/Rickettsialpox#/media/File:Rickettsialpox_lesion.jpg)

## Testing

- Testing for monkeypox is a clinical decision that can be made by any provider based on the patient's risk factors, exposure history and presentation
- Swab for non-variola *Orthopoxvirus* PCR
- Local health departments and commercial labs are available for molecular testing
  - Swab type and medium dependent on reference lab
- CDC offers Poxvirus serology (TAT is 14 days)

## Treatment

- Antiviral treatment can be considered for patients with severe disease requiring hospitalization and/or at high risk for severe disease, such as
  - Immunocompromised (malignancy, HIV/AIDS, etc.)
  - Younger pediatric patients, < 8 years of age
  - Pregnant
  - Those with severe secondary complications (superimposed bacterial skin infection, gastroenteritis, pneumonia)
  - Atopic dermatitis or other exfoliative skin conditions

## Treatment

- **Tecovirimat (TPOXX®)** is the preferred agent when treatment is indicated, based on limited data for safety in humans and efficacy in animal studies. There were no teratogenic effects seen in mice or rabbits.
  - Only available via the Strategic National Stockpile
  - In order to obtain TPOxx, providers must contact their state/territorial health department or CDC (Emergency Operations Center 770-488-7100; Poxvirus@cdc.gov)
- Other treatments currently stockpiled for Orthopoxviruses:
  - Vaccinia Immune Globulin Intravenous (VIGIV)
  - Cidofovir

## Tecovirimat

- Initially created due to concerns for clandestine smallpox stockpiles
- FDA approved in July 2018 for symptomatic smallpox
- inhibitor of the orthopoxvirus VP37 envelope wrapping protein
  - protein that is present and highly conserved (approximately 98% amino acid identity) in all orthopoxviruses
- VP37 is critical for envelopment of intracellular mature virus with Golgi-derived membrane to form enveloped virus
- Blocks the final steps in virus maturation and release from the infected cell, interfering with spread of virus in the host

Russo AT, Grosenbach DW, Chinsangaram J, et al. An overview of tecovirimat for smallpox treatment and expanded anti-orthopoxvirus applications. *Expert Rev Anti Infect Ther.* 2021;19(3):331-344. doi:10.1080/14787210.2020.1819791

Grosenbach DW, Honeychurch K, Rose EA, et al. Oral Tecovirimat for the Treatment of Smallpox. *N Engl J Med.* 2018;379(1):44-53. doi:10.1056/NEJMoa1705688

## Tecovirimat – Human Safety Summary

- Unethical to do studies with naturally occurring smallpox in humans
- Extrapolated animal data and human safety data
- 600mg PO BID for 14 days within 30 minutes after a full meal of moderate or high fat.
- Most Common side effects - HA and nausea
- weak inducer of cytochrome P450 (CYP)3A and a weak inhibitor of CYP2C8 and CYP2C19
  - May reduce levels of midazolam
  - May increase levels of repaglinide and cause hypoglycemia

Russo AT, Grosenbach DW, Chinsangaram J, et al. An overview of tecovirimat for smallpox treatment and expanded anti-orthopoxvirus applications. *Expert Rev Anti Infect Ther.* 2021;19(3):331-344. doi:10.1080/14787210.2020.1819791

Grosenbach DW, Honeychurch K, Rose EA, et al. Oral Tecovirimat for the Treatment of Smallpox. *N Engl J Med.* 2018;379(1):44-53. doi:10.1056/NEJMoa1705688

[https://www.accessdata.fda.gov/drugatfd9\\_docs/label/2018/208637/000001.pdf](https://www.accessdata.fda.gov/drugatfd9_docs/label/2018/208637/000001.pdf)

## Vaccination Strategies

- Pre-exposure prophylaxis (PrEP)
  - Vaccination prior to exposure given high risk of contracting monkeypox
  - At this time, the majority of US clinicians are not advised to receive orthopoxvirus PrEP
- Post-exposure prophylaxis (PEP)
  - Vaccination following exposure to monkeypox to help prevent illness
  - Can be offered to exposed healthcare professionals depending on degree of exposure

## Monkeypox PrEP

- Currently, there are 2 vaccines licensed by the U.S. Food and Drug Administration (FDA) available for preventing monkeypox infection.
- **JYNNEOS** (also known as Imvamune or Imvanex)
- **ACAM2000**

## Monkeypox PrEP

- **JYNNEOS**
  - Live, non-replicating virus vaccine produced from the strain Modified Vaccinia Ankara-Bavarian Nordic (MVA-BN), an attenuated, nonreplicating orthopoxvirus
  - Two subcutaneous injections 4 weeks apart
  - No risk for spread to other parts of the body or other people.
  - People who receive JYNNEOS are not considered vaccinated until 2 weeks after they receive the second dose of the vaccine.
- **ACAM200**
  - Live *Vaccinia* virus
  - Single dose (multiple puncture technique)
  - Lesion that develops at the site of the inoculation (a “take”) can spread to other parts of the body or other people
  - Contraindicated in patients who are immunocompromised, pregnant/breastfeeding, have certain skin conditions such as atopic dermatitis, or have heart disease or 3 or more cardiac risk factors (risk of myopericarditis)

[https://emergency.cdc.gov/coca/ppt/2022/062922\\_slides.pdf](https://emergency.cdc.gov/coca/ppt/2022/062922_slides.pdf)

## Monkeypox PEP

- The JYNNEOS vaccine is available for PEP
- CDC recommends the vaccine be given within 4 days from the date of exposure in order to prevent onset of the disease
- If given between 4–14 days after the date of exposure, vaccination may reduce the symptoms of disease, but may not prevent the disease
- Recommendation for PEP for healthcare workers is based on degree of exposure

## Monkeypox PEP

- **High Risk Exposure:**
  - Unprotected contact with the skin, lesions, or bodily fluids
  - Involved in high risk AGP and not wearing N95 AND eye protection
    - \*PEP recommended
- **Intermediate Risk Exposure:**
  - Being within 6 feet for ≥3 hours of an unmasked patient without wearing a mask
  - Contact with patients clothing, skin lesions or soiled linens while wearing gloves but not gown
    - \*PEP based on informed decision making
- **Low Risk Exposure:**
  - Entered patient’s room without wearing eye protection
  - Wore gown, gloves, eye protection and at a minimum a surgical mask
  - Being within 6 feet for ≤3 hours without wearing a mask
    - \*Generally PEP not recommended

## Monkeypox Exposure in Healthcare Workers

- Infection control, occupational health, and the health department should be notified
- CDC recommends that healthcare workers who have unprotected exposures to patients with monkeypox should undergo active surveillance for symptoms such as fever and rash
- Do not need to be excluded from work duty
- Healthcare workers who have been exposed while adhering to recommended infection control precautions may undergo self-monitoring for 21 days following the exposure as determined by local health department