

Infection in the Immunocompromised Patient

John Davis, Ph.D., M.D. and
Stanley Martin, M.D.
Division of Infectious Diseases

Who's compromised?



Compromised hull on the Starship Voyager

Objectives

1. Assess factors that determine the degree of immunosuppression in a patient and correlate the net state of immunosuppression with risk for infection
2. Recognize common clinical syndromes associated with opportunistic infections in immunocompromised hosts
3. Understand the proper use and limitations of new diagnostic tests for common opportunistic infections
4. Identify therapeutic options for the management of common opportunistic infections
5. Recognize the need and options for prophylaxis of certain opportunistic infections in immunocompromised hosts

Who's compromised?

- Not just AIDS anymore!
- Increasing recognition of immune dysfunction in our patient population
- More and more solid organ and hematopoietic stem cell transplant recipients
- More and more use of immunosuppressant therapies
- Two recurring themes: exposures and degree of immunosuppression

What's immunocompromised?

- A patient's risk for infection is determined by two factors:
 1. Epidemiology/Exposures
 2. Net state of immunosuppression

Who's compromised?

- A patient's net state of immunosuppression is comprised of numerous factors:
 - ✓ Pharmacology (intensity and duration)
 - ✓ Neutropenia, lymphopenia
 - ✓ Hypogammaglobulinemia
 - ✓ Underlying autoimmune dysfunction (SLE, etc.)
 - ✓ Mucocutaneous barrier breakdown
 - ✓ Metabolic compromise (renal failure, DM, malnutrition, etc.)
 - ✓ Other infections (CMV, EBV, etc.)

Epidemiology/exposures

- Distant Exposures
 - ✓ TB, NTM, herpesviruses (HSV, VZV, CMV, EBV, HHV-8), toxoplasmosis, endemic fungi (histoplasmosis, coccidiomycosis, etc.), HBV, HCV, HIV
- Current exposures
 - ✓ Central lines, foley catheters, surgical compromise, aspiration, nosocomial flora
 - ✓ Donor-derived infections in transplant

Who remembers their pathology?

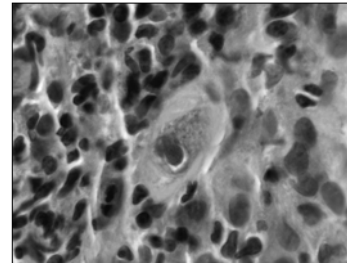
- The diagnosis of infection in the immunocompromised host is more challenging:
 - ✓ Patients may lack obvious signs of inflammation
 - ✓ Presence of more than one infection or other concomitant medical problem (e.g., exacerbation of underlying medical condition, rejection)
 - ✓ Complex pharmacology in a transplant recipient
 - ✓ Surgical and anatomical alterations

Case #1

- 56M, liver transplantation 1991 for autoimmune hepatitis
- Course complicated by chronic kidney disease (CKD) and post-transplant ulcerative colitis
- Admitted for “UC flare”: fevers, increase in diarrhea and abdominal pain

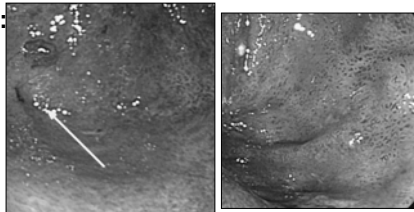
Case #1 (cont'd)

- Severely active chronic colitis
- Immunohistochemistry positive for CMV



Case #1 (cont'd)

- Medications: Mycophenolate (Myfortic), prednisone (15mg daily)
- Laboratory data: T.bili 1.2, alk phos 569, AST 68, ALT 81.
- Colonoscopy:



Herpesviruses

- 8 known Human herpesviruses
- Large, enveloped, DNA viruses
- Most are transmitted by body fluids
- Induce lifelong, latent infection in the host
- Mechanisms of pathogenesis
 - ✓ Direct destruction of tissues
 - ✓ Stimulating immunopathologic responses
 - ✓ Facilitating neoplastic transformation
 - ✓ Immune avoidance (secondary immunosuppression)

Risk for Herpesvirus disease

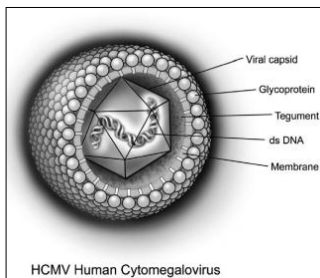
		Donor Status	
		Seropositive	Seronegative
Recipient Status	Seropositive	++	++
	Seronegative	+++	+

Infectious Syndromes of CMV

- Fever (non-specific viral syndrome)
- CNS disease
 - ✓ Retinitis (most common eye infection in AIDS)
 - ✓ Meningitis/Encephalitis
- Pulmonary disease
- GI disease
 - ✓ Hepatitis
 - ✓ Tubular GI disease (esophagitis, colitis, etc.)
- Graft-specific disease, including rejection

Cytomegalovirus (CMV)

- Herpesvirus (HHV-5)
- Seroprevalence 40-100%
- Transmission: maternal/fetal, close contact
- Most common opportunistic viral infection in the immunosuppressed



Diagnosis of CMV Infection

- Serologic methods
 - ✓ Good marker for prior infection
 - ✓ IgM unreliable for acute infection in the immunocompromised host
- Culture methods
 - ✓ Not confirmatory of pathogenesis, as asymptomatic shedding is common
- Direct antigen detection methods
 - ✓ Antigenemia assays (require WBC, time intensive)
 - ✓ PCR (nucleic acid amplification)
- Pathologic methods (immunohistochemistry)

Diagnosis of CMV Infection

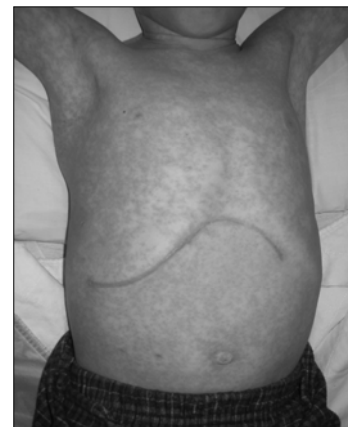- **Rules of thumb**
 - ✓ In the immunocompromised host, rely mostly on CMV PCR or CMV antigenemia assay to diagnose CMV disease
 - ✓ Sensitivity of CMV assays is lower for GI disease and CNS disease
 - ✓ Low-level positive CMV PCR assays may reflect reactivation secondary to inflammatory state from another etiology

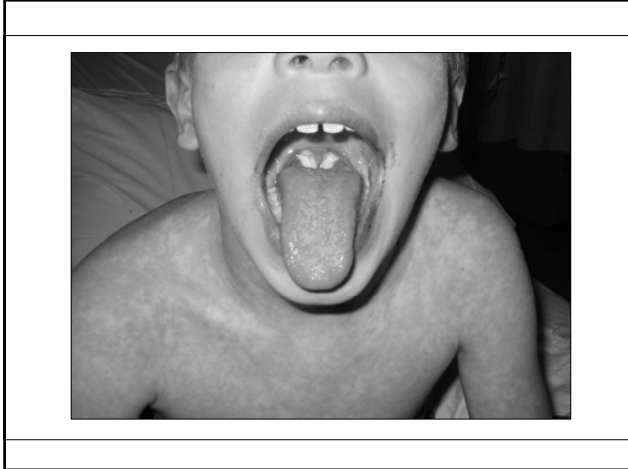Case #2

- 9 yo male S/P orthotopic liver transplant, presents with 2 weeks of nasal congestion, fevers, malaise, sore throat, and headache
- One brief episode of presumed mild rejection 2 weeks after surgery, treated by increasing tacrolimus
- Immunosuppression consisted of mycophenolate, tacrolimus, and low-dose prednisone
- Infection prophylaxis consisted of TMP-SMX and valganciclovir

Management of CMV infection: The internist's perspective

- **General Strategy**
 - ✓ Induction, ≥ 14 days
 - ✓ Maintenance, ≥ 3 months
 - ✓ Prophylaxis, before and after
- **Medications**
 - ✓ Ganciclovir (Cytovene®), Valganciclovir (Valcyte®)
 - Primary side effects: cytopenias (20-40%), CNS
 - Both must be dosed based on renal function
 - ✓ Foscarnet (Foscavir®) (renal toxicity, electrolyte imbalance), and Cidofovir (Vistide®) (renal toxicity)
 - Used rarely, for resistant CMV or intolerance to GCV/VGCV





Spectrum of EBV disease post-transplant


- **Early Disease**
 - ✓ Reactive plasmacytic hyperplasia
- **Polymorphic PTLD**
 - ✓ Polyclonal
 - ✓ Monoclonal
- **Monomorphic PTLD**
 - ✓ B cell lymphomas
 - ✓ T cell lymphomas
 - ✓ Others (Hodgkin's disease-like, plasmacytoma-like)

Taylor, AL, et al. Crit Rev in Onc/Heme. 2005; 56: 155

EBV in the setting of transplant

- The cytotoxic T cell response of the host is impaired
 - ✓ B cell proliferation may continue unchecked
- High levels of viremia may contribute toward infection of more mature B cells
 - ✓ Mature, Germinal Center, and Post-germinal Center B cells
 - ✓ These cells can enter into the growth program, but may not be able to differentiate out of it
 - ✓ These cells may also be more likely to develop somatic mutations, resulting in more aggressive growth

Post-transplant Lymphoproliferative Disorder



Black and White

Shades of Grey

Epidemiology of PTLD

- Can be seen in about 1% of hematopoietic stem cell transplant recipients
- Incidence in solid organ transplants varies depending on organ
 - ✓ Small bowel (up to 20%)
 - ✓ Lung (up to 10%)
 - ✓ Heart/Lung (up to 5-6%)
 - ✓ Heart (up to 6%)
 - ✓ Liver (up to 3%)
 - ✓ Kidney (up to 2%)

Herpesviruses

Classification of the Herpesviruses		
Virus	Subfamily	Location of Latency
Herpes Simplex Virus, type 1	α	Dorsal root ganglia
Herpes Simplex Virus, type 2	α	Dorsal root ganglia
Varicella-Zoster Virus	α	Dorsal root ganglia
Cytomegalovirus	β	Bone marrow myeloprogenitor cells
Human Herpesvirus 6	β	Bone marrow myeloprogenitor cells
Human Herpesvirus 7	β	Bone marrow myeloprogenitor cells
Epstein-Barr Virus	γ	B lymphocytes
Human Herpesvirus 8 (Kaposi's Sarcoma Herpesvirus)	γ	B lymphocytes

Therapy for PTLD

- Treatment for PTLD can involve surgery, radiation therapy, reduction in immunosuppression, anti-B cell monoclonal antibody therapy, interferon, and antiviral therapy
- Reduction in immunosuppression is universal, though rejection is a concern – up to 39% of solid organs show some form of rejection
 - ✓ Lack of response portends worse prognosis

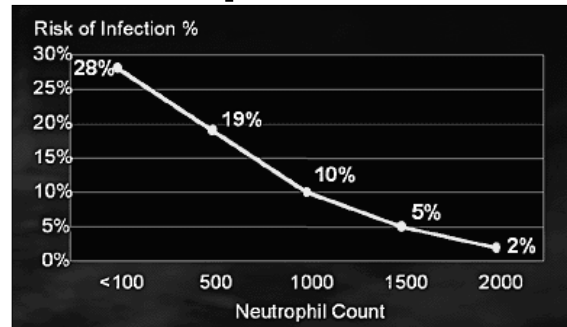
Tsai, et al. Transplantation. 2001; 71: 1076

What about other states of immunosuppression besides organ transplantation?

Case #3

- 37M presented to outside facility with bilateral leg swelling. ?cellulitis.
- CBC notable for pancytopenia, smear showed peripheral blast cells. Transferred to OSUMC for further evaluation/treatment
- Bone marrow biopsy showed AML (acute monoblastic subtype)
- Started on Ara-C, daunorubicin, midostaurin (FLT-3 inhibitor)

Infection and neutrophil counts



Bodey, et al. Ann Intern Med. 1966; 64: 328-40

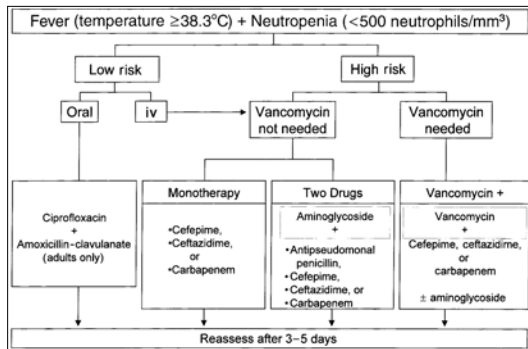
Case #3 (cont'd)

- Neutropenia noted on day +3 of chemo
- Fever to 101.4 on day +6 (day 3 of neutropenia)
- At that time, pt noted to c/o mild, non-productive cough, truncal rash.
- Exam with normal other vital signs, chest clear, diffuse maculopapular rash on trunk; R IJ CVC without purulence/erythema

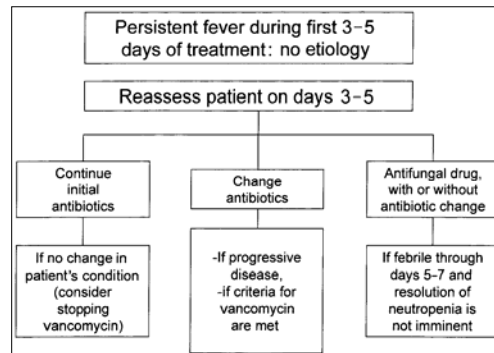
Approach to febrile neutropenia

- Complete history and physical exam
- Laboratory evaluation
- Culture data
- Radiographic data
- (But what about antibiotics?)

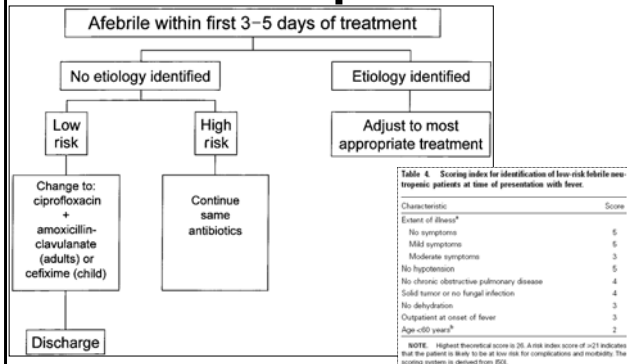
Management of febrile neutropenia



Management of febrile neutropenia



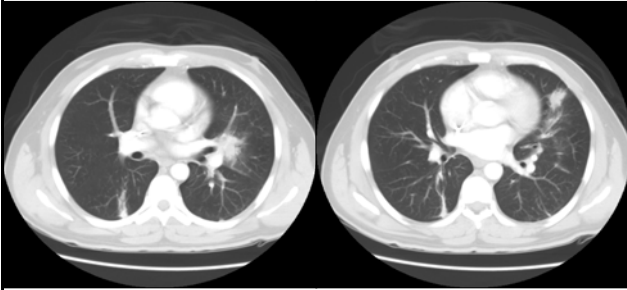
Management of febrile neutropenia



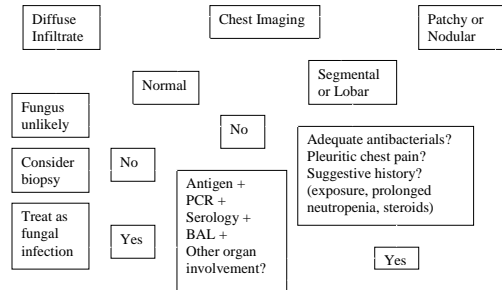
Case #3 (cont'd)

- Started on vancomycin, piperacillin/tazobactam
- Blood cultures repeatedly negative
- Urine cultures negative
- Chest X-ray clear (subsegmental atelectasis at the L base)
- Fever persists for 5 days, caspofungin started, chest CT ordered...

Case #3 (cont'd)



Algorithm for possible fungal pneumonia



From Principles and Practice of Infectious Diseases, 6th Ed. Ch 307: 3432-3441.

Pulmonary findings in the immunocompromised host

- Diffuse Infiltrates
 - ✓ Viral vs. NTM vs. non-infectious
- Segmental/Lobar Infiltrates
 - ✓ Bacterial
- Patchy/Nodular Infiltrates
 - ✓ Bacterial vs. fungal

Diagnosis of invasive fungal infection

- Proven
 - ✓ Pathology, Culture from sterile site, or CSF Cryptococcal antigen
- Probable
 - ✓ Combination of host factors, clinical criteria and mycological criteria
- Possible
 - ✓ Combination of host factors and clinical criteria

CID 2008 46:1813-1821

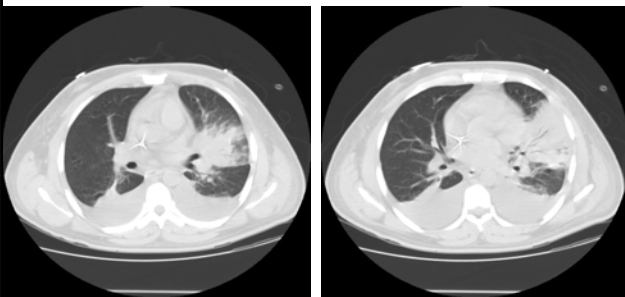
Management of invasive fungal infection

- *Candida* spp.
 - ✓ Echinocandin (Amphotericin for CNS disease)
- *Cryptococcus*
- Aspergillosis
 - ✓ Voriconazole or Amphotericin B
- Unknown mold
 - ✓ Amphotericin B

Case #3 (concl'd)

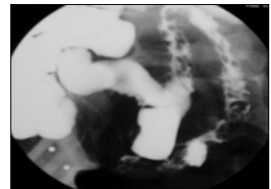
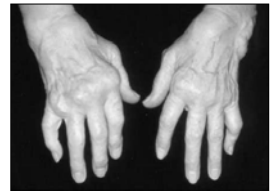- Started on amphotericin B (Abelcet)
- Creatinine rose to >3.0 mg/dL
- *Aspergillus* antigen +
- Switched to voriconazole
- ANC >500 on day +40 after chemo
- Defervesced on day +42

Case #3 (cont'd)



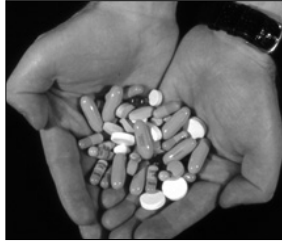Inflammatory Diseases

- Rheumatoid arthritis
- Systemic lupus erythematosus
- Sjögren's syndrome
- Polymyositis
- Dermatomyositis
- Systemic sclerosis
- Vasculitis
- Inflammatory bowel diseases
- Multiple sclerosis
- Psoriasis
- Myasthenia gravis



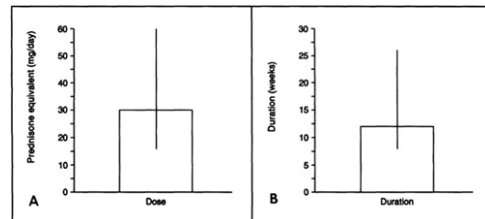
Immunosuppressant agents used to treat inflammatory disorders

- Corticosteroids
- Methotrexate
- Cyclophosphamide
- Mycophenolate
- TNF- α inhibitors
- Monoclonal antibody therapy



Mmmm... Immunosuppressants

Corticosteroids and *Pneumocystis pneumonia*



A study of 116 consecutive non-HIV infected patients on corticosteroids that developed pneumonia due to *Pneumocystis jiroveci*, noted a median dose of 30mg of prednisone daily for 12 weeks. The authors concluded that patients on long-term prednisone should be considered candidates for TMP-SMX prophylaxis.

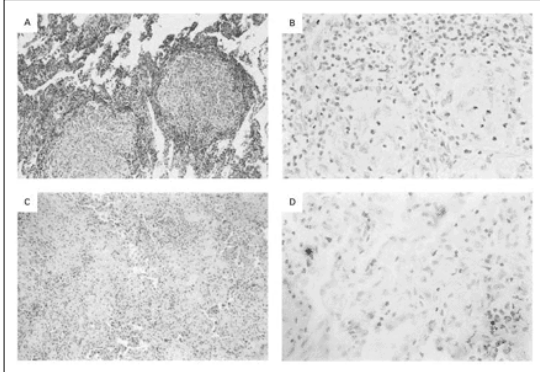
Yale, SH, et al. Mayo Clin Proc. 1996; 71: 102

Corticosteroids

- 50 years since their discovery and introduction into clinical medicine, much remains unclear about their mechanism of action, clinical potential, and side effect profiles
- Corticosteroids reduce lymphocyte and antigen-presenting cell function
- Dose-dependent effect on the immune system
- Clinical efficacy can vary widely and risk for infection remains a challenge to predict

TNF- α inhibitor therapy

- Why are granulomas important?
- Pathogens that can resist being killed by effector cells need to be contained
- Granulomas serve as a physical barrier to prevent dissemination of certain organisms even if they can't eliminate them altogether
- TNF is the cytokine probably most essential for formation and maintenance of granulomas



Lung specimens from a patient with TB not receiving infliximab (A and B) and one who did (C and D)

Keane, J, et al. N Engl J Med. 2001; 345: 1098

Granulomatous infections with TNF- α inhibitors

Infection	Presentation	Prevention	Diagnosis
Tuberculosis	Extrapulmonary disease and dissemination	TB skin test w/treatment of latent infection	Radiographic or symptom-based search, biopsy w/AFB smear and culture
Histoplasmosis	Extrapulmonary disease and dissemination	Unknown	Biopsy w/fungal stain and culture Urinary and serum antigen testing
Cryptococcosis	Meningitis	Unknown	Lumbar puncture and culture Cryptococcal antigen
Aspergillosis	Rhinocerebral or pulmonary disease	Unknown	Radiographic findings w/biopsy and fungal culture
Listeriosis	Sepsis syndrome	Avoid soft cheeses	Blood and CSF culture

Adapted from Hamilton, CD. Proc Am Thorac Soc. 2005; 2: 456

TNF- α inhibitor therapy

- Infliximab (Remicade®)
- Etanercept (Enbrel®)
- Adalimumab (Humira®)
- Certolizumab (Cimzia®)

Management of infections due to TNF- α inhibitors

- High index of suspicion needs to be maintained
- All patients should be screened for latent TB infection
 - ✓ If positive, treatment should be initiated for at least a month before starting the TNF- α inhibitor
- If any infection develops, TNF- α inhibitor therapy should be put on hold
- No feasible or well-studied screening methods in other infections

What about PCP prophylaxis?

- Solid organ transplantation
- If patients are on immunosuppressants, particularly corticosteroids, strong consideration for prophylaxis should probably be given
- Options for prophylaxis:
 - ✓ TMP-SMX (Bactrim®) – the gold standard
 - ✓ Dapsone
 - ✓ Atovaquone
 - ✓ Inhaled pentamidine

Summary

- Clinicians caring for patients receiving immunosuppressive agents need to have a high-index of suspicion for opportunistic infections
- Clinicians should try to take into account their patient's net state of immunosuppression
- Newer immunosuppressive agents are being used almost every day, but the true immunomodulatory effects and subsequent risk for infection often remain unclear

Summary

- Infections in the immunocompromised host:
 - ✓ More difficult to diagnose
 - ✓ Infection often more advanced at the time of diagnosis
 - ✓ Complicated by other medical problems, drug toxicities, etc.
 - ✓ The intensity of immunosuppression is as important as antimicrobial therapy