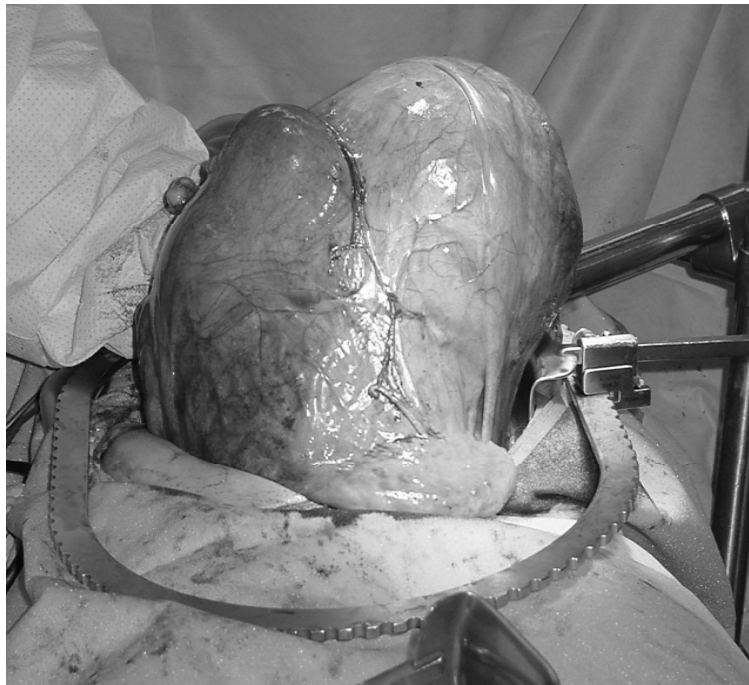
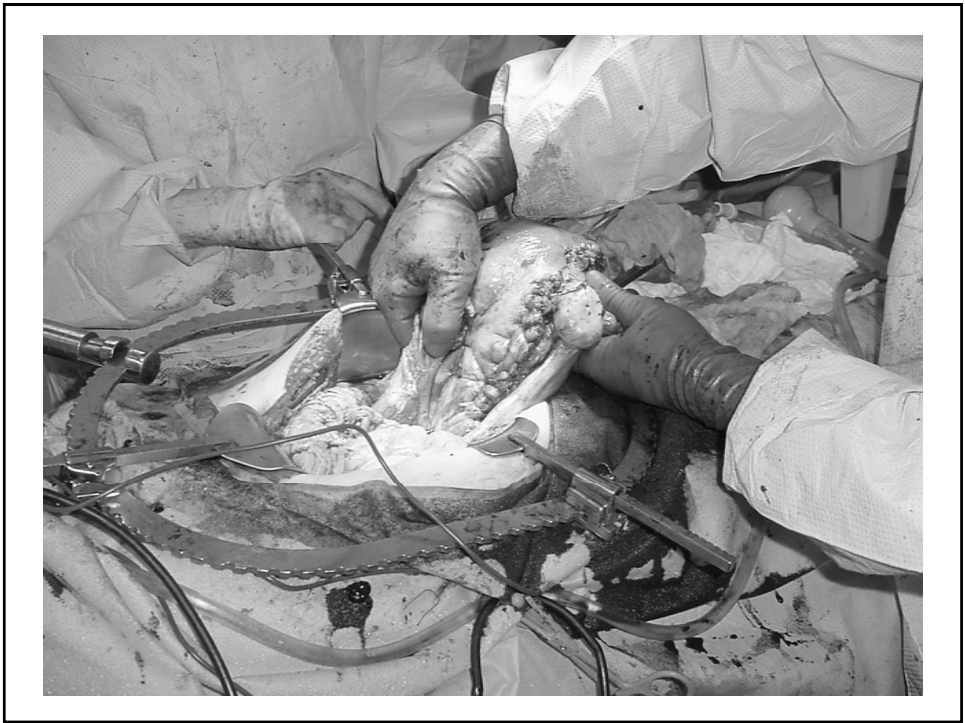
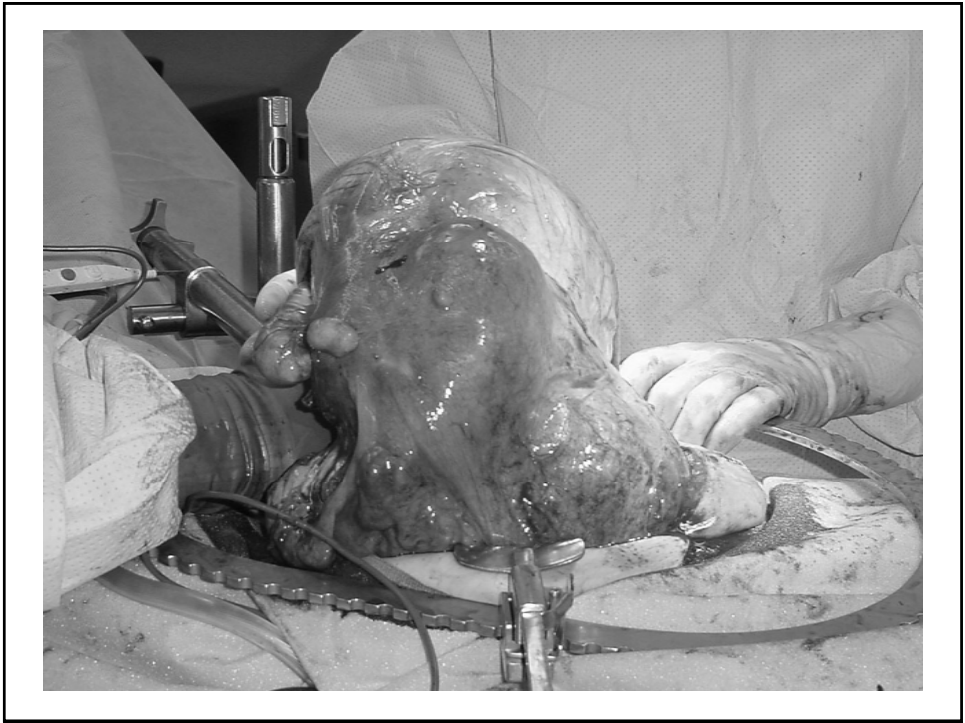Uterine Leiomyomas

Michael L. Blumenfeld, MD,
Clinical Director, Center for Women's Health
Associate Professor
Department of Obstetrics & Gynecology
The Ohio State University College of Medicine





Uterine Leiomyoma-Outline

Definition

Prevalence

Epidemiology and types

Differential diagnosis

**Clinical manifestations including
reproductive dysfunction in pregnancy**

Diagnosis and imaging

Natural history

Uterine Leiomyoma-Outline

Treatment plan

→Medical

-Contraceptive steroids

-GnRh Agonists

- aromatase inhibitors

- progestin modulators

→Surgical

**-Myomectomy: abdominal, laparoscopic,
hysteroscopic, robotic-assisted**

-Uterine artery embolization

-MRI/ultrasound ablation

**Perioperative/operative adjuncts GnRh,
vasopressin, tourniquets**

Uterine Leiomyoma

Definition:

- benign monoclonal tumors from the smooth muscle cells of the myometrium
- contain extracellular mature collagen proteoglycin and fibronectin
- Surrounded by thin pseudocapsular areolar tissue and compressed muscle fibers.

Uterine Leiomyoma

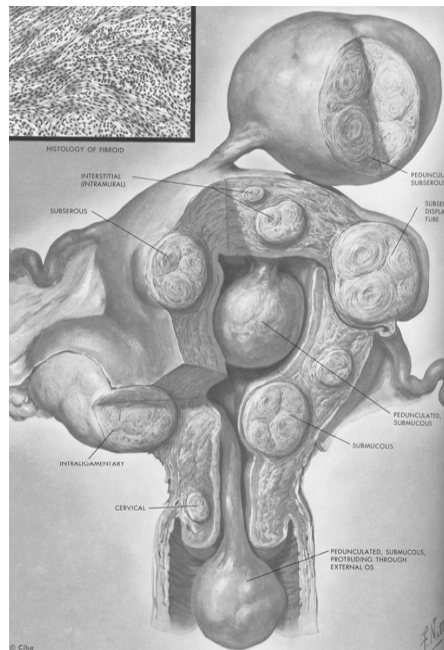
Prevalence and epidemiology:

- Genesis of the monoclonar tumor unclear
- Parallels the ontogony and life cycle changes of the reproductive system
- Noted in approximately 80% of uterine pathological examinations
- Clinical significance in about 25% of reproductive women
- Relative risk and incidence is 2-3 fold greater in black than white women
- Other risk factors: parity ↓, early menarche ↑, smoking ↓, familial ↑, injectible progestins ↓, OCP ↓, EtOH ↑
- Most common solid pelvic tumor in women

Uterine Leiomyoma

Types: (defined by location)

- **Intramural can become transmural (serosal-mucosal)**
- **Submucosal, protrudes into the endometrial cavity.**
- **Subserosal, originates from the serosal Surface**
 - **Broad**
 - **Pedunculated,**
 - **Intraligamentary**
- **Cervical - below the uterine vessels**
- **Metastatic**
- **Combined**



Netter (1984)

Uterine Leiomyoma

Types further defined for treatment

Submucosal:

- Subdivided by European Society of Hysteroscopy classification system.
- Clinically relevant in predicting outcomes of hysteroscopic myomectomy.
- Type 0: Completely intracavitary
- Type 1: at least 50% of volume is in cavity
- Type 2: at least 50% of volume is in uterine wall.

Uterine Leiomyoma

Differential Diagnosis:

- Adenomyosis-much different pathology and treatment plan
- Leiomyosarcoma
 - very rare, about .25%
 - Not necessarily associated with rapid growth ,but considered
 - postmenopausal patients with pelvic mass abnormal bleeding, and pain.

Uterine Leiomyoma

Differential Diagnosis- Continued

- Benign metastasizing leiomyomas: leiomyoma into lesion are present in uterus and distant locations
- Leiomyomas of uncertain malignant potential:
 - mitotic index
 - cellular atypia
 - extent and pattern of necrosis
- Cellular leiomyoma: typically considered benign histological variant but may be more similar to a sarcoma
- Others: lymphangioleiomatosis, intravenous leiomyomatosis, leiomyomatosis, peritonealis disseminate

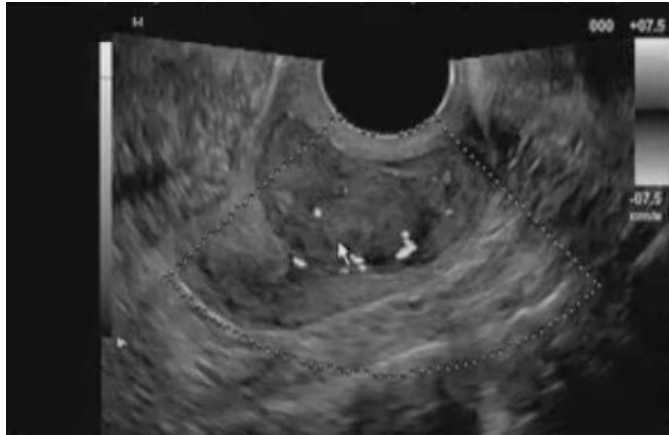
Uterine Leiomyoma

Clinical Manifestations

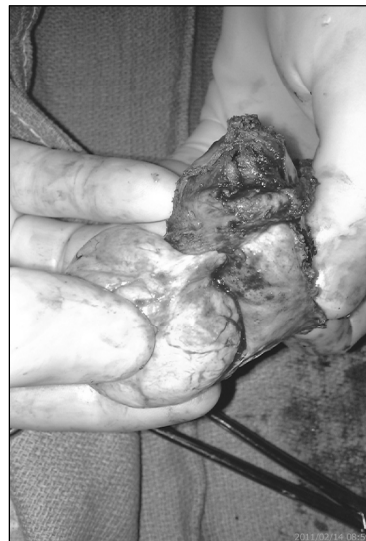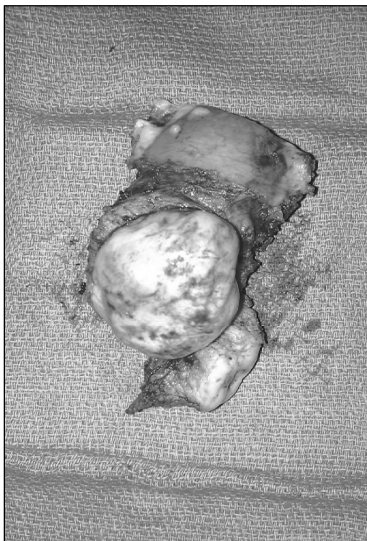
Main Three

1. Increased uterine bleeding→ menorrhagia
→location mainly submucosal
-menorrhagia, iron deficiency anemia, interference with life function, social, and productivity.
2. Pelvic pressure and pain
→Pressure→ urinary frequency, difficulty emptying bladder, rarely obstructive, constipation, dyspareunia, rarely silent uterine compression
3. Reproductive dysfunction

Pedunculated Myoma-Hx of severe bleeding



Pedunculated Myoma-Hx of severe bleeding



Uterine Leiomyoma

Reproductive Dysfunction

- Difficult to quantitate the impact
- Associated with sub-fertility and adverse pregnancy outcomes.
- Pregnancy
 - increases risk of 1st trimester bleeding, abruption, breech presentation, dysfunctional labor and increased risk of cesarean section.
 - Related to the size of leiomyoma and position of the placenta
- Myomectomies- not indicated to prevent pregnancy complications except in women with a history of obstetric complications that appear to be related to the myoma
- Fertility- estimated to account for 1-2% of infertility
- Location is a key factor, mainly submucosal

Uterine Leiomyoma

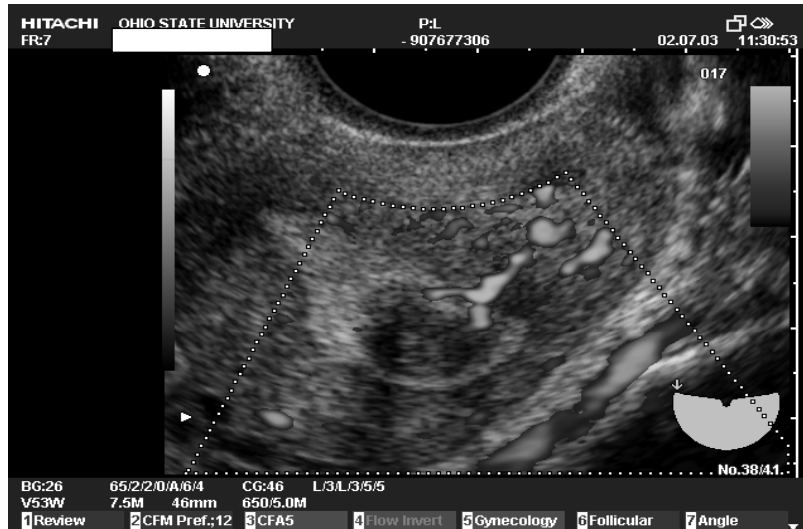Diagnosis:

Physical exam: Enlarged, mobile , irregular uterus

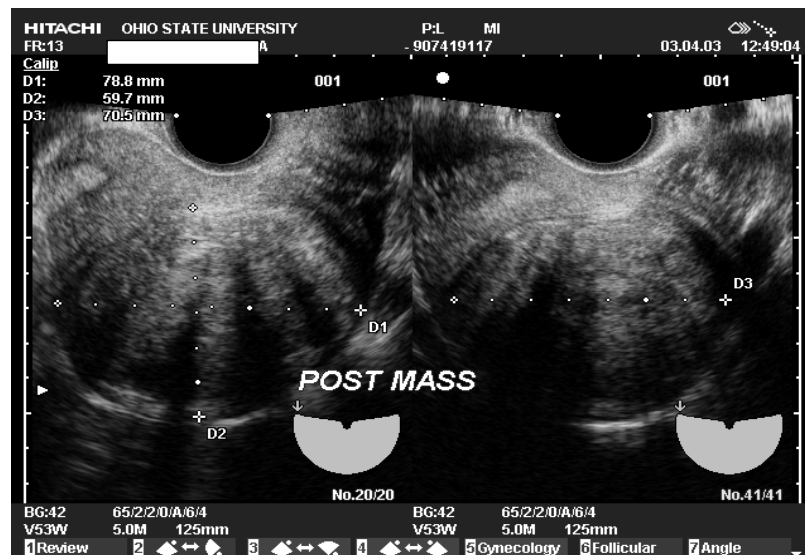
Imaging:

- Ultrasound- highly sensitive 95-100%
- Sonohistogram enhances endometrial cavity assessment
- Hysterosalpingography (HSG)- good technique for defining the contour of the endometrial cavity otherwise limited
- MRI considered best modality for imaging the size, location of all myomas, differentiation of myomas, adenomyosis, adenomyoma, and possible leiomyosarcoma-(pre-op for robotic)
- CT- very helpful as well, combination with ultrasound

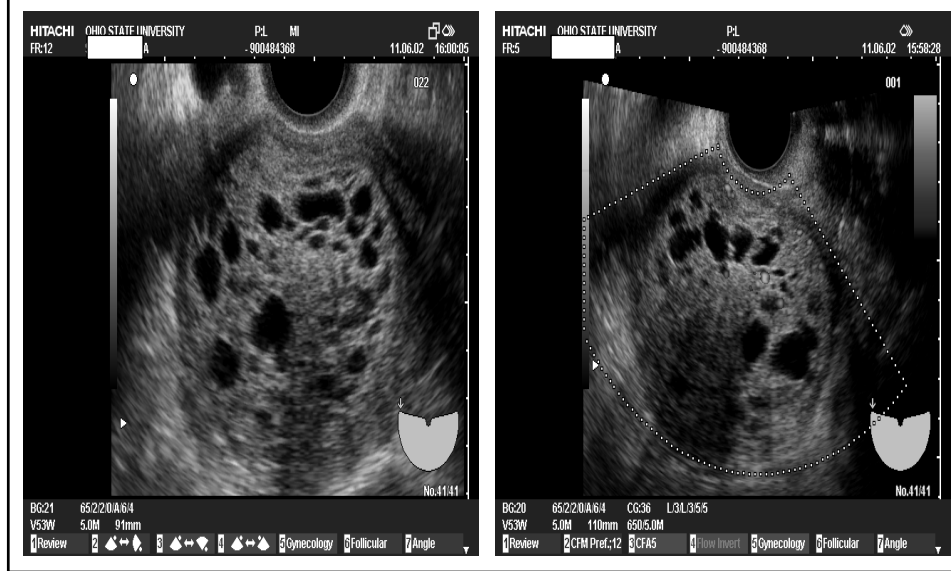
Leiomyoma-submucosal



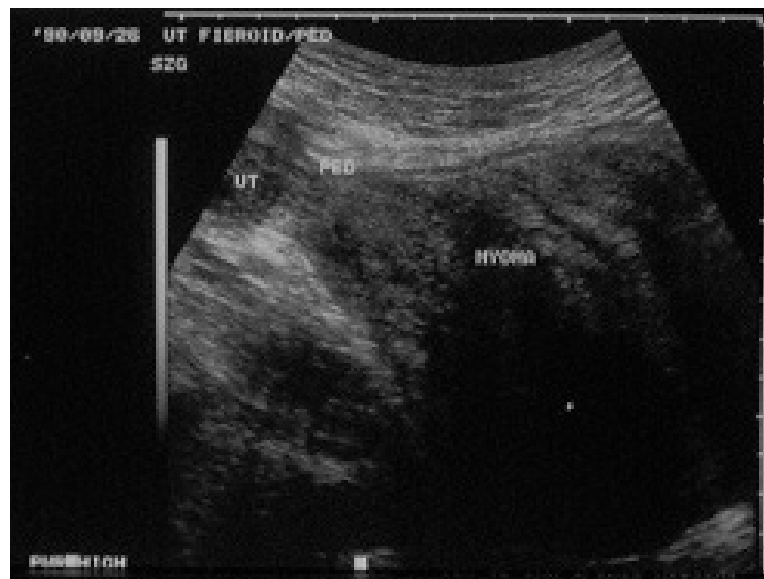Leiomyoma: Intramural-subserosal



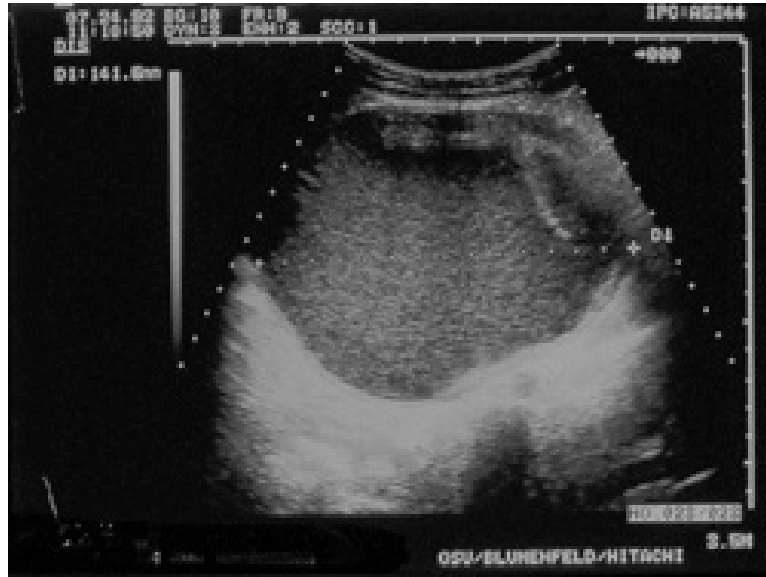Leiomyoma:cystic degeneration



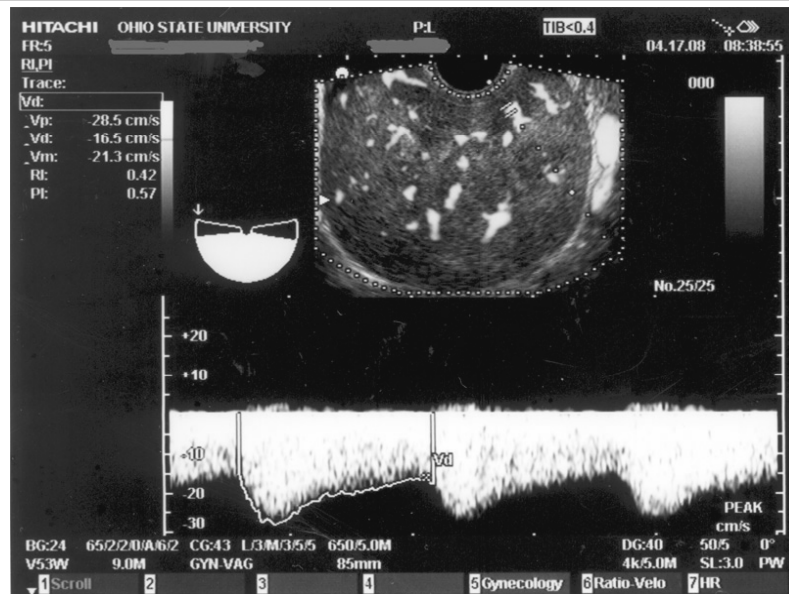
Leiomyoma:pedunculated



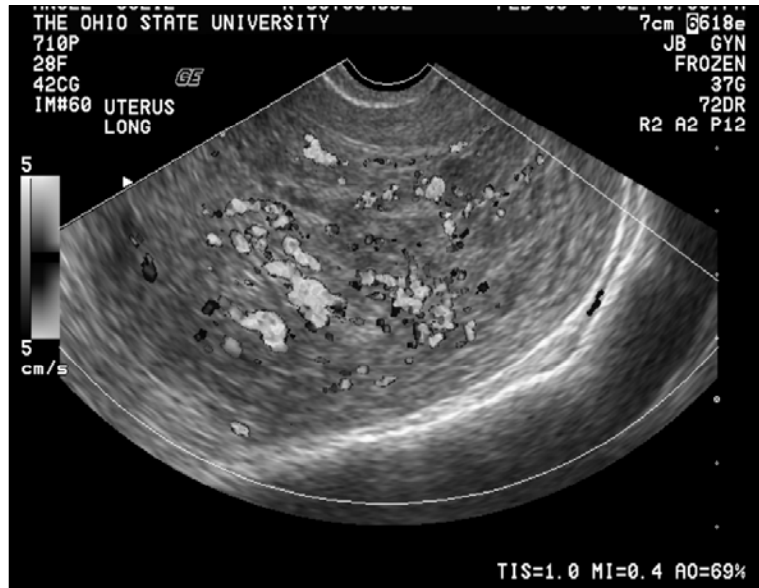Leiomyoma:Cystic Degeneration-hemorrhagic



Leiomyoma-Angiomyoma



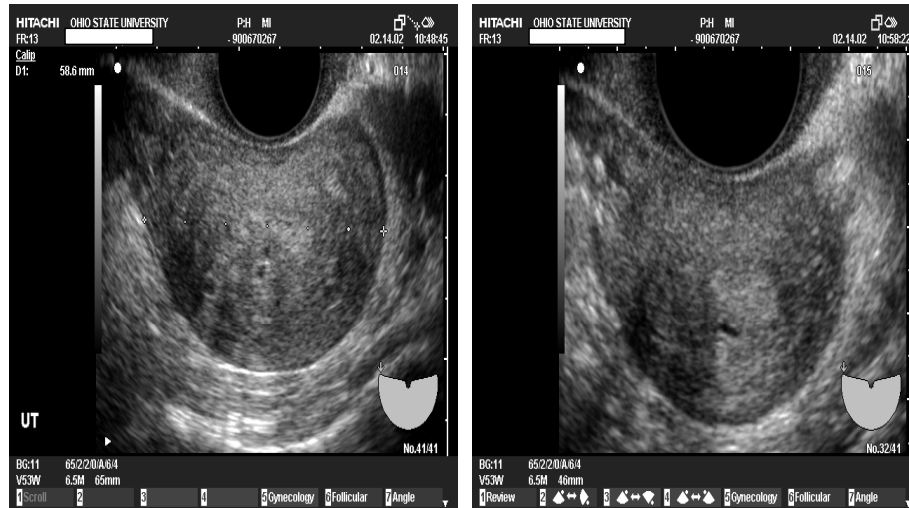
Leiomyoma-Stump



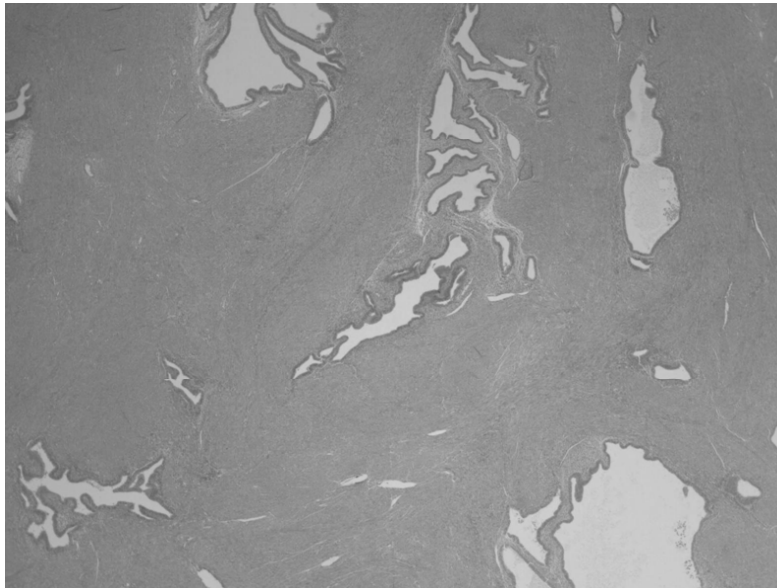
Adenomyosis

- Endometrial tissue within myometrium
- Underdiagnosed
- Cause of uterine / pelvic pain / central
- Subendothelial, but not limited to that area
- Asymmetric myometrial thickening
- Avascular-(less)
- Small sonolucent areas-myometrial cysts-2-4mm
- Diffuse infiltrative process
- U/S findings may vary with cycle/hormonal rx

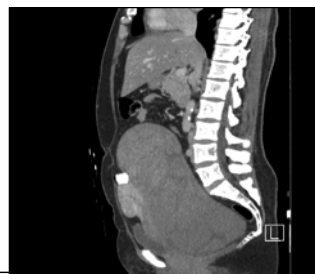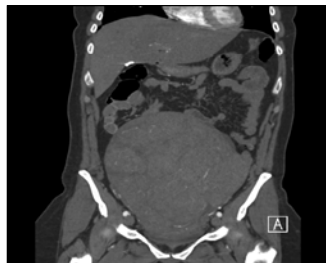
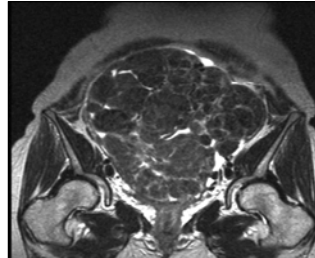
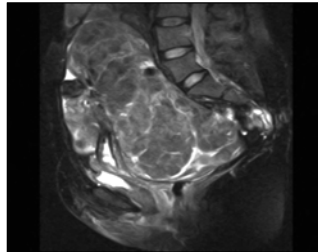
Adenomyosis



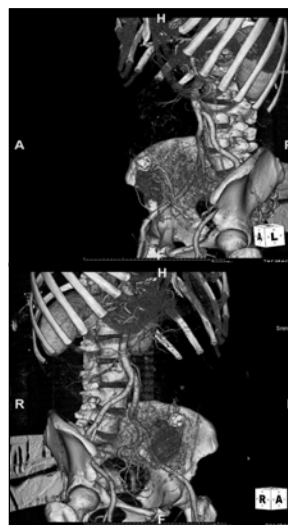
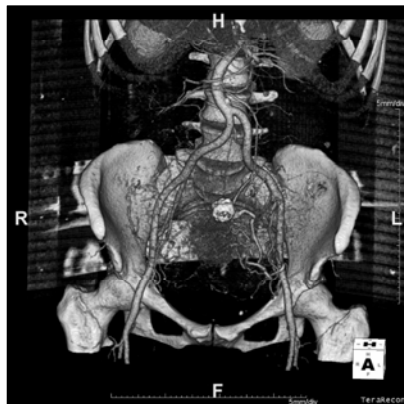
Adenomyosis, low power- J. A.----trh bso



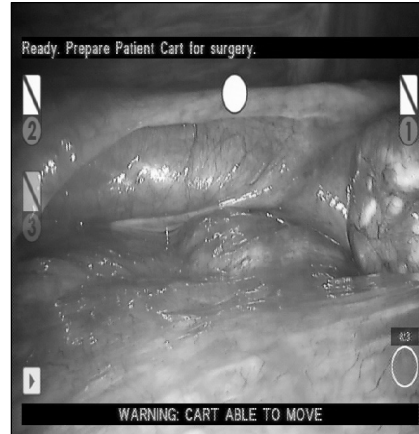
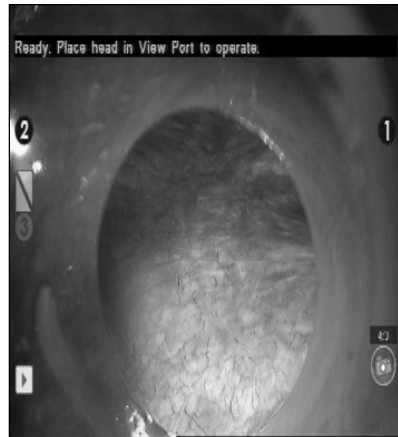Uterus with 28wks size mass



Uterus with 28wk size mass



Uterus with 28wk size mass- Robotic assisted Hysterectomy



Uterine Leiomyoma- Treatment

Pharmacological Options:

- Contraceptive steroids- first in line therapy for controlling menstruation and dysmenorrhea,
- less beneficial in the long run for patients with uterine leiomyomas.
- Variable results, but usually do not stimulate significant growth
- Progestin alone may decrease leiomyoma size (or control symptoms and maintain stability-DepoP)
- Combined therapy and progestin may decrease risk of developing clinically significant leiomyoma

Uterine Leiomyoma-Treatment

Levonorgestrel IUD

- Excellent delivery method of levonorgestrel
- Localized beneficial effect – may equal endometrial ablation Rx.
- but may have higher rates of expulsion and spotting- submucosal / endometrial distortion

NSAIDs agents

- Effective in reducing dysmenorrhea
- No major studies documenting improvement with dysmenorrhea secondary to leiomyomas.
- Patients often self treated prior to presentation

Uterine Leiomyoma-Treatments

GnRh Agonists:

- Luprolide acetate approved by FDA for preoperative therapy in women with anemia in conjunction with supplemental iron.
- Leads to amenorrhea in most women and provides 35-65% reduction in volume in 3 months of therapy
- Effects are temporary with gradual recurrent growth to previous size - (~ 6-24 months)
- Limited to 6 months without add-back therapy (?) (Only low-dose preparations have been studied)
- Maximal results using sequential regiment GnRh for down regulation and steroid add-back therapy after 1-3 months of therapy.

Uterine Leiomyoma-Treatments

Aromatase inhibitors

- Block ovarian and peripheral estrogen production
- Decrease E2 levels after 1 day of therapy (fewer side effects , rapid onset)
- Several small studies and case reports note reduction in leiomyoma size and symptoms
- Further research needed
- Not FDA approved

Uterine Leiomyoma-Treatments

Progestin Modulators

- Anti-progestin agents acct at level of P4 receptors.
- P4 or progestin receptors found in high concentrations of uterine leiomyoma.
- Mifepristone --most extensively studied compound
- Research studies show usefulness in controlling symptoms
- Several studies report reduction in volume (26-74%)
- Comparable to GnRh analogs with slower rate of re-growth

Uterine Leiomyoma-Treatments

Progestin Modulators

- Amenorrhea up to 90%, stable bone mineral density and decreased pelvic pressure
- Potential SE including endometrial hyperplasia without atypia (14-28%)
- Transient elevation in transaminase levels
- Need to use compounding pharmacy for clinically relevant doses
- May have short-term role in perioperative management- further studies needed

Uterine Leiomyoma-Treatment

Myomectomy-

- Uterine-preserving surgical procedure
- Incise, extract, and reconstruct

Types:

- Abdominal → laparotomy or mini-lap
- Laparoscopic → traditional or robotic-assisted
- Hysteroscopic Resection

Uterine Leiomyoma- Treatment

Myomectomy- abdominal:

- Safe and effective option for treatment of symptomatic myomas
- Long time “Gold” Standard procedure
- Morbidity overall similar to hysterectomy
- Significantly improved menorrhagia symptoms (40 - 93%)
- Significantly improved pelvic pressure
- Note well-know your preop Dx, anatomy and have a preop map and surgical plan and complete informed consent

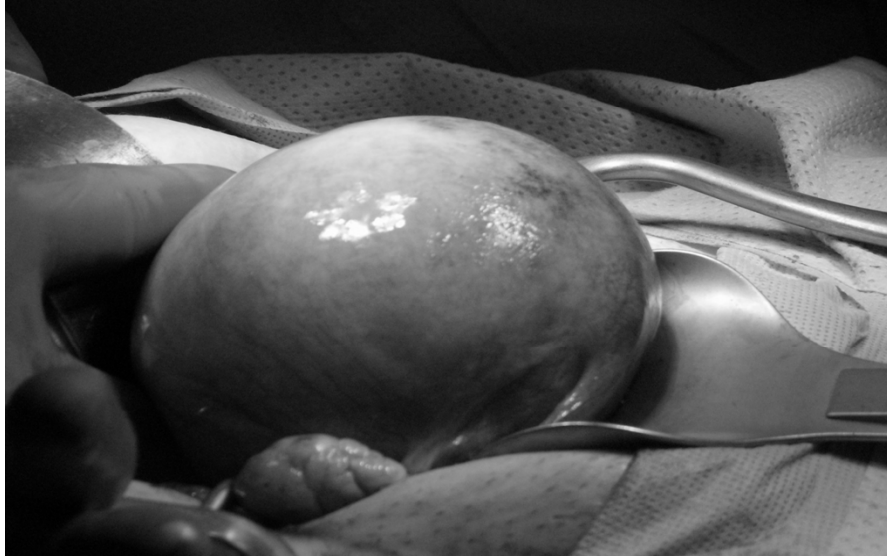Uterine Leiomyoma-Treatment

Myomectomy- Abdominal:

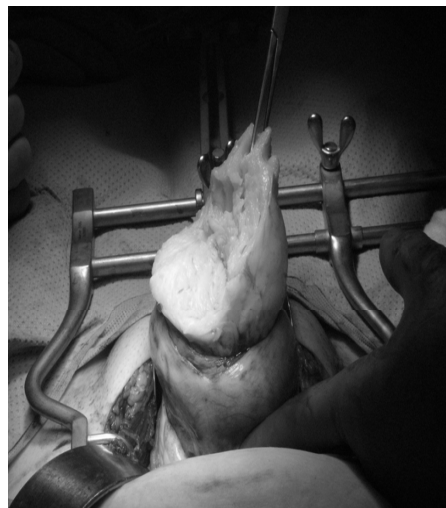
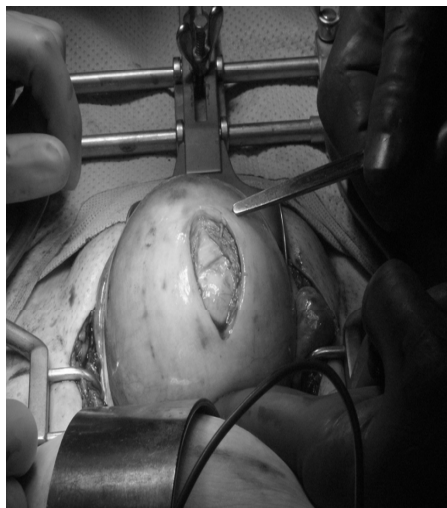
Risk of recurrence of leiomyomas

- Subsequent childbirth -↓ risk of recurrence
- Recurrence rate dependent on number of leiomyoma present
 - Single -27%, 11% hysterectomy
 - multiple -59%, 36% recurrent myomectomy or hysterectomy or both
- Risk of hysterectomy is low, less than 1% even with substantial uterine size (caution – Adenomyosis)
- Blood loss and risk of transfusion increases with larger uterine leiomyoma but location is the main key

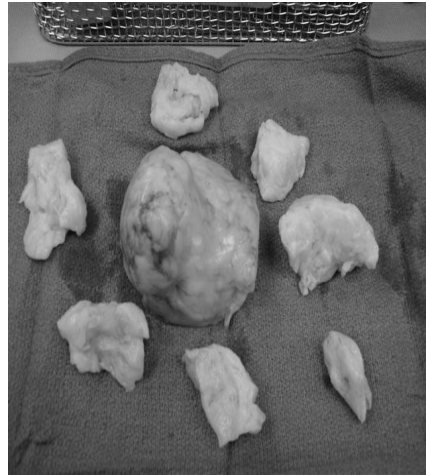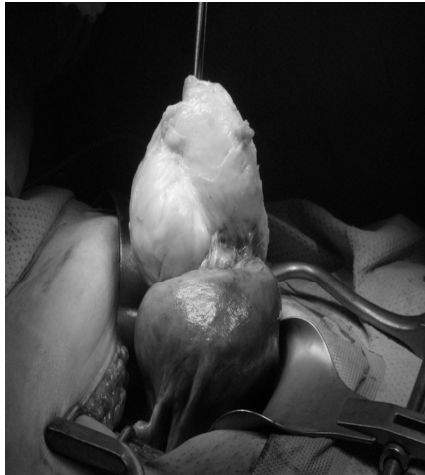Open Myomectomy



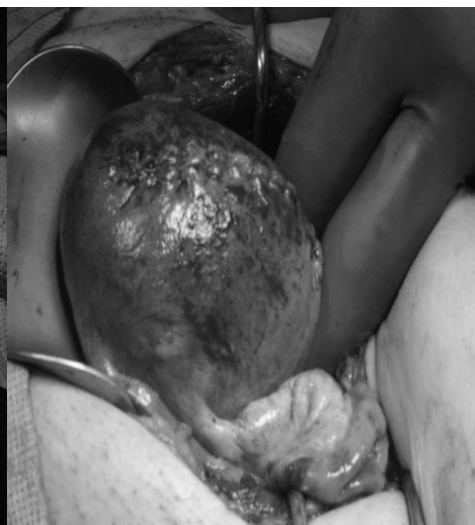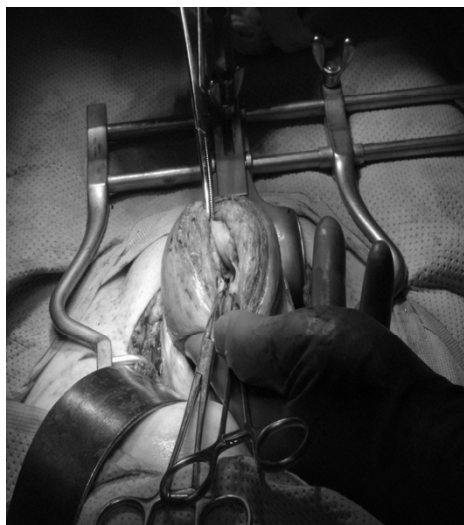Open Myomectomy



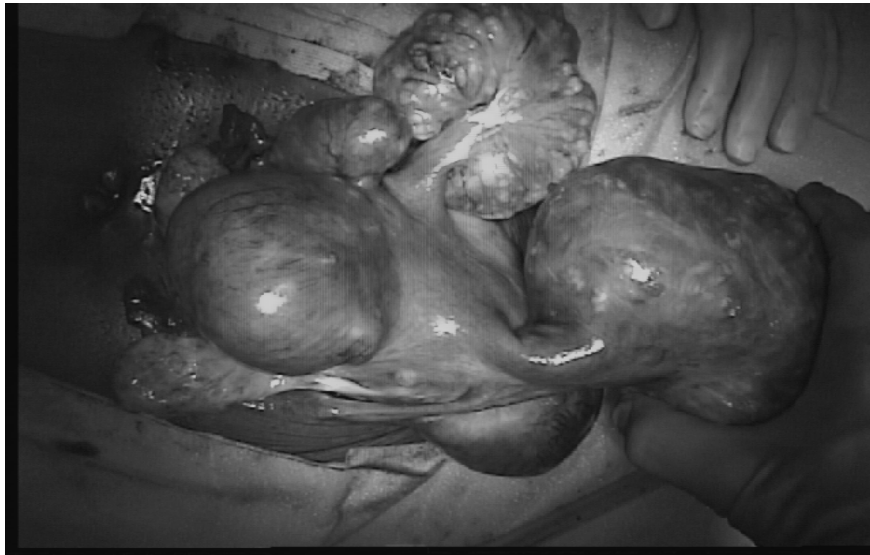Open Myomectomy



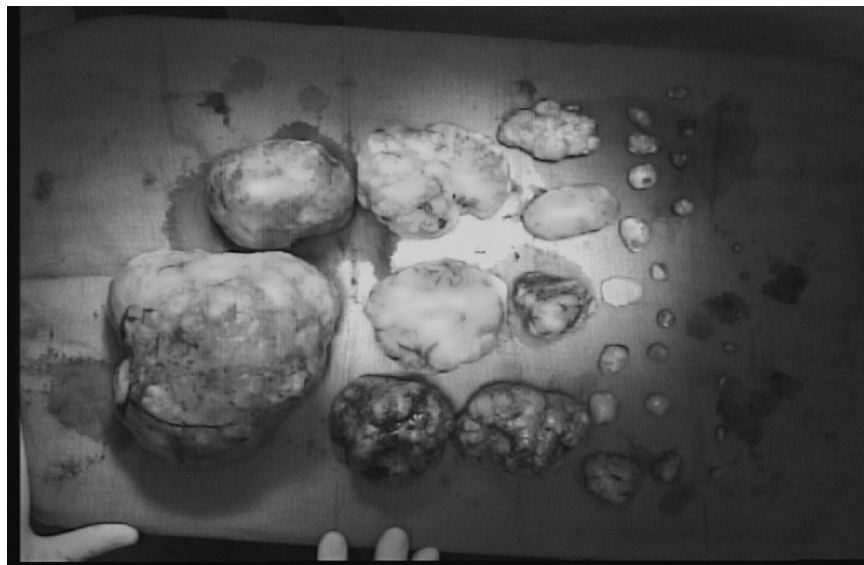
Open Myomectomy



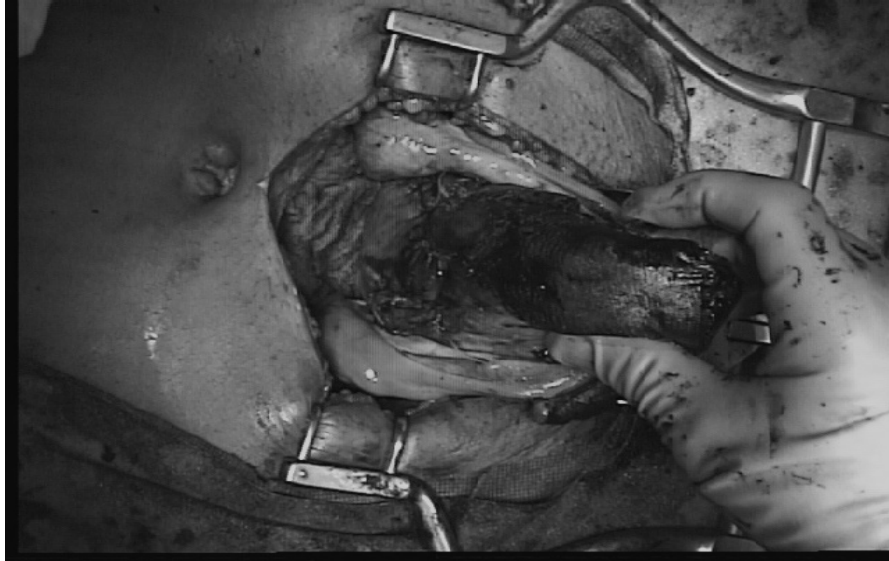
Leiomyomas-intraop decisions



Leiomyomas-intraop decisions



Leiomyomas-intraop decisions



Uterine Leiomyoma-Treatments

Laparoscopic Myomectomy

- **Minimizes size of Abdominal incisions**
 - **Quicker postoperative recovery time**
 - **Traditional Straight sticks-now evolving**
 - **Considerable Surgical expertise is required for procedure**
 - dissection, control of blood loss, reconstruction and suturing or repair
- *Procedure should mimic open or standard technique***

Uterine Leiomyoma- Treatment

Laparoscopic Myomectomy:

Case series -Sizzi (2007)- 2000 patients over 6 years.

- Complication rates between 8-11%
- Subsequent pregnancy rate 57-69%

Randomized control trial -284 patients to laparoscopy or mini-laparotomy Alessandri(2006)

- less estimated blood loss
- reduced length of post op ileus
- shorter hospital time
- reduced analgesic
- more rapid recovery (Mini-laparotomy - shorter operating time)

A second trial (Palomba 2007)- patients with unexplained infertility noted improved reproductive outcomes

Uterine Leiomyomas-Treatment

Laparoscopic Myomectomy

- Previous recommendations for laparotomy included:
 - Myomas greater than 5-8cm
 - Multiple
 - Deep
 - Intramural
- Study -Wang (2006) noted >80g myomas have longer OR time, increased blood loss, but length of stay and overall complication rate the same.

Uterine Leiomyomas-Treatment

Laparoscopic / Robotic Myomectomy

- Successful outcomes primarily reported by surgeons with expertise in advanced laparoscopy in this area.
- May not be able to generalize to all gynecological surgeons
 - (2006-8-12% did TLH)
- Robotic assistance improves :
 - Optics-high resolution
 - 3-D visualization
 - Enhanced dexterity
 - Decreased haptic sensation-preop mri
 - Increased OR time-decreases
 - Increased cost- maybe not over time and volume
 - >>>Too early to tell

Robotic-Assisted, Laparoscopic, and Abdominal Myomectomy: A Comparison of Surgical Outcomes

Barakat, Ehab E. MD; Bedaiwy, Mohamed A. MD; Zimberg, Stephen MD; Nutter, Benjamin; Nosseir, Mohsen MD; Falcone, Tommaso MD
Obstetrics & Gynecology February 2011 - Volume 117 - Issue 2, Part 1 - pp 256-266

- **OBJECTIVE:** To compare the surgical outcomes of robot-assisted laparoscopic myomectomy (robot-assisted), standard laparoscopic myomectomy (laparoscopic), and open myomectomy (abdominal).
- **METHODS:** Myomectomy patients were identified from the case records of the Cleveland Clinic and stratified into three groups. Operative and immediate postoperative outcomes were compared. Data analysis was performed using analysis of variance, Kruskal-Wallis analysis of ranks, χ^2 , and Fisher exact tests where appropriate.

Robotic-Assisted, Laparoscopic, and Abdominal Myomectomy: A Comparison of Surgical Outcomes

Barakat, Ehab E. MD; Bedaiwy, Mohamed A. MD; Zimberg, Stephen MD; Nutter, Benjamin; Nosseir, Mohsen MD; Falcone, Tommaso MD
Obstetrics & Gynecology February 2011 - Volume 117 - Issue 2, Part 1 - pp 256-266

- **RESULTS:** From a total of 575 myomectomies, 393 (68.3%) were abdominal, 93 (16.2%) were laparoscopic, and 89 (15.5%) were robot-assisted. The three groups were comparable regarding the size, number, and location. Significantly heavier myomas were removed in the robot-assisted group (223 [85.25, 391.50] g) compared with the laparoscopic group (96.65 [49.50, 227.25] g, $P<.001$) and were lower than in the abdominal group (263 [90.50, 449.00] g, $P=.002$). Higher blood loss was reported in the abdominal group compared with the other two groups, with a median (interquartile range) of blood loss in milliliters of 100 (50, 212.50), 200 (100, 437.50) and 150 (100, 200) in the laparoscopic, abdominal, and robot-assisted groups, respectively. The actual surgical time in minutes was 126 (95, 177) in the abdominal group, 155 (98, 200) in the laparoscopic group, and 181 (151, 265) in robot-assisted group ($P<.001$). Patients in the abdominal group had a higher median length of hospital stay of 3 (2, 3) days, compared with 1 (0, 1) day in the laparoscopic group and 1 (1, 1) days in the robot-assisted group ($P<.001$).

Robotic-Assisted, Laparoscopic, and Abdominal Myomectomy: A Comparison of Surgical Outcomes

Barakat, Ehab E. MD; Bedaiwy, Mohamed A. MD; Zimberg, Stephen MD; Nutter, Benjamin; Nosseir, Mohsen MD; Falcone, Tommaso MD
Obstetrics & Gynecology February 2011 - Volume 117 - Issue 2, Part 1 - pp 256-266

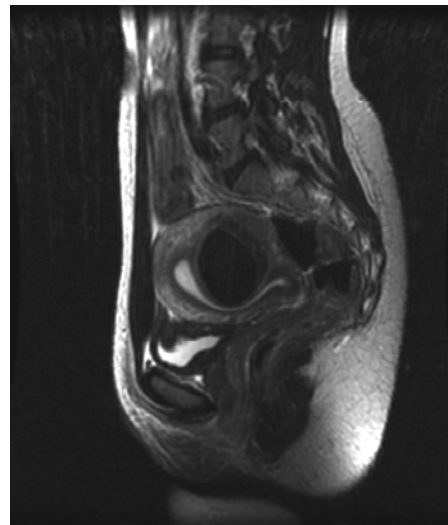
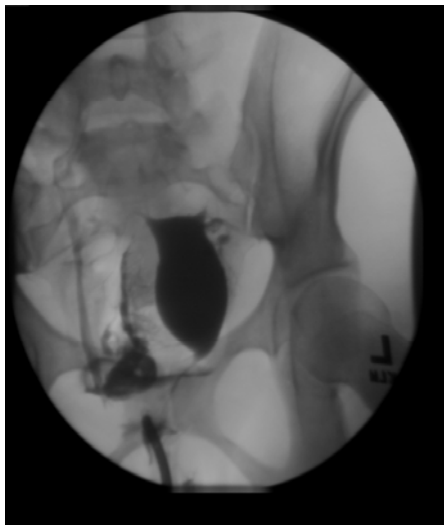
- **CONCLUSION:** Robotic-assisted myomectomy is associated with decreased blood loss and length of hospital stay compared with traditional laparoscopy and to open myomectomy. Robotic technology could improve the utilization of the laparoscopic approach for the surgical management of symptomatic myomas.
- **LEVEL OF EVIDENCE: II**

Uterine Leiomyoma-Treatment

Hysteroscopic Myomectomy

- Method of management of AUB caused by submucosal leiomyomas
- Submucosal myoma classification system predictive of success of surgical resection
- Complete resection → most predictive of success
- Uterine size and number also variables for success
- Success rate 85-95%, decreases over time
- Complication rates 1-12%
 - Fluid overload with secondary hyponatremia, pulmonary edema, cerebral edema, intraoperative and postoperative bleeding, uterine perforation, gas embolization, and infection

Submucosal Myoma-Hsg, MRI



Uterine Leiomyoma-Treatment

- **Surgical Myomectomy**
 - Risk of rupture of uterus with pregnancy, including labor
 - Trial of labor is not recommended in patients at high risk of uterine rupture → including extensive transfundal surgery
 - Garnett 1964 study → no uterine rupture in 212 patients (level 3)
 - Pooled data → 1 out of 730 cases of laparoscopic myomectomy with rupture
- Risk of rupture is low, but because of the serious complications, a high index of suspicion must be maintained

Risk factors for uterine rupture after laparoscopic myomectomy.

Parker WH, Einarsson J, Istre O, Dubuisson JB.
J Minim Invasive Gynecol. 2010 Nov-Dec;17(6):809.

- Case reports for uterine rupture subsequent to laparoscopic myomectomy were reviewed to determine whether common causal factors could be identified. Published cases were identified via electronic searches of PubMed, Google Scholar, and hand searches of references, and unpublished cases were obtained via E-mail queries to the AAGL membership and AAGL Listserve participants.
- Nineteen cases of uterine rupture after laparoscopic myomectomy were identified. The removed myomas ranged in size from 1 through 11 cm (mean, 4.5 cm). Only 3 cases involved multilayered closure of uterine defects. Electrosurgery was used for hemostasis in all but 2 cases. No plausible contributing factor could be found in one case [corrected].
- It seems reasonable for surgeons to adhere to techniques developed for abdominal myomectomy including limited use of electrosurgery and multilayered closure of the myometrium. Nevertheless, individual wound healing characteristics may predispose to uterine rupture.
- Copyright © 2010 AAGL. Published by Elsevier Inc. All rights reserved.

Uterine Leiomyoma- Treatment

Uterine Artery Embolization

Treatment by I.R.- embolizing uterine vasculature with polyvinyl alcohol particles of trisacrylgelatin microspheres, may also supplement with metal coils

Collaboration with I.R. and gynecologist important to ensure appropriateness plan of therapy

Short Term Outcome

Pron (2003)- greater than 500 patients

Favorable 3 month outcome

42% reduction in dominant myoma volume,
decreased symptoms

Uterine Leiomyoma- Treatment

Uterine Artery Embolization

EMMY (2006)- UAE vs TAH

- UAE- less pain over 24 hours
- return to work sooner
- more minor complications
- higher readmission rate 11% vs 0 %

Uterine Leiomyoma-Treatment

Uterine Artery Embolization

Long Term Outcomes-

Broder (2002) 81 patients

Reoperation rate-UAE 29% ,Myomectomy 3%

Subjective variables-UAE 39% failure, Myomectomy 30% failure

Spies (2005) 5 year follow-up of 200 patients

Re-operation rate UAE 20%

Subjective symptoms 25% failure

Mara (2006)

Re-operation rate UAE 33%

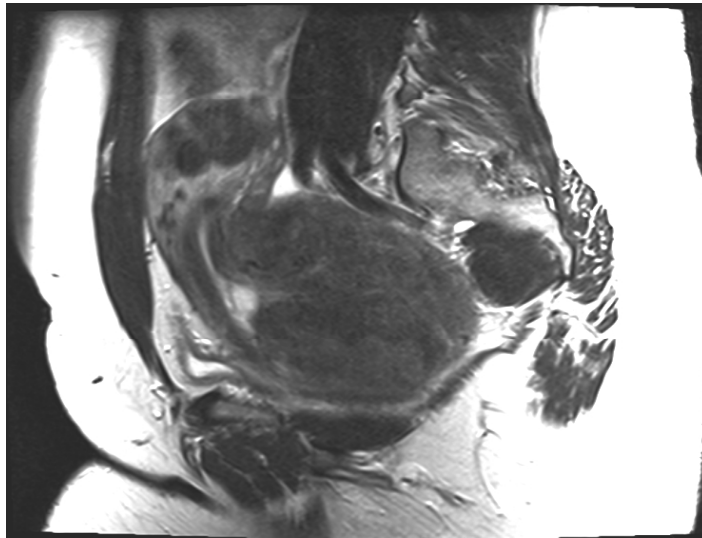
Myomectomy 6%

Uterine Leiomyoma-Treatment

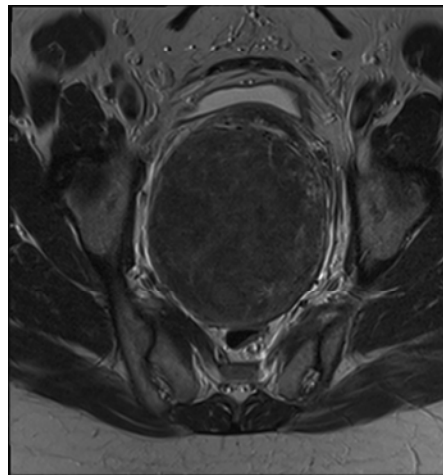
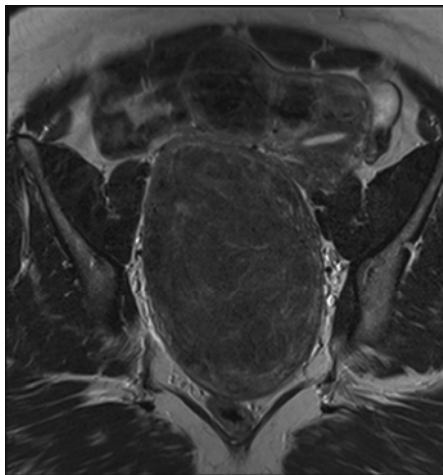
UAE- Conclusion

- **Safe and effective method if patient desires to retain her uterus.**
- **Important for Ob/Gyn-I.R. collaboration**

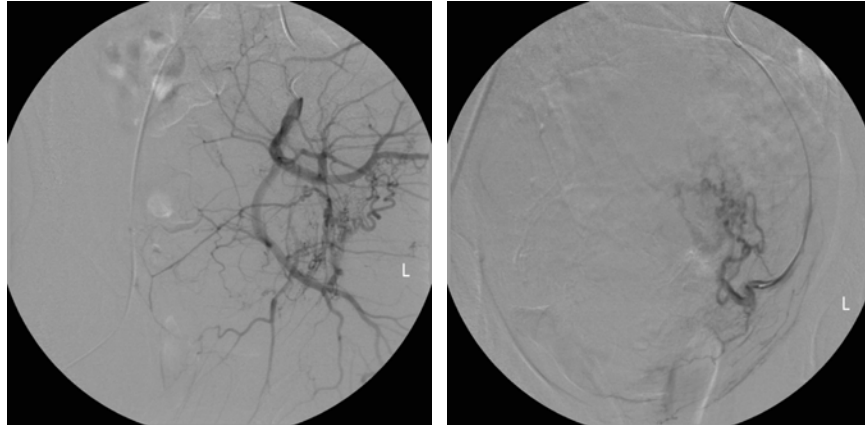
Uterine leiomyoma-Cervical?



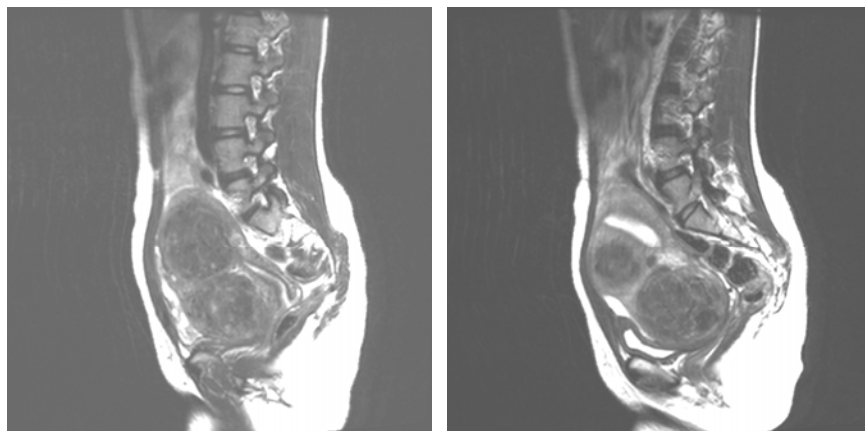
Uterine Leiomyoma-Cervical?



UAE: pre and post



Multiple Myoma –corpus and cervical



Uterine Leiomyoma-Treatment

MRI-guided Focused Ultrasound Surgery

- FDA approval in 2004
- Non-invasive high intensity ultrasound waves directed into focal volume of leiomyoma
- Energy penetrates soft tissue producing protein denaturation, irreversible cell damage and coagulative necrosis

Uterine Leiomyoma-Treatment

MRI-guided Focused Ultrasound Surgery

- Hindley (2004) and Stewart (2006)
- 109 patients → 6 months 13.5% with decreased uterine volume, 71% with decreased symptoms
- 9.4% decrease in volume over 12 months with 51% decreased symptoms
- Improvement of symptoms related to the thoroughness of treatment
- Decreased adverse outcomes with increased experience
- **Conclusion:** no major long term studies assessing the sustainability of the results beyond 24 months

Uterine Leiomyoma-Treatment

Preoperative Adjuvants

- **GnRh agonists**
 - Widely used for preoperative therapy for myomectomy and hysterectomy
 - Beneficial when significant volume reduction would modify surgical approach
 - Improves hematological parameters, shorter stay, decreased blood loss, OR time, and postoperative pain
 - Expensive (iron supplements are helpful)
 - Caution-May be disadvantageous for myomectomy as softens up the myoma and loss of surgical planes.

Uterine Leiomyoma-Treatment

Preoperative Adjuvants

GnRh Antagonists

Study reported by Flierman (2005)

- Avoids initial steroidal flare
- Rapid effectiveness with less side effects- decreased volume 25-40% in 19 days
- Not FDA approved for pre-op therapy

Intraoperative Adjuvants

- Vasopressin- decreases blood loss with infiltration- myometrium, cervix
- Tourniquets- penrose drains, vascular clamps

Uterine Leiomyoma

Leiomyomas and Fertility

- Complicated and confusing clinical issue
- High prevalence of uterine leiomyomas
- Incidence of leiomyomas increases with age, as does infertility
- Many women with myomas conceive and have uncomplicated pregnancies
- Leiomyomas noted in 5-10% of infertile women
- Sole factor in infertile women 1-2%
 - Intramural and submucosal myomas can distort cavity or obstruct tubal ostia.
 - Subsequent pregnancy rates after abdominal myomectomy 40-60% after 1-2 years
 - Several studies have shown increased pregnancy rates with myomectomy if cavity was distorted by intramural or submucosal myomas.

Uterine Leiomyoma

Leiomyomas and Fertility

-The benefits of myomectomy for large myomas may outweigh the complication rate but risk of recurrence and pelvic adhesive disease should be considered

Plan-

1. A basic infertility evaluation
2. Targeted evaluation of uterus and endometrial cavity to assess leiomyoma location, size, and number
3. Surgical therapy for a distorted uterine cavity may be reasonable
4. Consider myomectomy for those with several failed IVF cycles assuming good ovarian response and quality embryos

Uterine Leiomyoma

Leiomyomas- asymptomatic women

- In past, hysterectomy for large uterine myomas
→ Complicated assessment of ovaries and early surveillance for ovarian cancer
→ Larger uterus “had” increased rate of morbidity during surgery
- Compression of ureters and secondary compromise of renal function- rare
- Ureteral dilatation in uterus greater than 12 weeks is seen but is rare to cause secondary renal compromise

Concern of sarcoma with rapid growth

- Parker (1994) → 1332 hysterectomy specimens with pre op diagnosis leiomyoma, sarcoma 2-3 per 1000 , no more common in sub group with rapid growth
- Reiter (1992) prevalence of incidental sarcoma 1 in 2000, mortality rate for hysterectomy with benign disease → 1 to 1.6 in 1000

Conclusion: in general insufficient evidence to support hysterectomy for asymptomatic leiomyomas for above.

Uterine Leiomyomas- Summary:

Level A

1. Abdominal myomectomy- safe and effective alternative to hysterectomy based on long and short term outcomes
2. GNRH agonists- shown to improve hematological parameters, shorter hospital stay, decreased blood loss, operative time and post operative pain when given 2-3 months preoperatively. Benefits should be weighed in against cost and side effects.
3. Vasopressin infiltration- decreases blood loss at the time of myomectomy.

Uterine Leiomyomas- Summary:

Level B

- 4. Clinical diagnosis in a rapidly growing leiomyoma should not be used as an indicator for myomectomy or hysterectomy.**
- 5. Hysteroscopic myomectomy is an acceptable method for treatment of abnormal uterine bleeding with an etiology of a submucosal myoma.**

Level C

- 6. There is insufficient evidence to support hysterectomy for asymptomatic uterine leiomyoma. To improve detection of adnexal masses, prevent renal function impairment, or rule out carcinoma.**
- 7. Leiomyomas should not be considered the cause of infertility or significantly impact infertility without complete infertility assessment.**
- 8. Hormonal therapy may cause some moderate increase in leiomyoma size but does not appear to have an impact on clinical systems.**

References

Advincula AP, Song A, Burke W, Reynolds RK. Preliminary experience with robot-assisted laparoscopic myomectomy. *J Am Assoc Gynecol Laparosc* 2004;11:511–8.

Alessandri F, Lijoi D, Mistrangelo E, Ferrero S, Ragni N. Randomized study of laparoscopic versus minilaparotomic myomectomy for uterine myomas. *J Minim Invasive Gynecol* 2006;13:92–7.

Alternatives to Hysterectomy: ACOG Practice Bulletin No. 96. *Obstet Gynecol* 2008; 112(2) part 1: 387-399.

Attilakos G, Fox R. Regression of tamoxifen-stimulated massive uterine fibroid after conversion to anastrozole. *J Obstet Gynaecol* 2005;25:609–10.

Fennessy FM, Tempany CM, McDannold NJ, So MJ, Hesley G, Gostout B, et al. Uterine leiomyomas: MR imaging-guided focused ultrasound surgery—results of different treatment protocols. *Radiology* 2007;243: 885–93.

Fiscella K, Eisinger SH, Meldrum S, Feng C, Fisher SG, Guzick DS. Effect of mifepristone for symptomatic leiomyomata on quality of life and uterine size: a randomized controlled trial. *Obstet Gynecol* 2006;108: 1381–7.

Flierman PA, Obery JJ, van der Hulst VP, de Blok S. Rapid reduction of leiomyoma volume during treatment with the GnRH antagonist ganirelix. *BJOG* 2005;112:638–42.

Garnet JD. Uterine rupture during pregnancy. An analysis of 133 patients. *Obstet Gynecol* 1964;23:898–905.

Goodwin SC, Bradley LD, Lipman JC, Stewart EA, Noshier JL, Sterling KM, et al. Uterine artery embolization versus myomectomy: a multicenter comparative study. *Fertil Steril* 2006;85:14–21. (Level II-2)

References- Continued

- Gupta JK, Sinha AS, Lumsden MA, Hickey M. Uterine artery embolization for symptomatic uterine fibroids. *Cochrane Database of Systematic Reviews* 2006, Issue 1. Art. No.: CD005073. DOI: 10.1002/14651858.CD005073.pub2.
- Hehenkamp WJ, Volkers NA, Brokemans FJ, de Jong FH, Themmen AP, Birnie E, et al. Loss of ovarian reserve after uterine artery embolization: a randomized comparison with hysterectomy. *Hum Reprod* 2007;22: 1996–2005.
- Hehenkamp WJ, Volkers NA, Birnie E, Reekers JA, Ankum WM. Pain and return to daily activities after uterine artery embolization and hysterectomy in the treatment of symptomatic uterine fibroids: results from the randomized EMMY trial. *Cardiovasc Intervent Radiol* 2006;29:179–87.
- Kumakiri J, Takeuchi H, Kitade M, Kikuchi I, Shimanuki H, Itoh S, et al. Pregnancy and delivery after laparoscopic myomectomy. *J Minim Invasive Gynecol* 2005;12:241–6.
- Olive DL, Lindheim SR, Pritts EA. Non-surgical management of leiomyoma: impact on fertility. *Curr Opin Obstet Gynecol* 2004; 16: 239-43.
- Palomba S, Zupi E, Falbo A, Russo T, Marconi D, Tolino A, et al. A multicenter randomized, controlled study comparing laparoscopic versus minilaparotomic myomectomy: reproductive outcomes. *Fertil Steril* 2007;88:933–41.
- Paul PG, Koshy AK, Thomas T. Pregnancy outcomes following laparoscopic myomectomy and single-layer myometrial closure. *Hum Reprod* 2006;21:3278–81.
- Shozu M, Murakami K, Segawa T, Kasai T, Inoue M. Successful treatment of a symptomatic uterine leiomyoma in a perimenopausal woman with a nonsteroidal aromatase inhibitor. *Fertil Steril* 2003;79:628–31.
- Sizzi O, Rossetti A, Malzoni M, Minelli L, La Grotta F, Soranna L, et al. Italian multicenter study on complications of laparoscopic myomectomy. *J Minim Invasive Gynecol* 2007;14:453–62.
- Spies JB, Bruno J, Czeyda-Pommersheim F, Magee ST, Ascher SA, Jha RC. Long-term outcome of uterine artery embolization of leiomyomata. *Obstet Gynecol* 2005;106:933–9.

References- Continued

- Steinauer J, Pritts EA, Jackson R, Jacoby AF. Systematic review of mifepristone for the treatment of uterine leiomyomata. *Obstet Gynecol* 2004;103:1331–6.
- Stewart EA, Barbieri RL, Falk SJ. Overview of treatment of uterine leiomyomas. Up to Date version 17.2: May 1, 2009. Online: www.utdol.com
- Stewart EA, Gostout B, Rabinovici J, Kim HS, Regan L, Tempany CM. Sustained relief of leiomyoma symptoms by using focused ultrasound surgery. *Obstet Gynecol* 2007;110:279–87.
- Stewart EA, Rabinovici J, Tempany CM, Inbar Y, Regan L, Gostout B, et al. Clinical outcomes of focused ultrasound surgery for the treatment of uterine fibroids [published erratum appears in *Fertil Steril* 2006;85:1072]. *Fertil Steril* 2006;85:22–9.
- Varelas FK, Papanicolaou AN, Vavatsi-Christaki N, Makedos GA, Vlassis GD. The effect of anastrozole on symptomatic uterine leiomyomata. *Obstet Gynecol* 2007; 110:643–9.
- Wallach EE, Vlahos, NF. Uterine myomas: an overview of development, clinical features, and management. *Obstet Gynecol* 2004; 104: 393-406.
- Yoo EH, Lee PI, Huh CY, Kim DH, Lee BS, Lee JK, et al. Predictors of leiomyoma recurrence after laparoscopic myomectomy. *J Minim Invasive Gynecol* 2007; 14: 690–7.