

Elbow Injuries in Athletes

Timothy L. Miller, MD

Assistant Professor

OSU Orthopaedic Surgery and Sports Medicine

OSU Track and Field Team Physician

The Ohio State University Wexner Medical Center

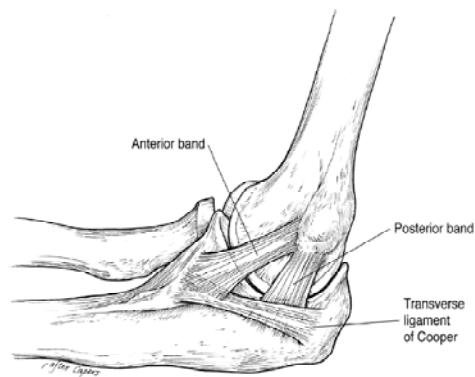
Elbow Injuries in Athletes

- **Ligamentous and Bony Anatomy**
- **Elbow Dislocations**
- **Ulnar (Medial) Collateral Ligament Tears**
- **Distal Biceps Tendon Ruptures**
- **Triceps Tendon Ruptures**
- **Lateral Epicondylitis**

Elbow Ligamentous and Bony Anatomy

MCL (UCL) Complex

- UCL complex:
 - Anterior bundle
 - Anterior band
 - Posterior band
 - Posterior bundle
 - Oblique bundle (transverse ligament)

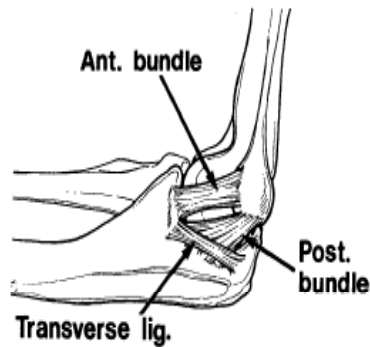


J Am Acad Orthop Surg 2004;12:405-415

EIAttrache, N, JAAOS, 2001

MCL (UCL) Complex

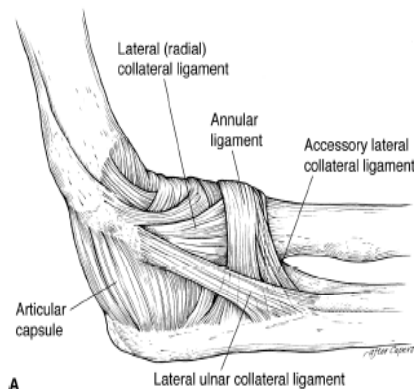
- **Anterior Bundle**
 - **Origin:** inferior aspect of the medial epicondyle
 - **Inserts:** sublime tubercle (medial aspect of the coronoid process)
 - Eccentrically located with respect to axis of elbow motion
 - Provides stability throughout full ROM
 - Functionally most important in providing stability to valgus stress of the elbow.



EIAttrache, N, JAAOS, 2001

Lateral Collateral Ligament Complex

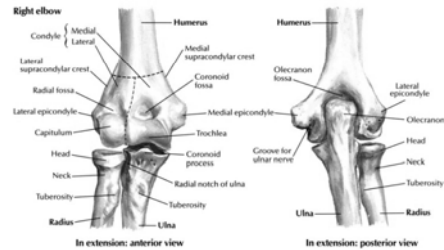
- **LCL (radial collateral)**
 - Lateral EC merges with annular ligament
- **LUCL (ulnar part of LCL)**
 - Lateral humeral EC to the tubercle of the supinator crest of the ulna
- **Accessory LCL**
 - Stabilizes annular ligament during varus stress
- **Annular ligament**



J Am Acad Orthop Surg 2004;12:405-415

Secondary Elbow Stabilizers

- At $< 30^\circ$:
 - Radial head
 - Ulnohumeral articulation
 - Anterior capsule
- At Full Extension:
 - Olecranon/Olecranon Fossa
- Muscles originate from ME:
 - PT
 - FCR
 - FDS
 - FCU
 - Provide dynamic functional resistance to valgus stress



Netter orthopaedic atlas

“Elbow Instability” - Morrey

A condition which results from both the injury and the resultant loss of function due to damage to the articular surface and the ligamentous structures that stabilize the elbow.

In order to provide a rationale for the reliable treatment of the spectrum of these injuries...

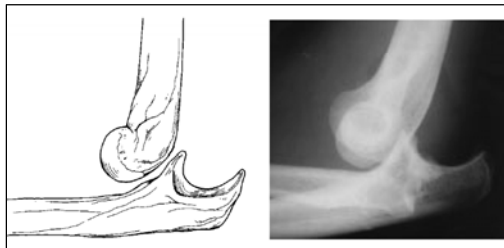
...there must be a thorough understanding the contributions of the articulation and the ligaments to the normal stability.

Morrey, BF. JBJS. 1997; 79-A; 460-9.

Elbow Dislocations

Elbow Dislocation

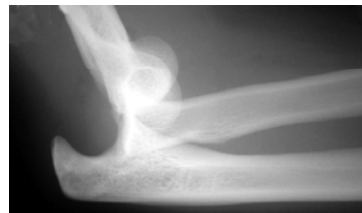
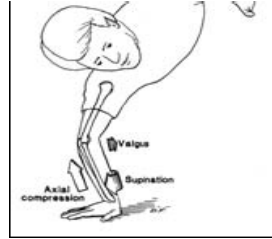
- **Second in frequency to shoulder dislocations**
- **Incidence of 6 per 100,000 persons**
 - **Most common:**
 - **Posterior**
 - **Posterolateral**
 - **80% dislocations**



J Am Acad Orthop Surg 1996;4:117-128

Elbow Dislocation

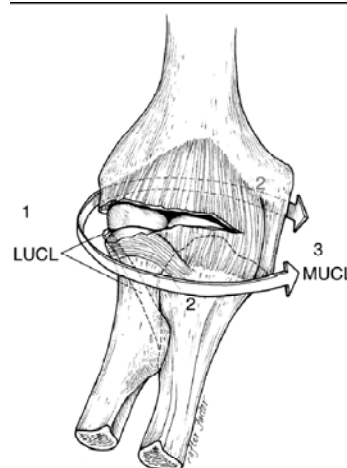
- Often caused by fall on outstretched hand
- Diagnosis is suspected and made on XR
- One must determine association of articular injuries
 - 25 – 50%
- Essential lesion which allows this...
 - Disruption of the LUCL



Morrey, BF. Acute and chronic instability of the elbow. JAAOS. 1996; 4; 117-128.

Pathophysiology

- 3 Stages of Injury: Lateral→Medial
 - Stage 1:
 - LUCL
 - Stage 2:
 - Ant. and Post. Capsular disruption
 - Stage 3:
 - MUCL
 - Stage 3B:
 - MUCL + Common flex/pronator origin disruption



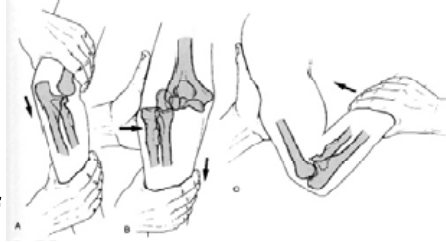
J Am Acad Orthop Surg 2004;12:405-415

O'Driscoll, Clin Orthopaedics 1992.

Elbow Dislocation-Treatment

- **Without Associated Fracture:**

- Pre-reduction PE
- Immediate reduction under conscious sedation
 - Longitudinal traction in about 45 degrees of flexion
 - Pressure on olecranon
- Post reduction assessment of stability
 - Examine joint throughout ROM
- Post reduction imaging



Morrey, BF. Acute and chronic instability of the elbow. JAAOS. 1996; 4; 117-128.

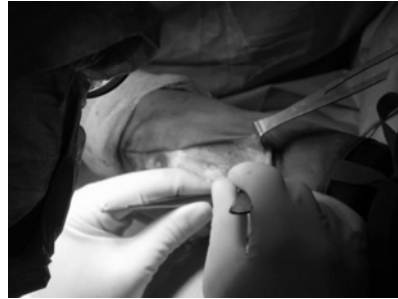Elbow Dislocation-Treatment

- **If Unstable Post Reduction:**
 - Splinted in a position of sufficient flexion for immediate stability
 - Motion in a stable arc after 5 – 7 days
 - Gradual progression of motion over next 3 – 4 weeks
 - If > 50 degrees of extension loss at 6 weeks, with a stable elbow, start hyperextension bracing at night.
 - Gradual regaining of motion by 12 months.

Elbow Dislocation-Treatment

- Length of immobilization?
 - Residual pain and loss of motion was a function of the period of immobilization

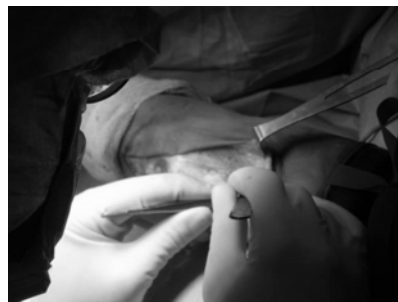(Mehlhoff, T et al., *JBJS*, 1988)



Elbow Dislocation-Treatment

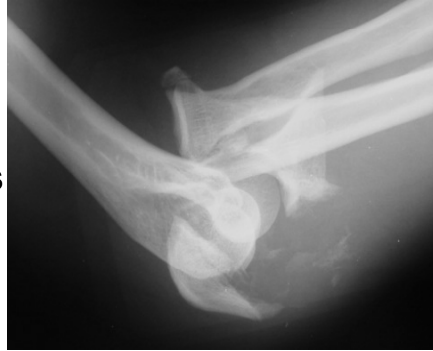- Role for Surgery??
 - Little value in uncomplicated dislocations
 - Prospective study
 - Non surgical elbows had less flexion contracture than surgically treated elbows
 - 80% of patients treated w/ surgery considered their elbow “not normal” compared w/ 50% of those treated non-operatively

Josefsson, PO, et al. *JBJS*. 1987; 69-A; 605-8.



Dislocations w/ Associated Fractures

- **More difficult to treat**
- **Requires reduction of the elbow**
- **Management of the fracture on the basis of its individual characteristics**
- **Beware of the “Terrible Triad”**
 - **Elbow Dislocation**
 - **Radial Head Fx**
 - **Coronoid Fx**



Matthew PK, JAAOS, 2009.

Medial Ulnar Collateral Ligament Injury

MUCL Tears

- Tears of the MCL are the most frequent isolated ligamentous injury of the elbow
- Seen commonly in throwing athletes (pitchers)
- c/o acute / chronic pain along the medial elbow
- Associated with valgus stress to the joint, which occurs commonly at the time of delivering a pitch/throwing.

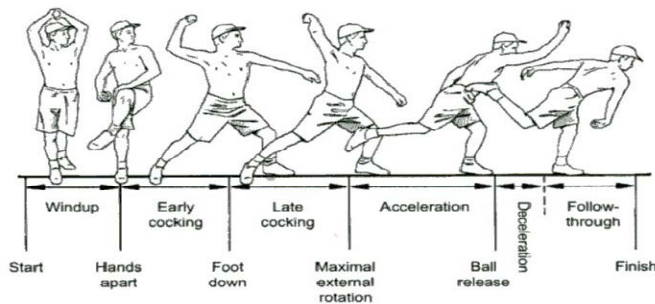


MUCL Tears: Pathophysiology

- Late cocking and early acceleration forces may exceed tensile strength of UCL
- Combination of valgus and extension loads produce tensile stress along the medial restraints (UCL, flexor-pronator m., medial epicondyle epiphysis, and ulnar nerve)
- Repetitive micro-trauma leads to gradual attenuation of anterior bundle of UCL

Conway JE, Jobe FW *JBJS Am* 1992;74:67-83

Clinical Presentation



- **History**

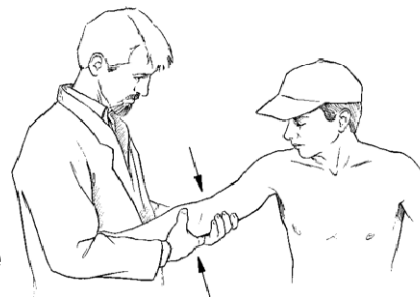Digiovine NM, JSES, 1992.

- Generally chronic and progressive medial elbow pain with repeated throwing
- Pain most severe in the cocking and acceleration phases of throwing
- Occasional “Pop” followed by sharp pain (acute injuries)
- May be accompanied by ulnar n. signs or posteromedial impingement pain
- Pt. may report loss of velocity in pitch assoc. w/ pain

Clinical Presentation

- **Physical Exam**

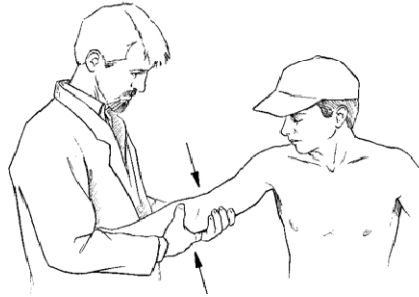- +/- ecchymosis
- Local TTP just inferior to the medial epicondyle
 - Especially over the anterior band of the MUCL



Chen FS, JAAOS, 2001.

Clinical Presentation

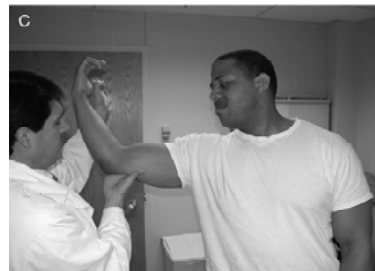- **Physical Exam**
 - **Diminished ROM**
 - loss of full extension, bony block to ext.
 - Flexion contracture in up to 50% professional pitchers
 - Pain to palpation of MCL at 50-70° flexion
 - Evaluate for ulnar n. subluxation, Tinel's



Chen FS, JAAOS, 2001.

Physical Examination

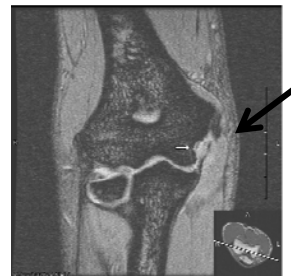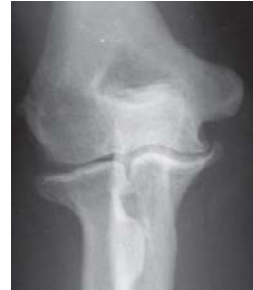- **Moving valgus stress test**
 - Pain 70° to 120° flexion range as the elbow is rapidly extended
- **Milking maneuver**



Chen FS, JAAOS, 2001.

Imaging


- **AP/Lateral Xray**
- **Fluoroscopy**
 - Stress views
- **MRI**
 - 92% sensitive, 100% specific for UCL tears
- **MR Arthrography**



Potter HG. CORR 2000;370:9-18.

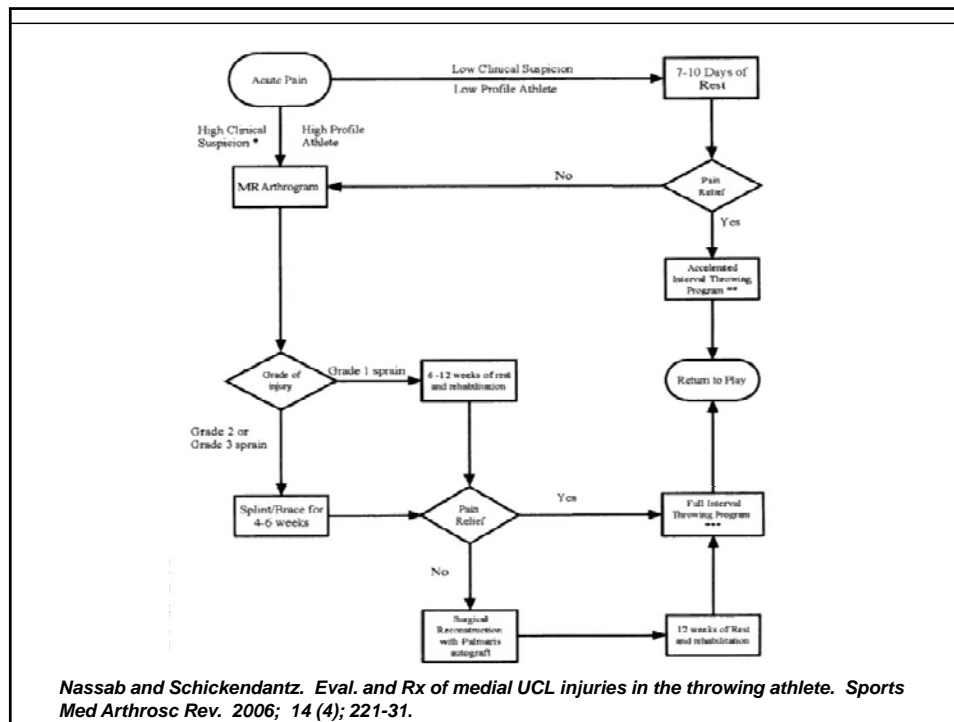
Treatment

- **TREATMENT CONSIDERATIONS**
 - career level
 - career potential
 - ability to participate in extensive rehabilitation
 - patient motivation
 - desire to continue throwing



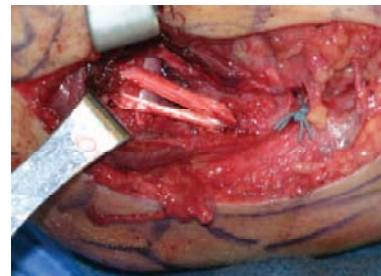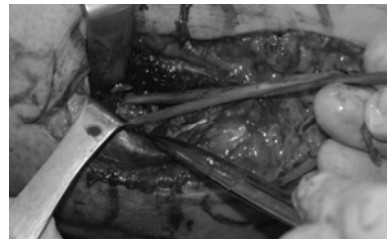
Sandy Koufax pitching for the Los Angeles Dodgers in the 1960s (photo, public domain)

Gaary EA, Potter HG, Altchek DW. AJR 1997;168:795-800.



Surgical Reconstruction of the MUCL

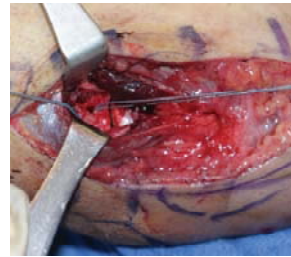
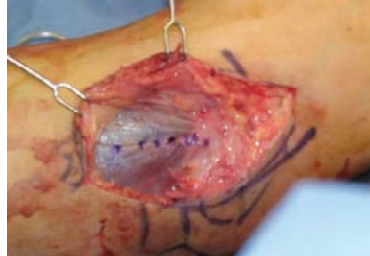- “Docking Technique”
 - Muscle splitting approach
 - Single inferior humeral tunnel with 2 small superior exiting tunnels
 - Place the tendon graft in bone tunnels; Simplify graft tensioning and improve fixation
 - 36 elite athletes
 - 92% returned to same activity level at 3.3 year follow-up



Rohrbough, JT, et al. MCL recon using the Docking Technique. AJSM. 2002. 30:4; 541-48

Reconstruction Results

- **Systematic review of all published reports of UCL reconstruction in overhead athletes.**
- **Average 83% of patients in all studies had an excellent result.**
- **UCL reconstruction has made return to previous or higher level of athletic participation in sports highly likely.**
- *Vitale, M. and Ahmad, C. The outcome of elbow ulnar collateral ligament reconstruction in overhead athletes. A systematic review. AJSM. 2008; 36 (6): 1193-1205.*



Distal Biceps Tendon Ruptures

Demographics

- Incidence of distal biceps rupture is 1.2 per 100,000 persons per year. Safran MR CORR, 2002
- Injuries tend to occur in the dominant elbow (86%) of men (93%) in their 40s, laborers. Morrey, BF JBJS 1985
- 7.5 times greater risk of distal biceps tendon ruptures in persons who smoke. Sutton KM, JAAOS, 2010

Demographics

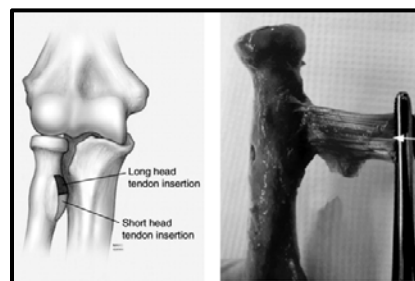
- Incidence of distal biceps rupture is 1.2 per 100,000 persons per year. Safran MR CORR, 2002
- Injuries tend to occur in the dominant elbow (86%) of men (93%) in their 40s, laborers. Morrey, BF JBJS 1985
- 7.5 times greater risk of distal biceps tendon ruptures in persons who smoke. Sutton KM, JAAOS, 2010

Demographics

- Incidence of distal biceps rupture is 1.2 per 100,000 persons per year. Safran MR CORR, 2002
- Injuries tend to occur in the dominant elbow (86%) of men (93%) in their 40s, laborers. Morrey, BF JBJS 1985
- 7.5 times greater risk of distal biceps tendon ruptures in persons who smoke. Sutton KM, JAAOS, 2010

Classification

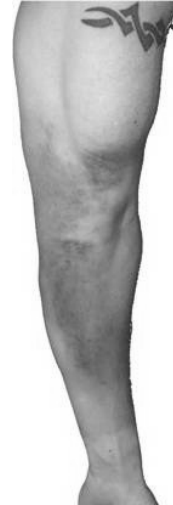1. Temporal – Acute vs. Chronic
2. Morphologic – Complete vs. Partial
3. Anatomic
 - Bone Attachment (Type I)
 - Intratendinous (Type II)
 - Musculotendinous Junction (Type III)



Athwal, et al. JHS 2007

History and Physical Exam

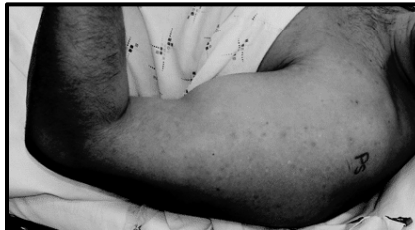- Rupture is frequently associated with a traumatic event (eccentric load)
 - A forceful extension
 - Lifting a heavy object
- Patients report a painful “pop” in the elbow.
- Ecchymosis of the elbow and medial forearm is common.



Sutton, KM, JAAOS 2010

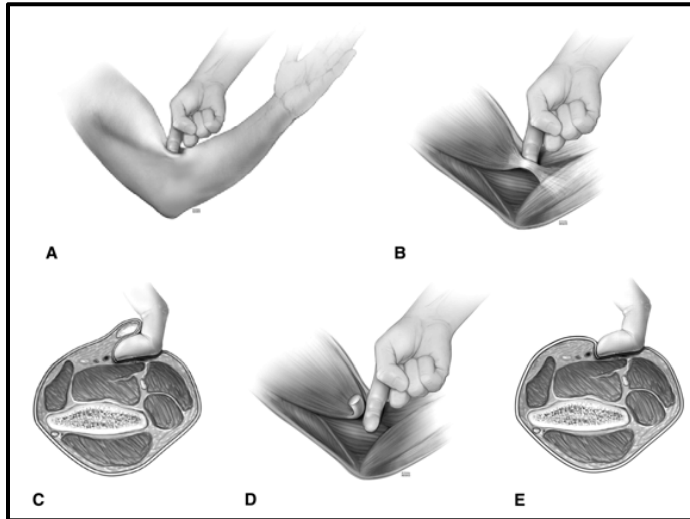
Physical Exam

- Patients with a complete biceps rupture present with:
 - A visible deformity with a “Popeye” muscle proximally
 - A palpable defect of the insertion
 - *Weakness of supination* and elbow flexion
 - Tendon can be palpable at, or proximal to, the antecubital fossa



Sutton, KM, JAAOS 2010

Examination: Hook test



O'Driscoll, SW et al. AJSM 2007

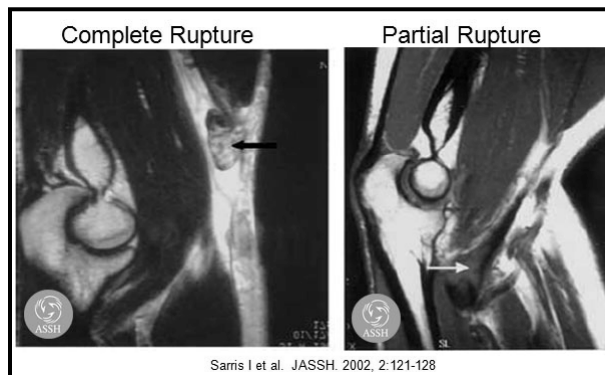
Examination: Hook test

		Sensitivity	Specificity
Complete			
	Hook Test	100%	100%
	MRI	98%	83%
Partial			
	Hook Test	75%	80%
	MRI	60%	98%

O'Driscoll, SW et al. AJSM 2007

Indications for MRI

- **Diagnosis is unclear**
- **Tear thought to be at myotendinous junction**
- **Evaluation of retraction in a chronic tear**
- **Suspected partial tendon rupture**



Non-operative Management

- **Low demand or medically infirm patients**
- **Without repair patients may have:**
 - **Activity related pain**
 - **Weakness, especially of power supination**
 - **Early fatigue of supination and flexion**

Operative Management

Rupture of the Distal Tendon of the Biceps Brachii

OPERATIVE VERSUS NON-OPERATIVE TREATMENT*

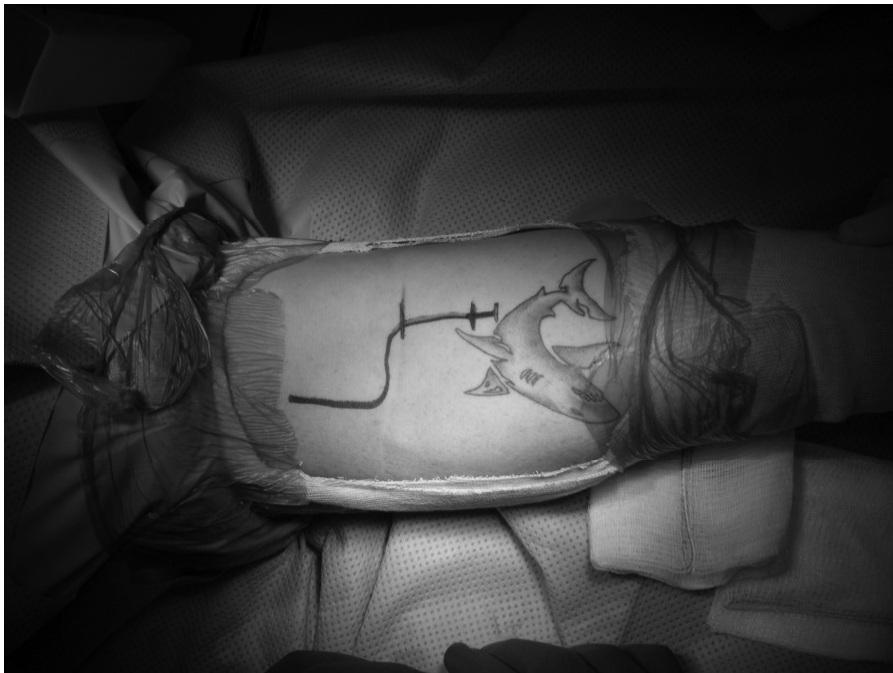BY BRUCE E. BAKER, M.D.[†], AND DAVID BIERWAGEN, R.P.T.[†], SYRACUSE, NEW YORK

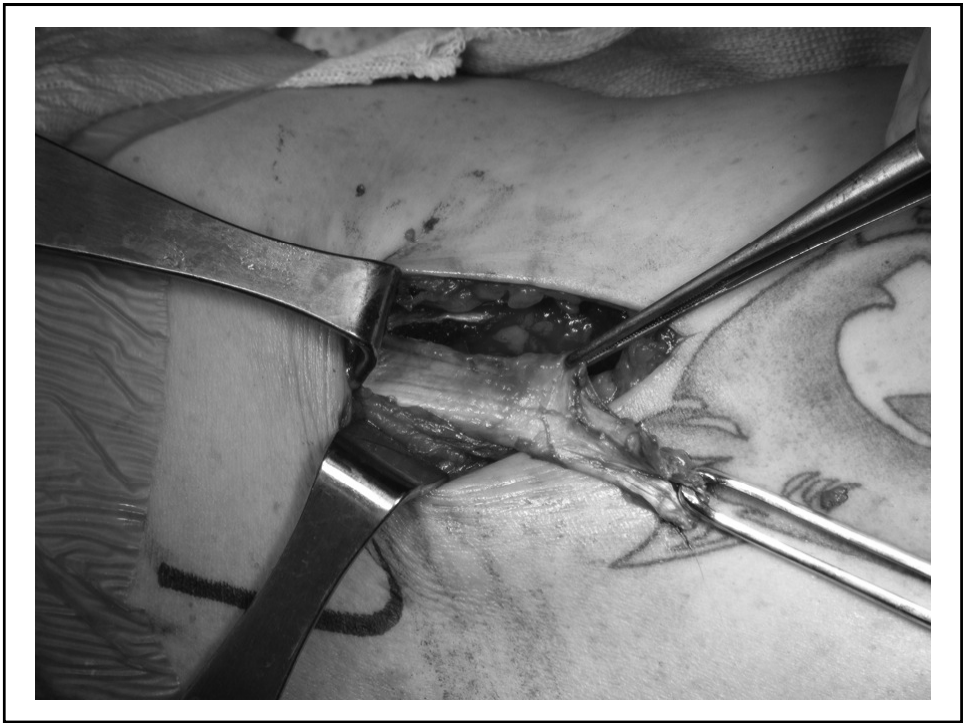
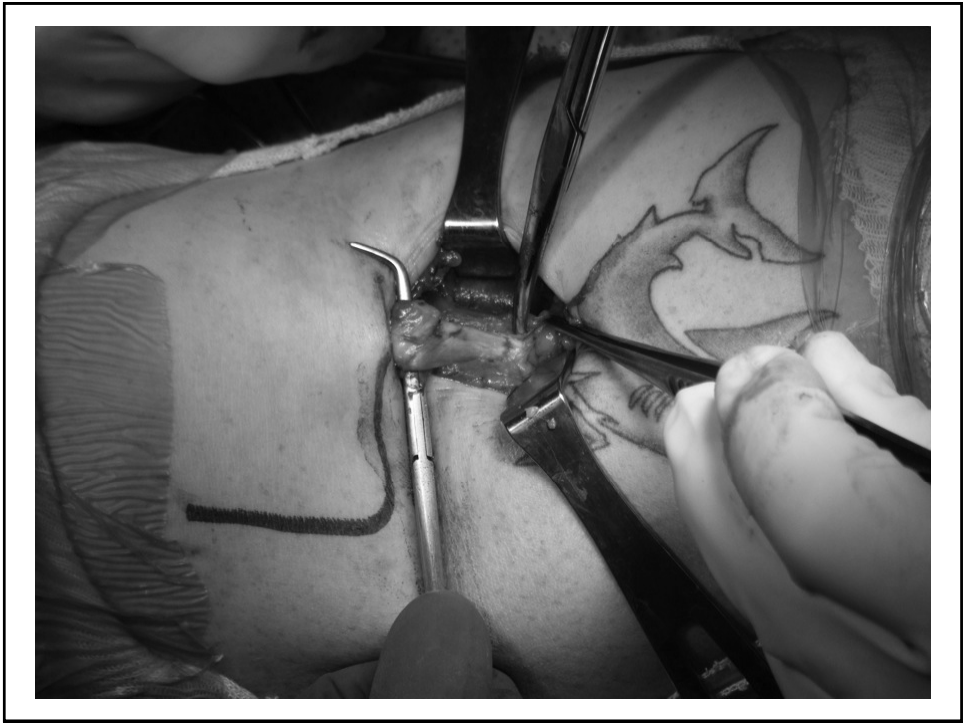*From the University Sports Medicine Center, Department of Orthopaedic Surgery,
State University of New York, Upstate Medical Center, Syracuse*

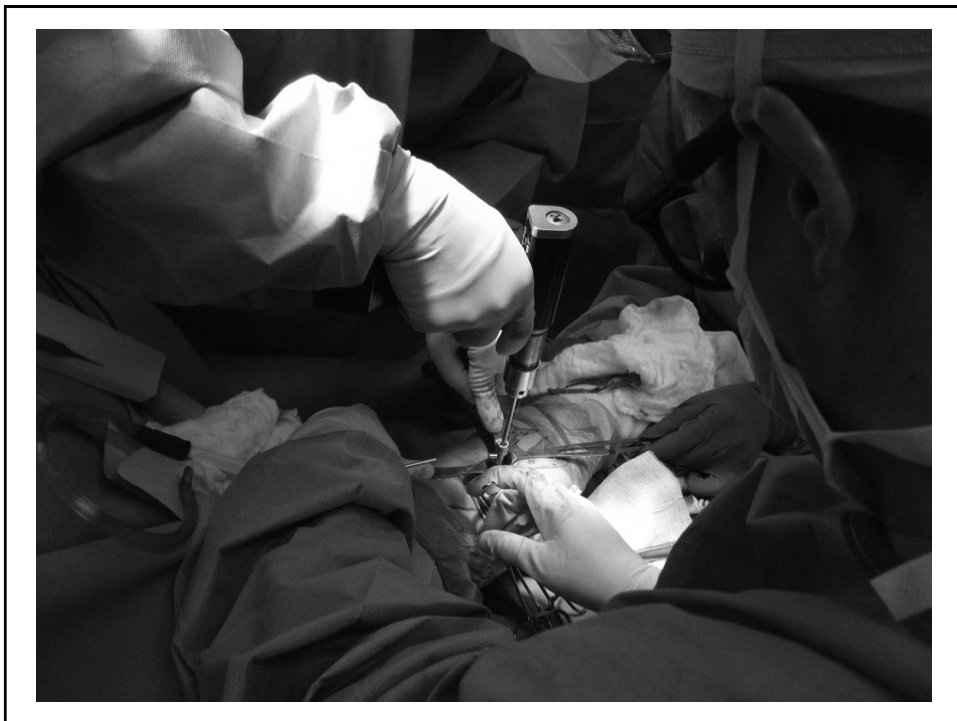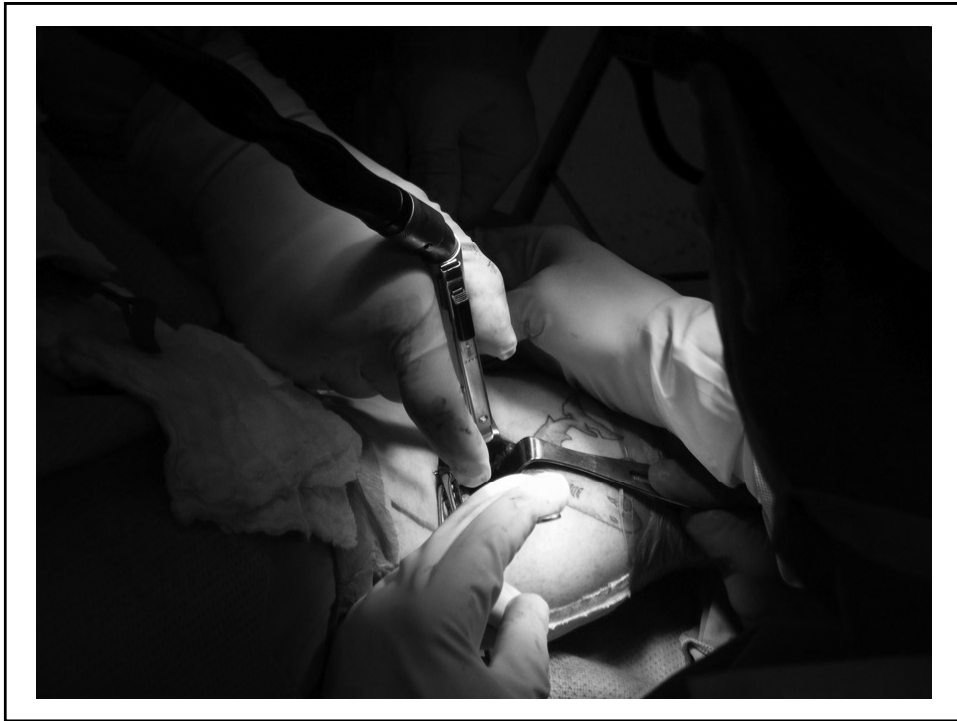JBJS 1985

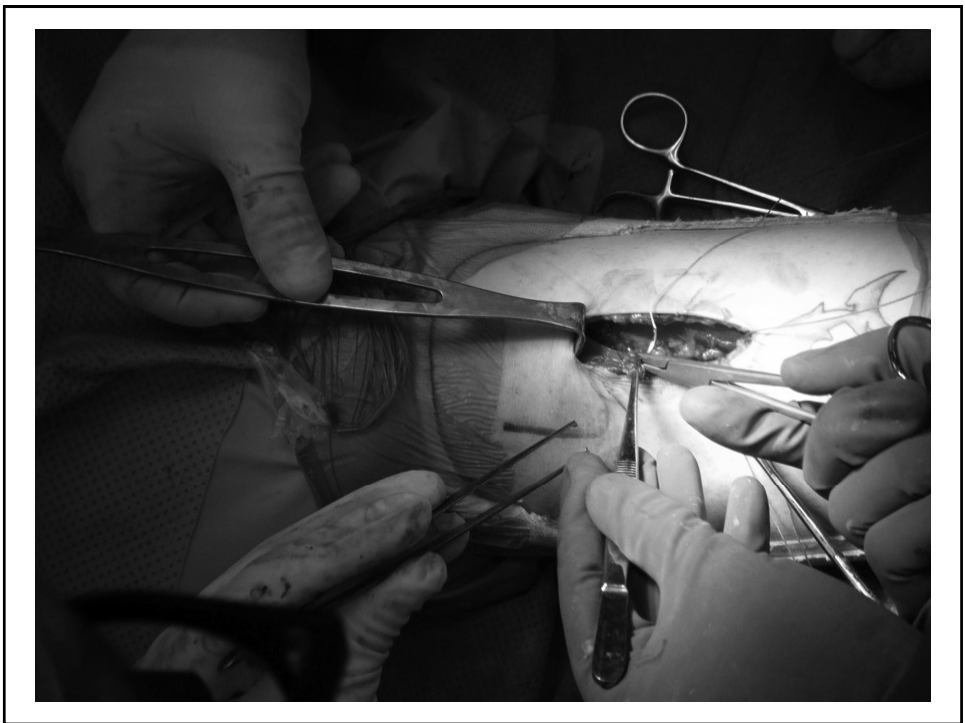
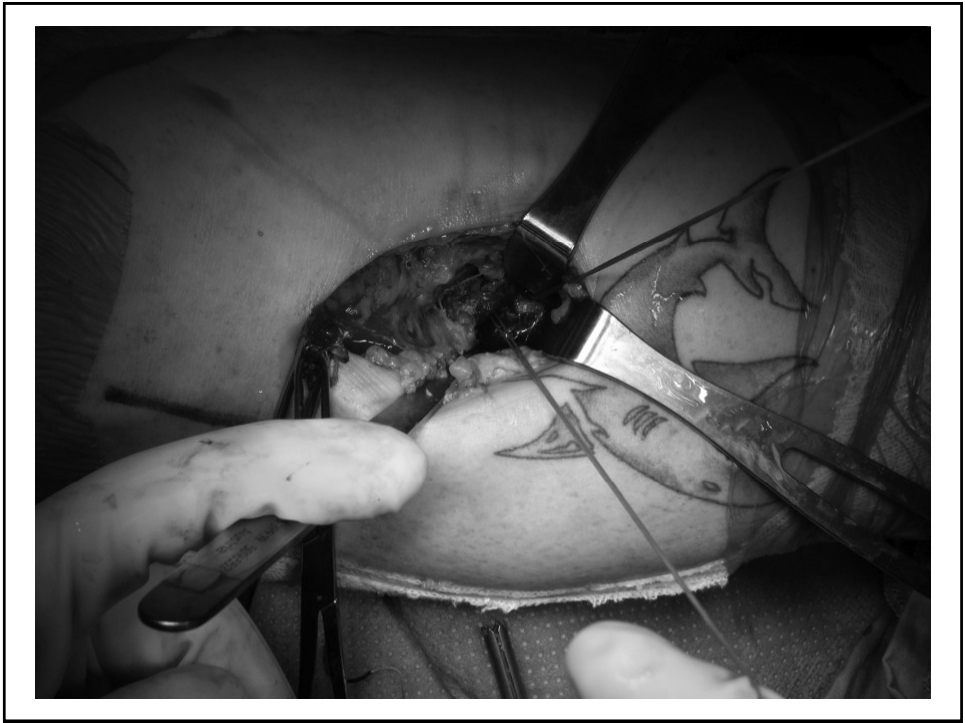▪ Operative Tx superior to non-op Tx in terms of restoring:

- Elbow flexion strength (30% improved)
- Supination strength (40% improved)
- Upper extremity endurance

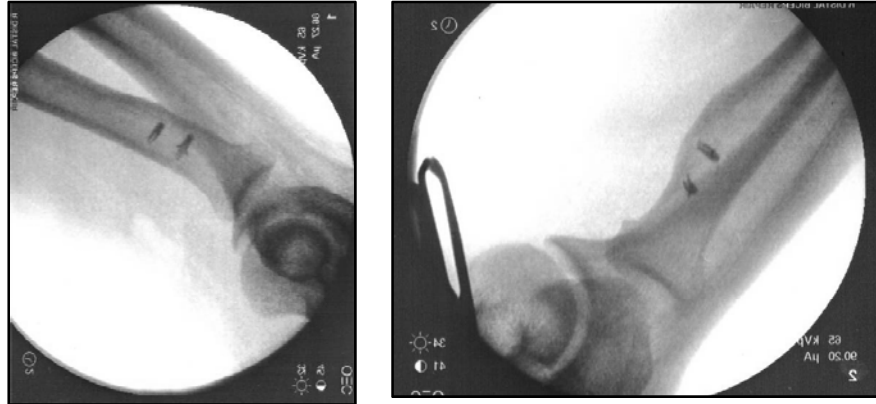








Post-op Xrays



Operative Management

- **Results**
 - **> 95% ROM return in flexion-extension and pronosupination.**
 - **Return of 97% of flexion and 95% supination strength.**
 - **Overall excellent functional outcomes in acute repairs.**
 - **Less predictable outcomes for patients treated with chronic injuries.**

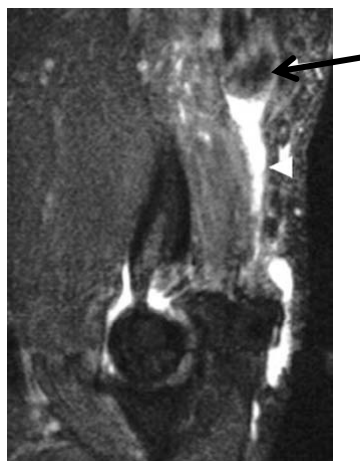King J, JAAOS, 2008.

- King J, JAAOS, 2008.**

Triceps Tendon Ruptures

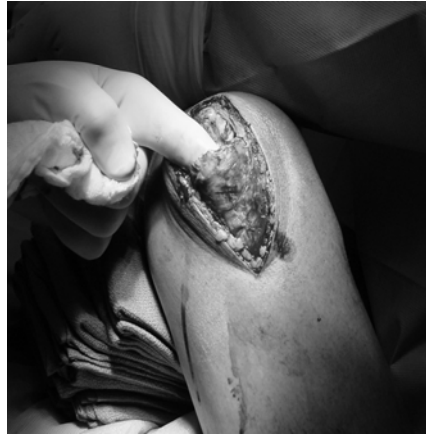Triceps Tendon Tears

- Rare injuries
- <1% of all tendon problems related to the upper extremity
- Seen in weight lifters with anabolic steroid use
- Local Factors:
 - Local corticosteroid injections
 - Attritional changes from degenerative arthritis
 - Olecranon bursitis
- Disruption occurs most commonly:
 - As a result of a FOOSH
 - Eccentric load
 - Can occur from direct trauma



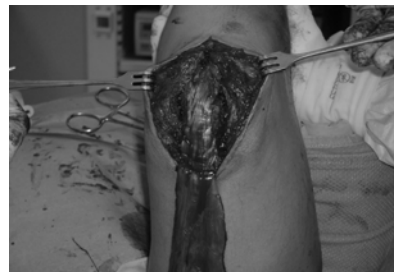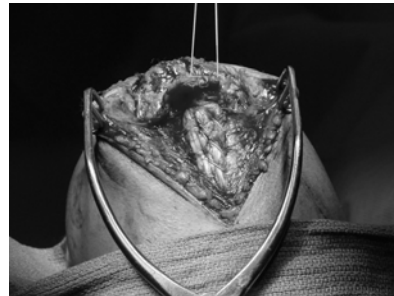
Presentation

- Pain and swelling over posterior elbow
- Eccymosis
- Palpable defect proximal to olecranon
 - Frequently not palpable due to swelling
- Inability to extend the elbow against gravity
- However extension is frequently preserved (50%)
 - Intact lateral expansion
 - Anconeus contribution



Triceps Tendon Tears

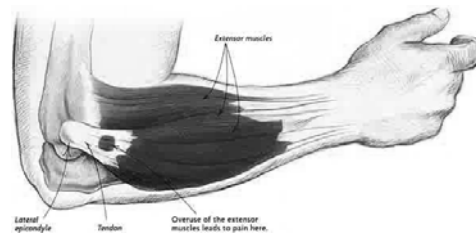
- Treatment:
 - Operative repair
 - Many different techniques
 - Suture, suture anchors, biotenodesis screws etc.
 - Chronic triceps avulsions:
 - May require allograft reconstruction to bridge defect



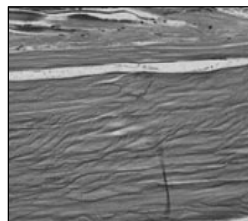
Lateral Epicondylitis “Tennis Elbow”

Lateral Epicondylitis

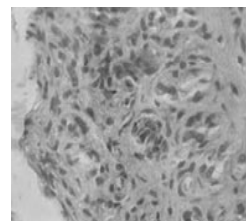
- Common extensor origin arises from the lateral epicondyle
- ECRB origin is deepest & superior
- Microscopically: invasion by fibroblasts and vascular granulation tissue
 - ‘Angiofibroblastic Hyperplasia’
 - Absence of acute & chronic inflammatory cells



Stemcelldoc



Normal Muscle

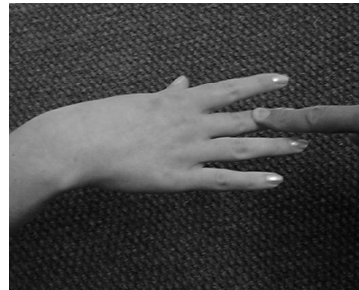

Angiofibroblastic Hyperplasia

Calfee RP, JAAOS, 2008.

Lateral Epicondylitis

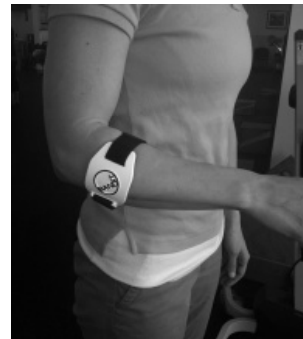- **Presentation**
 - Lateral elbow pain which may radiate to forearm
 - History of repetitive use of extensor tendons or repetitive trauma.
 - Waxing and waning of symptoms related to activity level.
- **Physical Exam**
 - Maximal tenderness just distal lateral epicondyle
 - Pain with passive wrist & finger flexion with the elbow extended
 - Pain with resisted wrist & finger extension with elbow extended



Nirschl, Clinical Sports Medicine, 2003.

Lateral Epicondylitis - Treatment

- **NON OPERATIVE TREATMENT**
 - Success rate up to 90%
 - Rest +/- icing.
 - PT/stretching
 - Counterforce Braces
 - Corticosteroid injections
 - PRP: 81% improvement at 6 months.



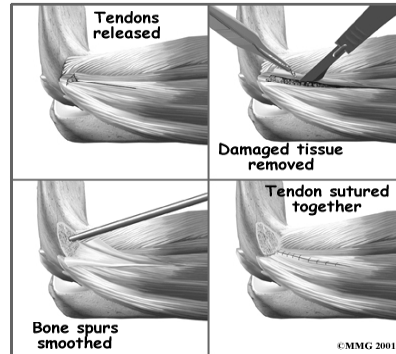
Athletico Physical Therapy, 2013

Mishra, A, *AJSM*, 2006

Lateral Epicondylitis - Treatment

- **OPERATIVE TREATMENT**

- Success rate > 85% of patients
- Excision of degenerated tendons + repair
- Arthroscopic release
- Percutaneous release



Scher, DL, Orthopaedics, 2009.

Conclusions

- Elbow injuries can be devastating problems.
- Most concerning for overhead and throwing athletes.
- When necessary, immobilization should be minimized to prevent loss of ROM.
- Acute tendon repairs produce overall good outcomes.
- Full recovery is less predictable in chronic injuries.



Lower Extremity Injuries in the Athlete

Michael Jonesco, DO
Assistant Clinical Professor,
Department of Internal Medicine
Team Physician, Capital University
Head Physician, Columbus Clippers
Division of Sports Medicine
The Ohio State University Wexner Medical Center

Outline and Objectives

- **Case 1. Hip**
 - Groin pain in hockey player
 - Clinical Pearl: Stress Fractures
- **Case 2. Knee**
 - Acute knee pain in triathlete
 - Clinical Pearl: Knee effusions
- **Case 3. Lower Leg**
 - Exertional Shin Pain in Runner
- **Case 4. Foot/Ankle**
 - Tennis player with lateral foot pain
 - Clinical Pearl: Pediatric Athletes



Case 1

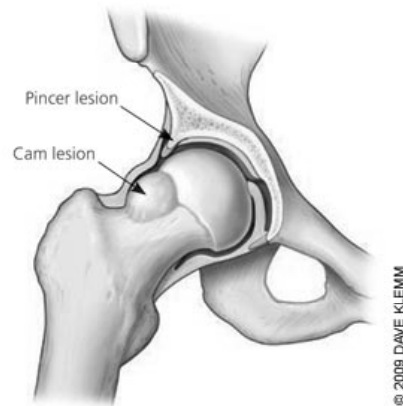
- 29 year old recreational hockey goalie presents with anterior hip pain for 3 months. Denies trauma or associated MOI. Pain exacerbated by flexion, relieved with rest. Describes occasional “clicking” or “popping”. Has taken NSAID with some relief, but pain returns whenever he resumes hockey activity.

Differential Diagnosis

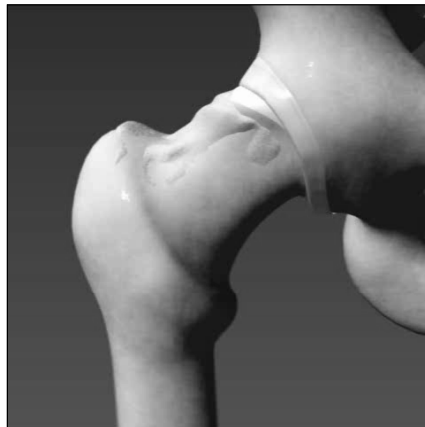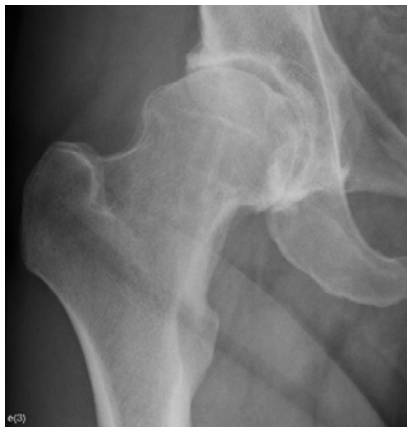- | | |
|----------------------------------|---------------------------------|
| • Glut tendonitis | • Stress Fracture Hip |
| • Piriformis syndrome | • Greater Trochanteric Bursitis |
| • SI dysfunction | • Iliopsoas tendonitis |
| • Hip osteoarthritis | • Hip Flexor strain |
| • Radicular Leg pain | • Hip Pointer |
| • Femoral acetabular impingement | • ITB syndrome of Hip |
| • Acetabular Labral Tear | • Osteitis Pubis |
| • Adductor Syndrome | • Athletic Pubalgia |
| • Meralgia paresthetica | |

Femoral Acetabular Impingement

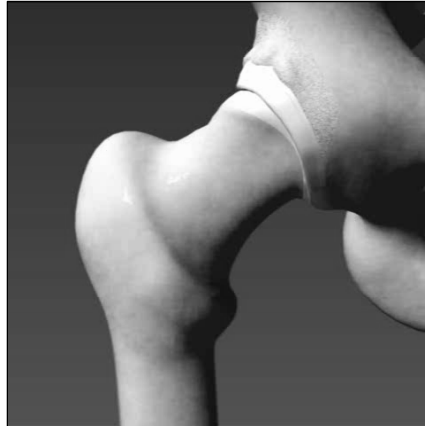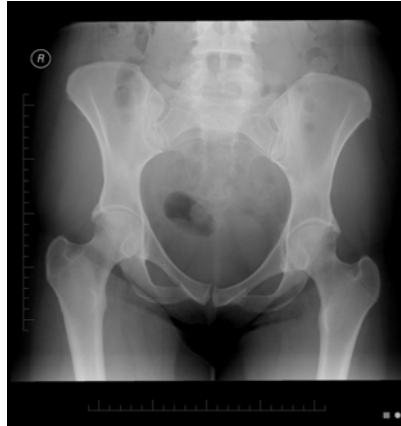- “Hip Impingement”
- Abnormal contact between proximal femur and acetabular rim during flexion of the hip
 - CAM: Prominence of femoral head
 - Pincer: Overcoverage of acetabulum
- Can lead to Labral Tears → premature OA if left untreated



CAM



Pincer



FAI, Acetabular Labral Tear

▪ History

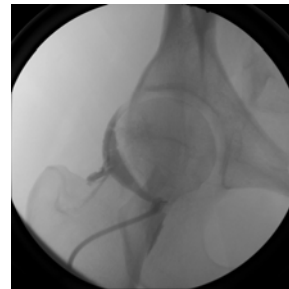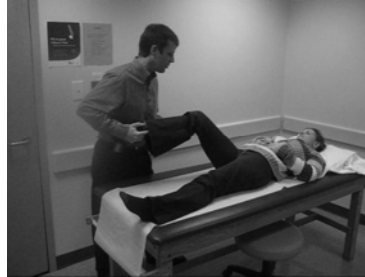- Insidious groin pain (FAI) vs singular event (labrum?)
- 2nd-6th decades
- Pivoting/twisting
- Pain with activity
 - flexion sports
- Sitting painful
 - Car rides, class, work



- *Pain worse over time – true FAI generally does not resolve spontaneously*

FAI/Labral Tear

- Exam
 - “C” sign
 - +FADIR
 - + “Scour” or Circumduction
- Eval/Imaging
 - Xray AP, Frog Leg
 - MRI
 - More sensitive w/ arthrography for LABRAL TEAR
 - (increases sens from 30%-90%)
 - Specificity w/ bupivacaine injection up to 90% for IA disorder



FAI/Labral Tear, Treatment

- Conservative Tx
 - Few (if any) studies done on long-term conservative management
- Core Strengthening
- Positional avoidance
 - Modify sport
- NSAIDs
- Injections
 - Blind, US, or Fluoro-guided
- Elliptical
 - Less hip flexion, impact vs running



FAI/Labral Tear, Treatment

- **Surgical studies limited**
 - Most with short term follow-up
- **Surgical treatment**
 - Addresses bony abnormalities (+ labrum)
 - 80-90 short term improvement (pain)
 - Moderate evidence may prevent OA
- **People w/ OA had worse surgical outcomes**

Ng et al, AJSM, 2010

Stress Fracture Hip

- **Considered in any runner w/ hip pain, thigh, buttock, or groin pain**
- **Signs and Symptoms**
 - Pain increases w/ weight bearing
 - Limitations in strength, ROM (esp IR)
- **Evaluation/Imaging**
 - Xray typically negative
 - MRI, low index of suspicion
- **Treatment**
 - Depends on WHERE the bony edema/stress rxn



Stress Fracture Hip

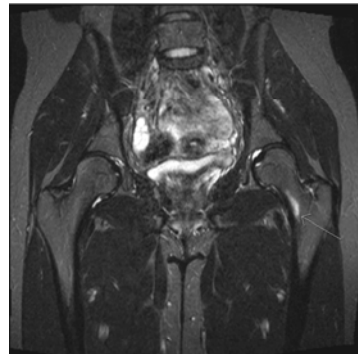
COMPRESSION

- >younger
- Inferior medial margin
- No Fracture line
- Treatment
 - Conservative
 - NWB initially (crutches)
 - Crutches and progressive wt bearing over 3 m
 - Gradual RTP

Stress Fracture Hip

COMPRESSION

- >younger
- Inferior medial margin
- No Fracture line
- Treatment
 - Conservative
 - NWB initially (crutches)
 - Crutches and progressive wt bearing over 3 m
 - Gradual RTP



Stress Fracture Hip

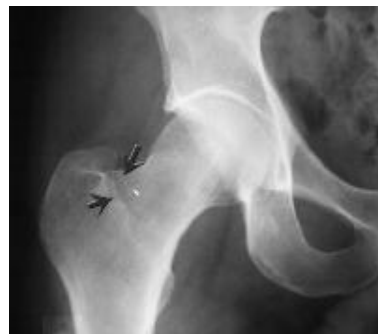TENSION

- Older
- Superior neck
- Treatment
 - Prompt Orthopedic referral

Stress Fracture Hip

TENSION

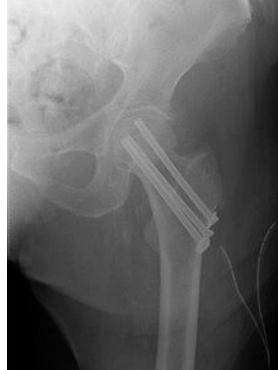- Older
- Superior neck
- Treatment
 - Prompt Orthopedic referral



Stress Fracture Hip

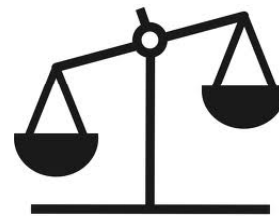TENSION

- Older
- Superior neck
- Treatment
 - Prompt Orthopedic referral



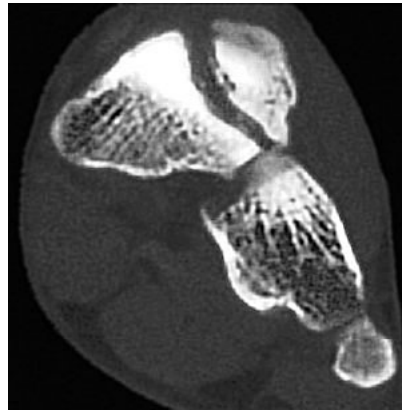
Clinical Pearls: Stress Fractures*

- **Imbalance in bony formation and bony breakdown**
 - Inadequate remodeling
 - Osteoclasts > Osteoblast
- **History**
 - Training, Shoes, Diet & Nutrition, Injury history
- **Imaging**
 - Xray typically negative, esp in first 3 wks or so
 - MRI most specific, sensitive
- **Treatment**
 - Generally rest
 - Be aware of high risk stress fractures!



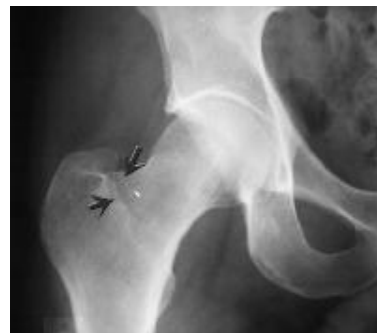High Risk Stress Fractures

- Navicular
- Hip, Tension-sided
- Medial Malleolus
- Base of 5th MT
- Sesamoid



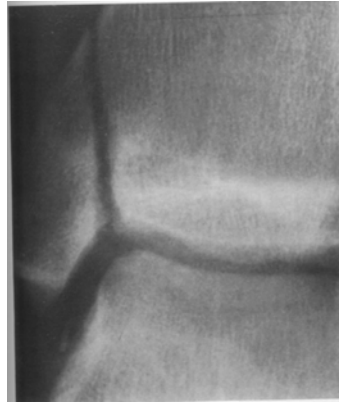High Risk Stress Fractures

- Navicular
- Hip, Tension-sided
- Medial Malleolus
- Base of 5th MT
- Sesamoid



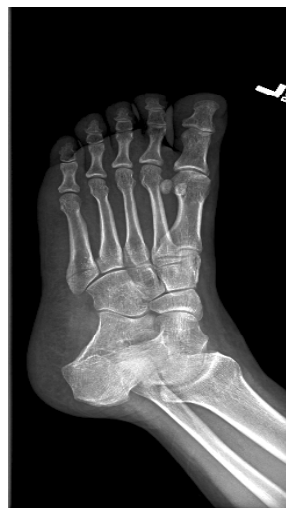High Risk Stress Fractures

- Navicular
- Hip, Tension-sided
- Medial Malleolus
- Base of 5th MT
- Sesamoid



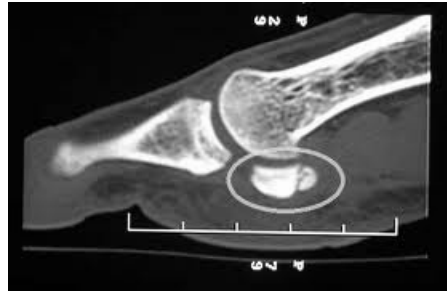High Risk Stress Fractures

- Navicular
- Hip, Tension-sided
- Medial Malleolus
- Base of 5th MT
- Sesamoid



High Risk Stress Fractures

- Navicular
- Hip, Tension-sided
- Medial Malleolus
- Base of 5th MT
- Sesamoid



Case 1 Follow Up

- Exam, xrays suggestive of FAI
- PT, NSAID
- At 6 weeks, pain had improved 80%
 - Returned to sport, symptoms returned
- Intra-articular injection (kenalog+lidocaine) in office
- Now 6 months out and still playing hockey
 - Less goalie
- Aware of increased risk of degeneration/OA



Case 2

- 44 yr old biker presents to your clinic with right lateral knee pain. He has been training for triathlon (run, bike, swim). Pain increases when running downhill and crossing right leg over left knee. Denies swelling, mechanical symptoms.
- Exam reveals *NO effusion*, FROM, full strength. There is ttp posterior to LCL.

Differential Dx: Knee Injuries in the Athlete

ACUTE

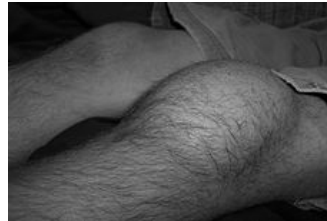- Ligamentous
 - ACL, PCL
 - MCL, LCL
- Cartilaginous
 - Chondral Injury
 - Meniscus Tear
- Patellar Dislocation
- Tendon Rupture
 - Quad, Patellar

SUBACUTE/CHRONIC

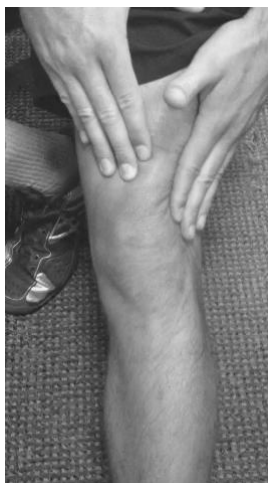- Patellar Tendonitis
- Pes Bursitis
- IT Band Syndrome
- Patellofemoral Syndrome
- Quad tendonitis
- Popliteal Tendonitis

Clinical Pearls: Knee Effusion*

- Aspiration aids examination!
- Sweep test*
- Red or yellow?
 - Hemarthrosis in athlete?
 - Anterior cruciate
 - Patellar Dislocation
 - Tibial Plateau Fracture
 - Straw colored
 - Meniscus, chondral injury
- Effusion warrants MRI!
 - Indicative of intra-articular damage
- Don't be fooled
 - Pre or suprapatellar bursitis vs effusion

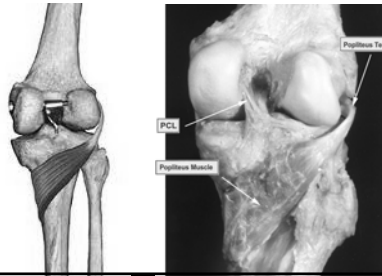


Knee Effusion: Sweep Test



Case 2: Follow up

- Diagnosed Popliteal Tendonitis
- Down-hill hiking, running
- > 15-30 flexion
- Figure 4 exam
- “Shoe Kick-off” Test
- Tx: conservative measures
 - Rest or activity modification
 - Ice
 - Bracing (mixed results)
 - Shoe wear
 - Case by case
 - Anti-inflammatory
 - PO, Topical NSAID vs Injection



Case 3



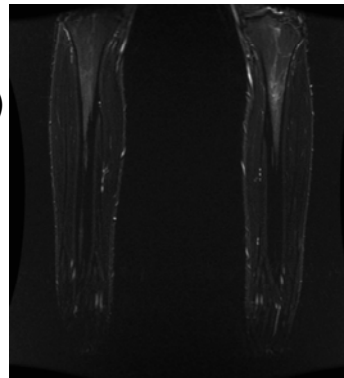
- 20 y/o female runner presents with bilateral lower extremity pain. She localizes pain diffusely over anterior shins. It is aggravated by running and relieved with rest. NSAIDs have minimal benefit. Despite 1 month of rest she is unable to return to running without return of symptoms.

MTSS or “Shin Splints”

- Misnomer: shin splints, periostitis
- Newer evidence suggests pain related to bony overload
- Continuum w/ stress fracture?
- Exam
 - *Diffuse TTP (vs isolated)*, middle/distal 1/3
- Imaging/Eval
 - Xray neg
 - MRI or bone scan reasonable if competitive athlete; r/o stress fx
- Treatment
 - Nsaids, RICE, Modify shoe wear (orthotic)
 - Posterior chain stretching
 - Cut mileage ~50% and gradually return <10%/wk , cross-train
 - AS PAIN ALLOWS!

Tibial Stress Fracture

- Posterior Medial Tibial Pain
 - Running→walking→rest→night
- Exam
 - More localized
 - Tuning Fork (away from sight)
- Imaging? If needed
 - Xray neg <3 wks (rest!)
 - Bone Scan vs MRI
- Treatment
 - Rest
 - Pneumatic Boots
 - Non-wt bearing; crutches (if needed)



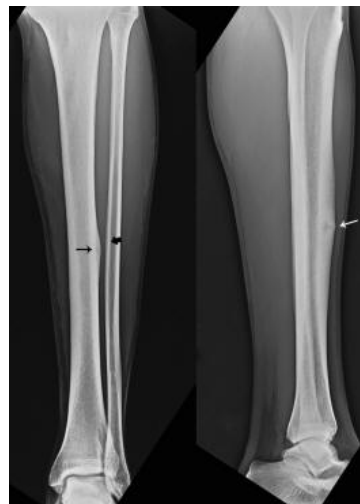Beware...

Anterior Mid Tibia

- **Tension sided**
 - High risk for non-union and complete fx
- **Jumping Athlete**
- **“Dreaded Black Line”**
- **Aggressive Conservative Tx**
 - NWB (+/- cast/boot) x 6-8 wks
 - If fails→ Ortho for IM rod

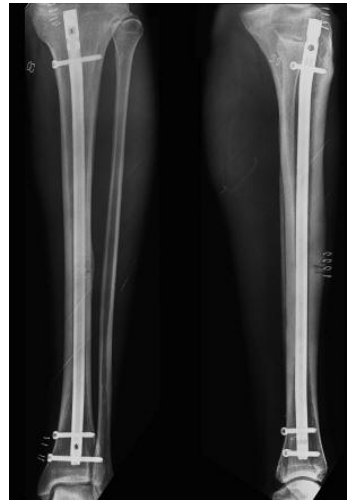Anterior Mid Tibia

- **Tension sided**
 - High risk for non-union and complete fx
- **Jumping Athlete**
- **“Dreaded Black Line”**
- **Aggressive Conservative Tx**
 - NWB (+/- cast/boot) x 6-8 wks
 - If fails→ Ortho for IM rod



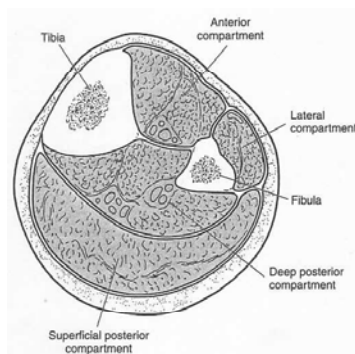
Anterior Mid Tibia

- **Tension sided**
 - High risk for non-union and complete fx
- **Jumping Athlete**
- **“Dreaded Black Line”**
- **Aggressive Conservative Tx**
 - NWB (+/- cast/boot) x 6-8 wks
 - If fails → Ortho for IM rod



Exertional Compartment Syndrome (ECS)

- **Dynamic Exercise**
 - Elevated interstitial pressures
 - Closed fascial compartments
- **Presents as ischemia pain**
 - (microvascular compromise)
 - ~30% chronic leg pain! (*Edwards*)
 - Boy=girl, common b/l
 - Runners>>bikers

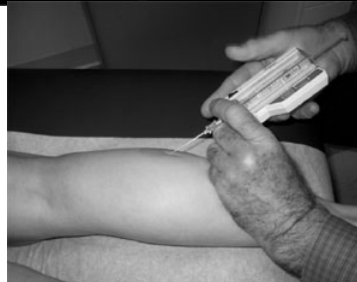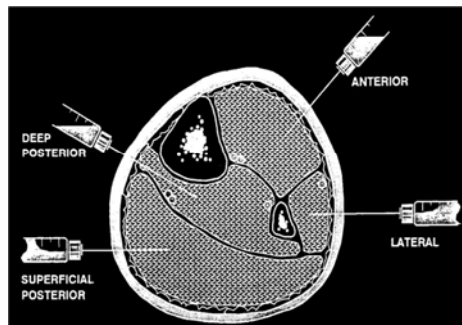


ECS: H&P

- **Crescendo-Decrescendo • Exam**
 - “Cramping”, paresthesias, weakness
 - Escalates w/ activity
 - Stops quickly w/ rest
 - Neuro findings?
- **Normal**
- **Muscle herniations (40%)**
- **Normal at rest...so exercise the patient!**
 - Rigid
 - Defects
 - Tender w/ passive motions

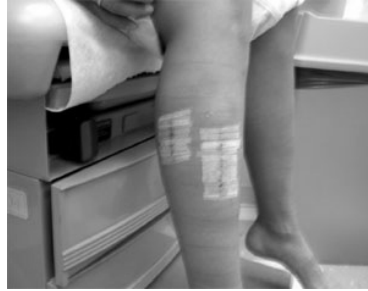ECS: Imaging & Evaluation

- **Xray/MRI**
 - Rule out other pathology
- **Evaluation/Imaging**
 - **Compartment testing**
 - Intra-compartmental pressure
 - Rest, 1 min, 5 min
 - **Confirmatory test**
 - >15, >30, > 20 mm Hg



ECS: Treatment

- **Rest (atrophy)**
- **Compression socks**
- **Switch Sport**
 - **Run→biking?**
- **Surgery: Fasciotomy**
 - **90% RTP successfully**



Case 3 Follow-up

- **Pt sent for compartment testing**
 - **Anterior and Lateral Pressures >60 mm Hg**
- **Referred for fasciotomy**
 - **Anterior and Lateral, laparoscopic**
- **Returned to sport 3 m later**
- **Competing at previous level at 6 months w/o complaint**



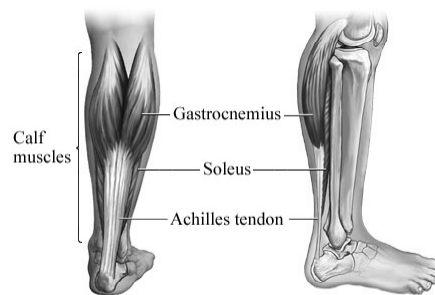Case 4

- **12 year old football and tennis player complains of lateral foot pain. He describes several weeks of symptoms that acutely worsened following a 2 day tennis tournament. Pain worsens w/ walking and he walks with a limp. Improves with rest and ibuprofen (400 mg PO tid).**



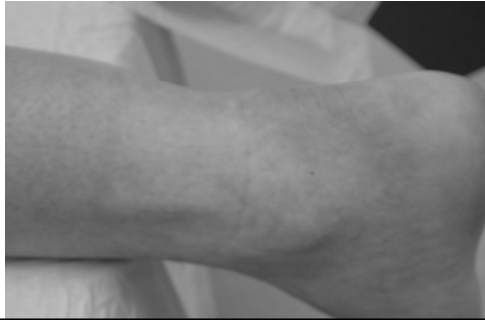Achilles Rupture

- **Largest, strongest tendon in the body**
- **Subjected to up to 10x body wt during activity**
- **Begins at junction of gastrocnemius and soleus tendons in middle of calf**
- **Typically 3 to 11 cm in length**



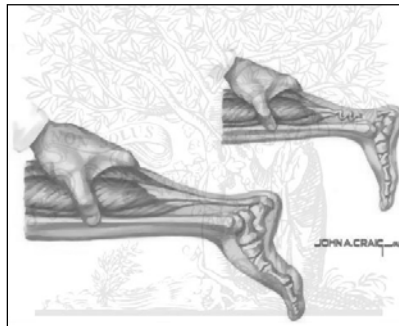
Achilles Rupture

- Antecedent tendinitis/tendinosis in 15%
- 75% of sports-related ruptures happen in patients between 30-50 years of age.
- Most ruptures occur in watershed area 2-6cm proximal to the calcaneal insertion.



Achilles Rupture

- History & Exam
 - “Kicked in the leg”
 - Mechanism
 - Eccentric loading (running backwards in tennis)
 - Sudden unexpected dorsiflexion of ankle
- Physical Exam
 - Palpable defect
 - Thompson Test +
 - Bruising/Swelling
 - Weakness with plantar flexion

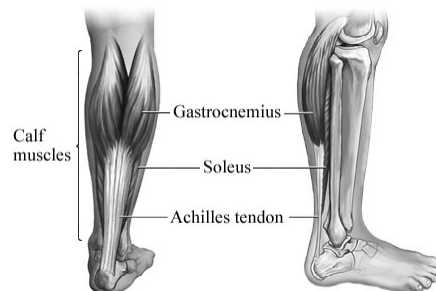

Achilles Rupture

- Management depends on physician and patient preference
- Surgery treatment of choice for athletes, young patients and delayed rupture
- Acute rupture in non-athletes can be treated nonoperatively
- Return to sport ~9 m regardless

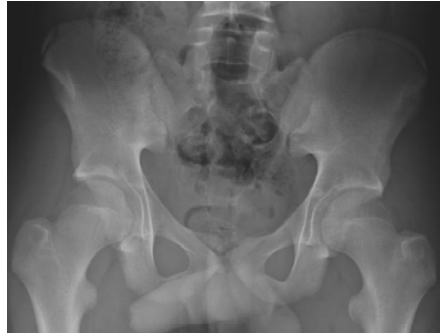Gastrocnemius Tear

- “Tennis Leg”
- Tear of gastroc fibers, typically medial head
 - Pain isolates to muscle belly
- Often presents like achilles rupture
- Exam: Negative Thompson, No defect
- Boot w/ wedges, WB as tolerated
- Early physical therapy



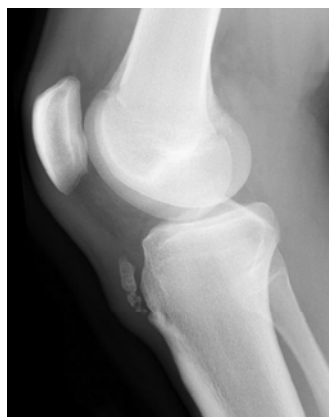Clinical Pearls: Pediatric Athletes Common Lower Extremity Apophyseal Injuries

- **Hip**
 - **ASIS, Iliac crest**
- **Knee:**
 - **Osgood Schlatter**
 - **Sinding-Larsen-Johansson**
- **Foot**
 - **Sever's**
 - **Iselin's**



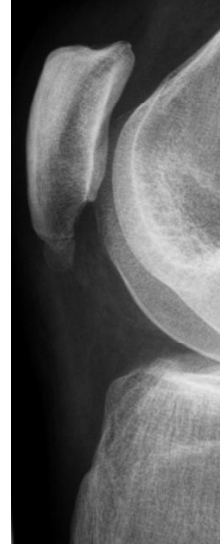
Clinical Pearls: Pediatric Athletes Common Lower Extremity Apophyseal Injuries

- **Hip**
 - **ASIS, Iliac crest**
- **Knee:**
 - **Osgood Schlatter**
 - **Sinding-Larsen-Johansson**
- **Foot**
 - **Sever's**
 - **Iselin's**



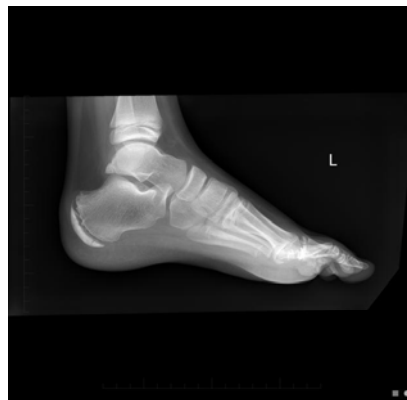Clinical Pearls: Pediatric Athletes Common Lower Extremity Apophyseal Injuries

- **Hip**
 - **ASIS, Iliac crest**
- **Knee:**
 - **Osgood Schlatter**
 - **Sinding-Larsen-Johansson**
- **Foot**
 - **Sever's**
 - **Iselin's**



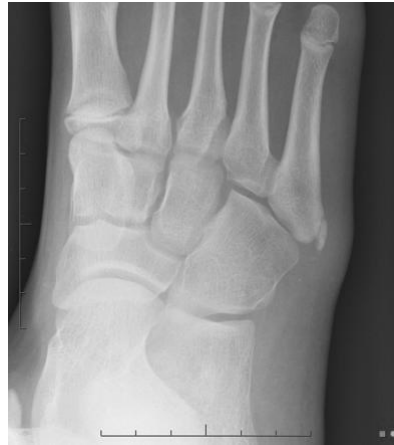Clinical Pearls: Pediatric Athletes Common Lower Extremity Apophyseal Injuries

- **Hip**
 - **ASIS, Iliac crest**
- **Knee:**
 - **Osgood Schlatter**
 - **Sinding-Larsen-Johansson**
- **Foot**
 - **Sever's**
 - **Iselin's**



Clinical Pearls: Pediatric Athletes Common Lower Extremity Apophyseal Injuries

- **Hip**
 - ASIS, Iliac crest
- **Knee:**
 - Osgood Schlatter
 - Sinding-Larsen-Johansson
- **Foot**
 - Sever's
 - Iselin's



Case 4: Follow-up

- Pt w/ point ttp base of 5th MT
- Xray:
 - Radiolucency parallel!
- Iselin Disease
 - Placed in short pneumatic boot
 - x 2 wks
 - 23 h/day, posterior chain stretching
 - Modified shoe wear
 - Gradual RTP
 - NSAIDs PRN if tolerated

