

Management of Delirium

Lauren Southerland, MD
Assistant Professor
Department of Emergency Medicine
The Ohio State University Wexner Medical Center

Lecture Objectives:

- Review the diagnosis of delirium
- Review screening tools for delirium
- Discuss different causes and treatments of delirium
- Discuss outcomes of delirium

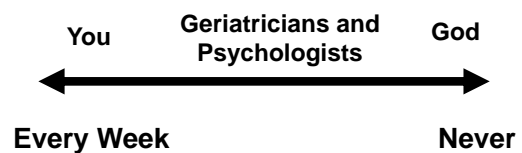
Metabolic Encephalopathy

- 1) Acute change in mental status
- 2) Fluctuating course
- 3) Characterized by inattention
- 4) Reversible

Affects 1.5 million older adult ED patients annually
60-80% of ICU patients
Seen in at least 20% hospitalized older adults

Neufeld, KJ and Thomas C. Delirium: Definition, Epidemiology, and Diagnosis .
J Clin Neurophys 30(5) 2013

How often do you miss the diagnosis of delirium?





Case #1

Mrs. Q is an 87yo woman brought in by her son for 1 day of confusion.

Mrs. Q

- Awake, alert, oriented only to self, denies any complaints
- Constantly picking at the sheets, staring off, intermittently tries to get out of bed during the interview
- 145/69, 85, 35.4, 93% RA
 - Heart RRR
 - Lungs clear
 - Abdomen soft, NDNT
 - Moving all extremities equally well, can walk with her walker

Quick chart review...

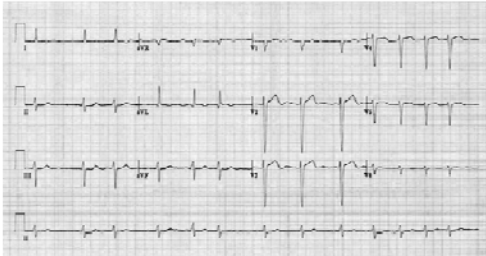
- **PMH:** HTN, HL, restless leg syndrome, UTIs
- **PSH:** hysterectomy
- **Meds:** ASA, Amlodipine, Losartan
- **Social History:** Lives with her son, normally able to dress and feed herself but not cook, clean, or drive.

I WATCH DEATH

| | |
|------------------|--|
| Infection | HIV, sepsis, Pneumonia |
| Withdrawal | Alcohol, barbiturate, sedative-hypnotic |
| Acute metabolic | Acidosis, alkalosis, electrolyte disturbance, hepatic failure, renal failure |
| Trauma | Closed-head injury, heat stroke, postoperative, severe burns |
| CNS pathology | Abscess, hemorrhage, hydrocephalus, subdural hematoma, Infection, seizures, stroke, tumors, metastases, vasculitis, Encephalitis, meningitis, syphilis |
| Hypoxia | Anemia, carbon monoxide poisoning, hypotension, Pulmonary or cardiac failure |
| Deficiencies | Vitamin B12, folate, niacin, thiamine |
| Endocrinopathies | Hyper/hypoadrenocorticism, hyper/hypoglycemia, Myxedema, hyperparathyroidism |
| Acute vascular | Hypertensive encephalopathy, stroke, arrhythmia, shock, ACS |
| Toxins or drugs | Prescription drugs, illicit drugs, pesticides, solvents |
| Heavy Metals | Lead, manganese, mercury |

Hospital Course

- CBC, BMP, Urinalysis, Chest X-ray, Head CT all within normal limits
- EKG with new onset atrial fibrillation, rate controlled



Mrs. Q

- Initial troponin 0.21, new atrial fibrillation
- Started heparin, admitted, cardiac cath the following day and stent placed x1.
Medications optimized and patient's mental status resolved. Discharged back home to live with her son.

Diagnosis of Delirium:

- Brief Confusion Assessment Method (CAM ICU)
- 1. Acute Change or Fluctuating course of mental status?
- 2. Inattention:
 1. S A V E A H A A R T
- 3. Altered level of consciousness (anything other than alert and calm, or a Richmond Agitation Sedation Scale of 0)

Ely EW et al. Evaluation of delirium in critically ill patients: validation of the Confusion Assessment Method for the Intensive Care Unit (CAM-ICU) Crit Care Med. 2001;29(7):1370-1379.

Brief Confusion Assessment Method (CAM ICU)

- Disorganized Thinking:
 1. Will a stone float on water?
 2. Are there fish in the sea?
 3. Does one pound weigh more than two?
 4. Can you use a hammer to pound a nail?
- Command: "Hold up this many fingers" (Hold up 2 fingers)
- "Now do the same thing with the other hand" OR
- "Add one more finger" (If patient unable to move both arms)

Diagnosis of Delirium:

- Other brief tests for inattention:
- serial sevens
- spelling WORLD backwards
- reciting months of the year backwards



Old Man
by Chonkhet Phanwichien

Case #2:

Mr. C is a 85yo man transferred to your ED from another ED for a bowel obstruction.

Mr. C

- He has soft 4 point restraints, a foley, IV, and NG tube. 155/73, 60 bpm, 36.4 temp, 18 RR, 95% RA
 - Heart RRR
 - Lungs clear
 - Abdomen distended, tympanic, but nontender
 - No focal neurological deficits.

Quick chart review...

- PMH: Alzheimer's dementia, diverticulitis s/p partial colectomy, myasthenia gravis, hyperlipidemia, and in situ prostate cancer currently being treated by watchful waiting.
- PSH: hernia repair x2 and partial colectomy
- Meds: aspirin, donepezil, finasteride, simvastatin, trazodone, pyridostigmine

Can you help with his agitation?

- A) 5mg haldol, 2mg ativan IV and admit him to surgery
- B) remove foley and NG and assign a sitter
- C) Intubate and sedate as he will need surgery anyway
- D) Have respiratory obtain baseline NIF and try scheduled low dose haldol and low dose morphine for pain, monitoring agitation and respiratory function.

Patient course:

- His mental status did better on haldol 1mg q6h and respiratory status stayed stable. Restraints removed
- Morphine 2mg q4h + 2mg q2h PRN given for pain
- Taken to the OR as non operative management was not resolving obstruction, and underwent small bowel resection x2 and lysis of adhesions.

Mr. C

- Post surgery developed aspiration pneumonitis and went into respiratory failure. Intubated and never able to be weaned from ventilator despite trach/peg. Family withdrew care and patient died one month post admission.





Neurotransmitters in Delirium:

- Acetylcholine deficiency: Normal aging leads to decrease in Ach in the brain, making them more sensitive to drugs, inflammation or other conditions that decreased Ach
- Serotonin dysregulation: excitatory neurotransmitter, decreased or dysregulated in delirium
- Dopamine increased: especially implicated in hyperactive delirium
- Gamma-aminobutyric acid (GABA) and Glutamate: decreased by hypnotics or sedatives which can precipitate delirium

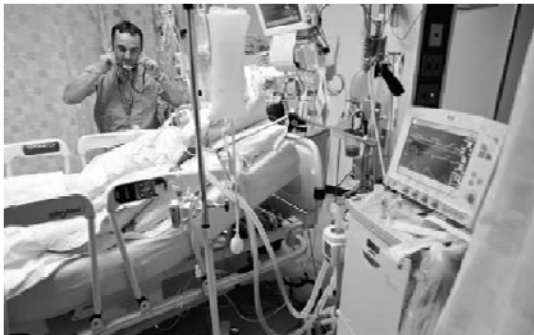Ali, MP et al. Insight into Delirium. Innov Clin Neurosci 2011; 8(10):25-34

Predisposing factors + Inciting event →
Delirium



Case #3:

Mr. B is an 87yo man in the SICU from total abdominal colectomy for large bowel obstruction caused by colon cancer.



Quick chart review...

- PMH: Dementia NOS, HTN, HL, chronic renal insufficiency, DM, new diagnosis of colon cancer
- PSH: total abdominal colectomy
- Meds: Lisinopril, HCTZ, ASA, Simvastatin, Omeprazole
- SH: lives with one of his 9 daughters, walks without difficulty and independent in his ADLs.

Mr. B is happy to see you...

- Nurses say he is increasingly agitated at night, although during the day with family he is redirectable
- Has had no pain meds for 3 days...
 - Dilaudid 0.5mg IV caused hypotension and apnea, morphine 4mg IV also caused hypotension
- No BM or flatus post op

Physical Exam

- Oriented only to self, answers simple questions and follows simple but no complex commands
- Denies pain, hunger or any complaints
- 125/70, hr 66, temp 37.1, 99% RA
- Heart RRR, lungs cta-b, neuro with motor and sensation intact
 - Abdomen diffusely tender, distended, no bowel sounds. Midline incision healing well

Why is Mr. B agitated at night?

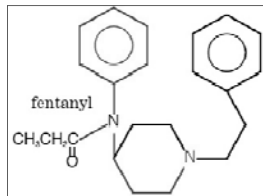
- A) The beds are uncomfortable
- B) He is in new surroundings and with his underlying dementia is having difficulty adjusting/reorienting
- C) Someone just stabbed his abdomen and took out his colon
- D) He has a post op ileus
- E) All of the above

Why is Mr. B agitated at night?

- A) The beds are uncomfortable
- B) He is in new surroundings and with his underlying dementia is having difficulty adjusting/re orienting
- C) Someone just stabbed his abdomen and took out his colon
- D) He has a post op ileus
- E) All of the above

What to do to help him?

- Low dose fentanyl drip for pain control
- Nasogastric tube and decompression
- Arranged for a family member there 24hr a day for orientation



Treatment of Delirium :

1. Remove inciting cause/stimulus
 - Pain control
 - Infection control
 - Tubes/lines/restraints
2. Reorient and redirect
 - Day/night cycle
 - Orient with familiar objects, faces, etc
3. Medications if needed
 - Avoid Beer's List meds!
 - Low dose antipsychotics

Treatment of Delirium :

1. Remove inciting cause/stimulus
 - Pain control
 - Infection control
 - Tubes/lines/restraints
2. Reorient and redirect
 - Day/night cycle
 - Orient with familiar objects, faces, etc
3. Medications if needed
 - Avoid Beer's List meds!
 - Low dose antipsychotics

Treatment of Delirium :

1. Remove inciting cause/stimulus
 - Pain control
 - Infection control
 - Tubes/lines/restraints
2. Reorient and redirect
 - Day/night cycle
 - Orient with familiar objects, faces, etc
3. Medications if needed
 - Avoid Beer's List meds!
 - Low dose antipsychotics

Case #4:

Mr. W is a 62yo man with oropharyngeal cancer who presents to the ED for presyncope after receiving his tube feeds this morning.



Mr. W:

- **Physical Exam:**
- Cachectic man in no apparent distress
- Abd soft, NDNT, BS+. PEG with small amount of drainage
- Lungs clear
- Heart RRR
- Rectal exam with soft brown stool, small anal fissure

Quick chart review...

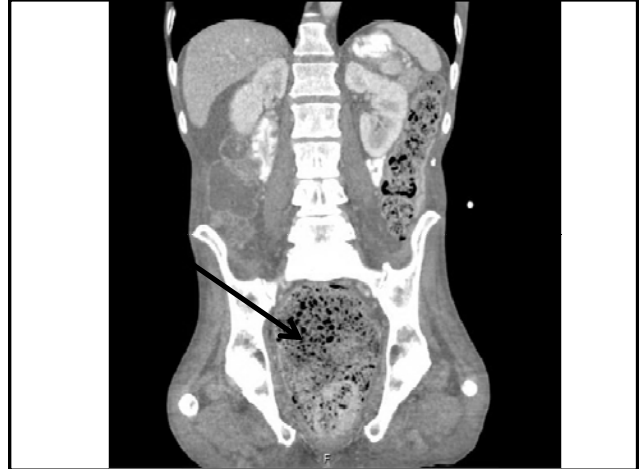
- **PMH:** COPD, metastatic oropharyngeal squamous cell cancer, glaucoma, chronic hep C, dysphagia, hx of polysubstance abuse
- **PSH:** modified radial neck dissection with lymphadenectomy, PEG placement
- **Meds:** Chemo, oxycodone, fluconazole oral, lisinopril, pantoprazole, latanoprost oph, brimonidine oph

ED course:

- **Initial vitals:** 103/59, HR 111, RR 16, SpO2 97%, temp 35
 - After 1L IVF: 110/79, HR 98
- Head CT, chest xray normal
- Cbc, chem panel, urinalysis, ekg and troponin unchanged.
- Mr. W placed in the observation unit overnight for light headedness

Hospital course:

- Mr. W remained fatigued, unable to get out of bed. He would lay in one spot not moving until forced too. He appeared asleep at any time unless spoken to. Minimal PO intake.
- The next morning his abdomen appeared slightly distended but he denied pain....



Hospital Course:

- Given polyethylene glycol, soapsuds enema, and senna
- Hospital note:
 - *"Diarrhea with occasional blood streaks overnight and this morning. Also had several bouts of emesis with streaks of feculent material.... Consulted General Surgery who successfully manually disimpacted stool with improvement in symptoms. Appreciate assistance."*

Why didn't Mr. W have abdominal pain?

- A) His home oxycodone masked any pain he would have.
- B) Changes in nerve function due to aging and chemo make him less likely to develop abdominal pain
- C) Hypoactive delirium

Why didn't Mr. W have abdominal pain?

- A) His home oxycodone masked any pain he would have.
- B) Changes in nerve function due to aging and chemo make him less likely to develop abdominal pain
- C) Hypoactive delirium

Hypoactive Delirium

- One of the three types of delirium (hyperactive, hypoactive, mixed)
- Over 50% of all delirium seen, and most frequent in older adult patients
- Presents with:
 - Excessive sleeping with little change in position
 - Poor appetite
 - Decreased interaction
 - Fluctuating mental status

Hypoactive Delirium

- Study of 300 ED patients >65y at Vanderbilt, all screened for delirium by CAM-ICU
- 8.3% had delirium, and of these 92% were of the hypoactive subtype, and 76% were not recognized as being delirious by the ED physicians.

• Han JH et al. Acad Emerg Med 2009, Mar; 16(3): 193-200

Case #5



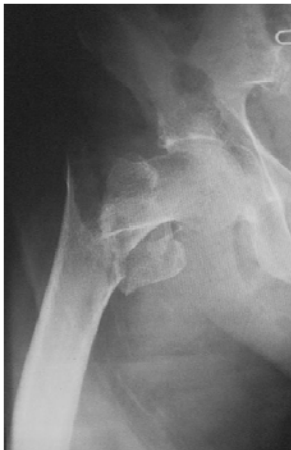Mrs. F is a 96yo woman brought in by her daughter for fall and hip deformity.

Physical Exam

- Only mumbles, does not answer questions, sleeping but arousable to voice. Denies pain
- 110/71, hr 70, temp 37.1, 95% RA
 - Heart RRR
 - Lungs clear
 - CN2-12, motor and sensation intact
 - RLE shortened and internally rotated, pulses intact

Quick chart review...

- PMH: Alzheimer's dementia, frequent UTIs
- PSH: appendectomy
- Meds: Donepezil, Macrochantin
- Social History: lives with her daughter, has 24hr home health caregivers. Previously able to ambulate without assistive devices.
- Exam: oriented only to self, follows simple commands, pleasantly demented



Hospital course

- Admitted to medicine with ortho following. It is Friday afternoon. Ortho places her on the OR schedule for Friday evening.
- Anesthesiologist refuses to clear her as he feels her age and underlying dementia make her not an operative candidate.
 - »Surgery is delayed...

Hospital course

- Reassessment on Monday...
 - Patient not eating or drinking well
 - Sleeping 20-22hr a day
 - Much less verbal and interactive
 - Does not endorse pain so no analgesics given
- Decision is made to place on hospice and d/c to nursing facility and cancel plans for hip repair.

Why is Mrs. F so sleepy?

- A) Recurrent UTI
- B) Pain is uncontrolled
- C) She is actively dying
- D) She's delirious
- E) Severe depression

Why is Mrs. F so sleepy?

- A) Recurrent UTI
- B) Pain is uncontrolled
- C) She is actively dying
- D) She's delirious
- E) Severe depression

Outcomes of Delirium:

- Primary Care:
 - Psychological Stress
 - Long term cognitive impairment
 - Functional impairment
- ED care:
 - Prolonged stay
 - Communication difficulties
 - Falls, injuries to staff, pulling out lines

Outcomes of Delirium:

- Hospital Care:
 - Prolonged stay
 - Increased cost and staffing needs
 - Increase discharge to skilled nursing facilities
 - Increased mortality rates



Conclusions:

- Thinking about delirium is the first step to noticing and diagnosing this disorder
- Delirium can be managed
- Treatment is multifactorial and patient dependent
- Delirium has long term affects that you can prevent