

# **Carotid Stenosis: Imaging**

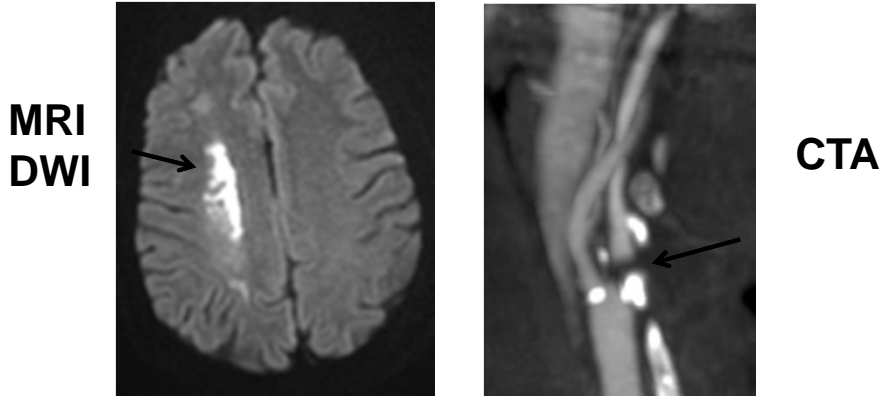
**Daniel Boulter, MD**  
Assistant Professor – Clinical  
Clinical Director – Magnetic Resonance Imaging  
Division of Neuroradiology  
Department of Radiology  
The Ohio State University Wexner Medical Center

## **Learning Objectives**


- **Describe relationship between carotid stenosis and stroke**
- **Compare carotid imaging techniques**
- **Interpret carotid imaging results and consider implications for management**
- **Discuss stroke risk stratification with advanced imaging**

# Carotid Stenosis and Stroke

- Stroke → 3<sup>rd</sup> leading cause of death
- Atherosclerosis → 15-20% of strokes
- Carotid stenosis is a major risk factor



# Atherosclerotic Plaque Progression



Normal vessel	Fatty streak	Fibro-fatty plaque	Advanced or Vulnerable plaque
---------------	--------------	--------------------	-------------------------------

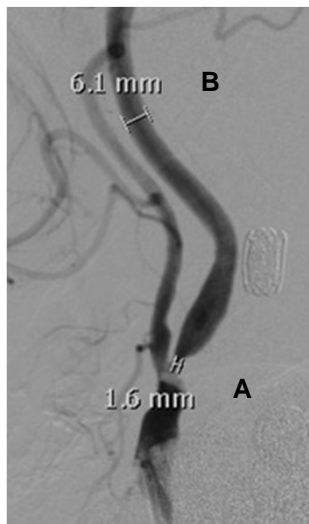
Clinically silent

May be symptomatic

## North American Symptomatic Carotid Endarterectomy Trial, 1991

- **Severe stenosis (70-99%)**
  - *Significant benefit at 2 yrs: CEA 9% vs MM 26%*
- **Moderate stenosis (50-69%)**
  - *Moderate benefit at 5 yrs: CEA 16% vs MM 22%*
- **Mild stenosis <50%**
  - *No benefit at 5 yrs: CEA 15% vs MM 19%*

## NASCET Measurement Criteria



Catheter angiogram

Stenosis Calculation:

$$1 - \frac{A}{B} \times 100 = \text{Stenosis \%}$$

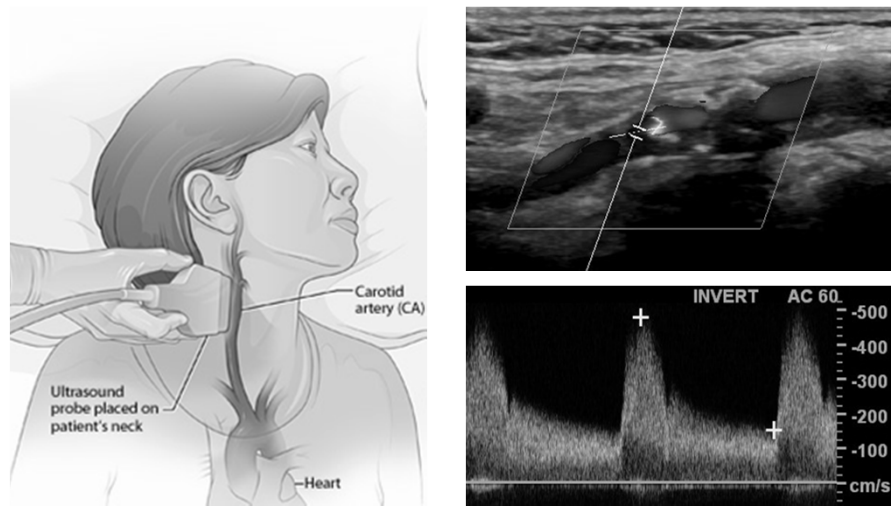
$$1 - \frac{1.6}{6.1} \times 100 = 74\%$$

Lumen diameter:

A: Narrowest ICA diameter

B: Normal distal ICA diameter

# Carotid Duplex Ultrasound

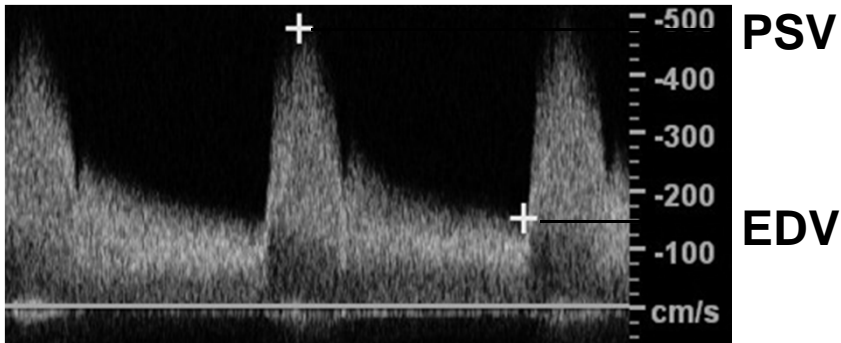


## Duplex US Indications

- ***Asymptomatic* patient, *suspected* stenosis**
  - Carotid bruit, history of PAD or CAD, risk factors
- ***Symptomatic* patient, *suspected* stenosis**
  - Hemispheric stroke, TIA, amaurosis fugax
- **Follow-up, *known* stenosis (>50%)**

## Ultrasound Stenosis Grading

- **Severe Stenosis (70-99%)**
  - Peak systolic flow velocity (PSV):  $>230$  cm/s
  - End diastolic velocity (EDV):  $>100$  cm/s
  - ICA:CCA PSV ratio:  $>4$

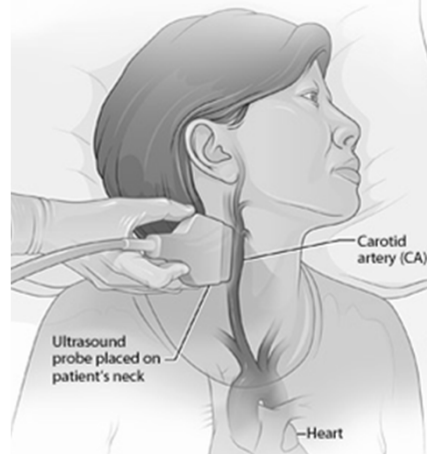


## Ultrasound Stenosis Grading

- **Severe Stenosis (70-99%)**
  - Peak systolic flow velocity (PSV):  $>230$  cm/s
  - End diastolic velocity (EDV):  $>100$  cm/s
  - ICA:CCA PSV ratio:  $>4$
- **Moderate Stenosis (50-99%)**
  - Peak systolic flow velocity (PSV): 125 – 230 cm/s
  - End diastolic velocity (EDV): 40 – 100 cm/s
  - ICA:CCA PSV ratio: 2 – 4

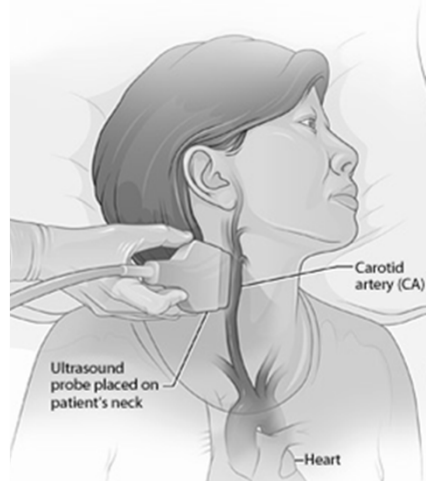
## Advantages of Ultrasonography

- No radiation
- No IV contrast
- Cost effective
- Best screening test
- Best for serially following patients on therapy



## Limitations of Ultrasonography

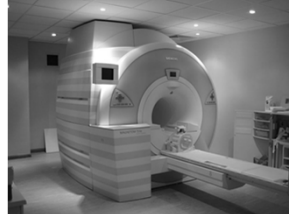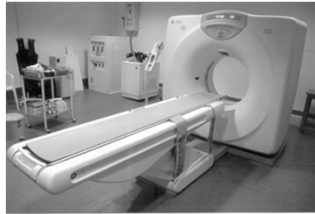- Operator dependent
- Limited field-of-view
  - No arch, intracranial
- Calcific shadowing
- Stenosis estimated based upon velocity
- Confirmatory test often needed prior to revascularization



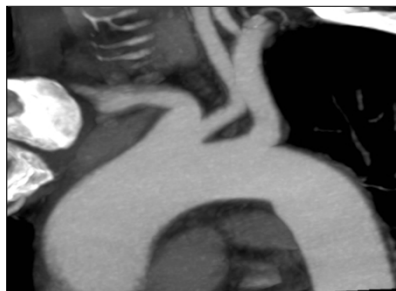
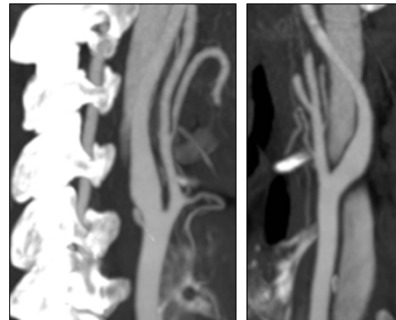
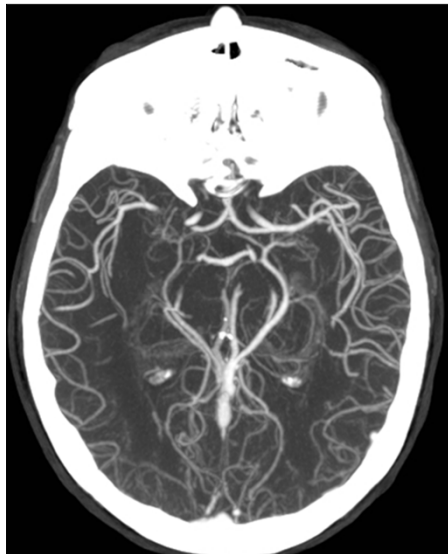
## Indications for CTA or MRA

*Acute ischemic neurologic symptoms, and*

- Ultrasound cannot be obtained, equivocal or non-diagnostic
- No carotid stenosis on ultrasound, search for intracranial vascular disease
- Confirmation of severe carotid stenosis or planning for revascularization procedure

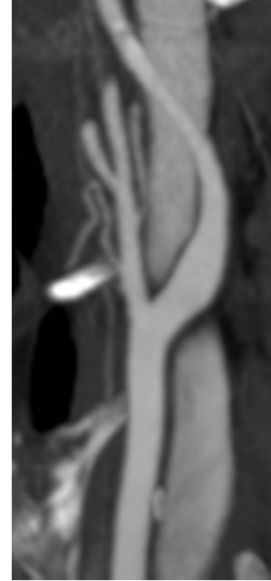

## CT Angiography



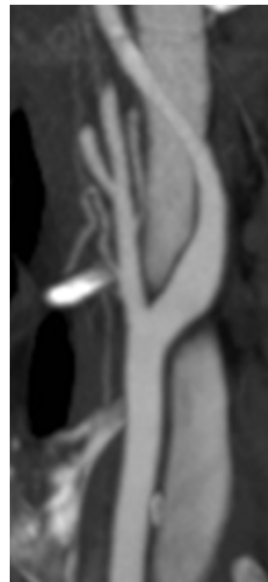## Advantages of CT Angiography

- Rapid (seconds of imaging)
- Available 24/7 emergency
- Aorta to Circle of Willis
  - Vessel origins
  - Tandem lesions
  - Distal embolus
- Plaque composition
- Brain imaging



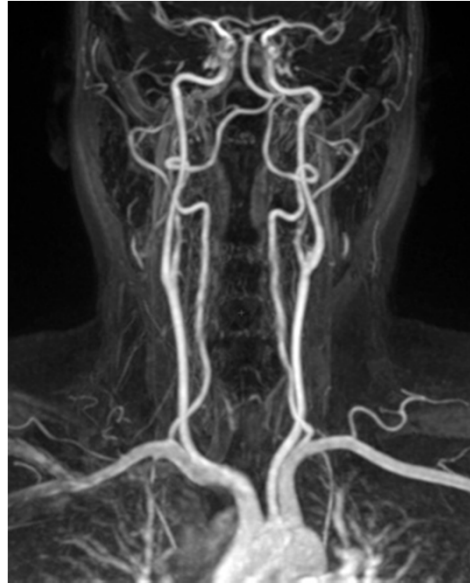
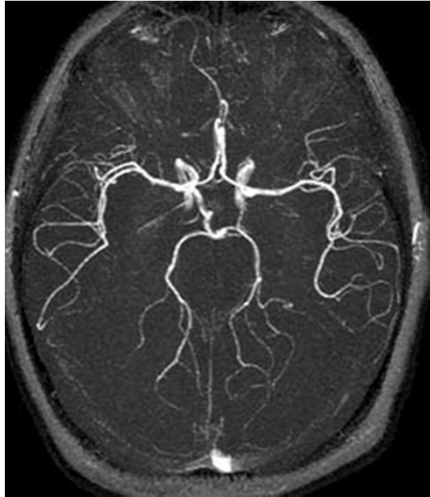
## Limitations of CT Angiography

- Requires IV contrast
  - Allergy
  - Renal failure
- Radiation dose
- May overestimate stenosis
  - Densely calcified plaques
  - Stents



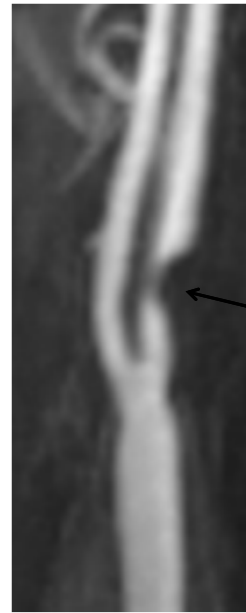


# MR Angiography



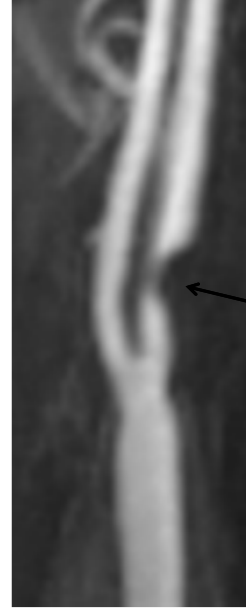## Advantages of MR Angiography

- No radiation
- Possible without IV contrast
- Aorta to Circle of Willis
  - Vessel origins
  - Tandem lesions
  - Distal embolus
- Brain imaging (MRI diffusion-weighted imaging)



## Limitations of MR Angiography

- Relatively lengthy (~15 min)
- Sensitive to motion artifacts
- Claustrophobia
- Ferromagnetic metal implants (pacemaker, etc)
- Best with IV contrast
  - Renal failure
- Lumen imaged only, without specialized sequences



## Advanced Imaging Risk Stratification

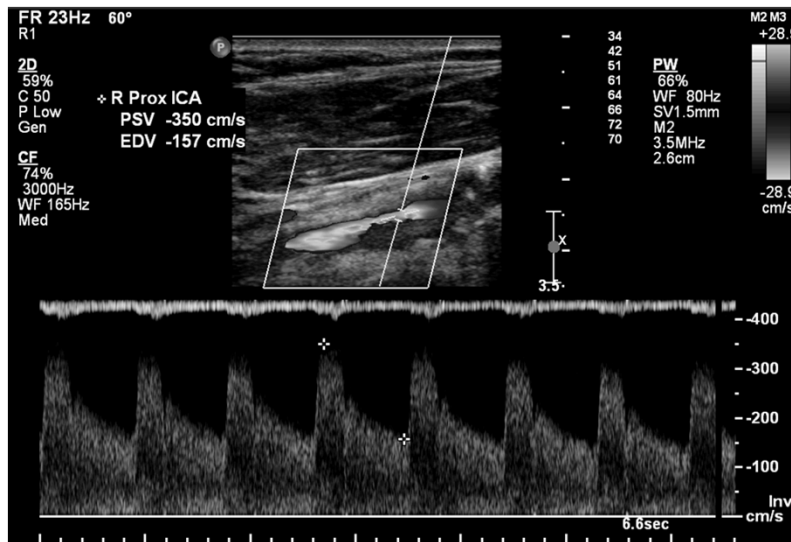
- Carotid plaque imaging (MRI, CT, US)
  - Ulceration, thin or ruptured fibrous cap
  - Intra-plaque hemorrhage
  - Lipid rich or necrotic core
  - Angiogenesis, leads to hemorrhage
  - Plaque inflammation (PET)
- Cerebrovascular reserve imaging
  - Acetazolamide challenge paired with perfusion imaging (SPECT, MRI or CT)
  - “Stress test” for the brain

## CASE 1

**56 y/o male with 3 month history of recurrent TIAs characterized by left sided weakness, sensory symptoms**

- History of iodinated contrast allergy
- No metallic implants
- Not claustrophobic

## Carotid Duplex Ultrasound



**3 month history of recurrent right hemispheric TIAs**

# Carotid Duplex Ultrasound

Segment				
	PSV	EDV	Ratio	% Stenosis
Prox CCA	50.7	15.3		
Dist Com Carotid	43.2	13.8		
Prox. ICA	350	157	8.1	70 - 99%
Mid. ICA	266	81.7	6.16	50 - 69%
Dist. ICA	122	22.6	2.82	
Ext Carotid	145	27.5		
Vertebral				

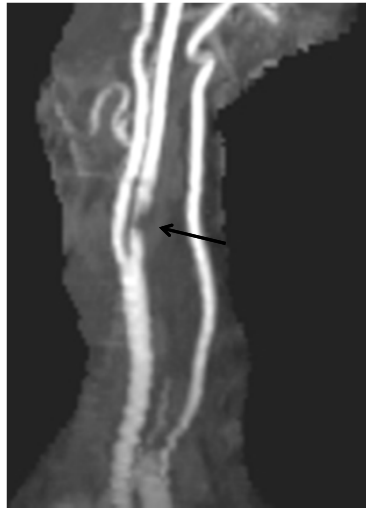Right carotid duplex indicates **70-99% stenosis of internal carotid artery.**

Segment				
	PSV	EDV	Ratio	% Stenosis
Prox CCA	95.9	33		
Dist Com Carotid	90.4	31.4		
Prox. ICA	69.8	27	0.77	< 50%
Dist. ICA	96.2	38.1	1.06	
Ext Carotid	114	24.4		
Vertebral				

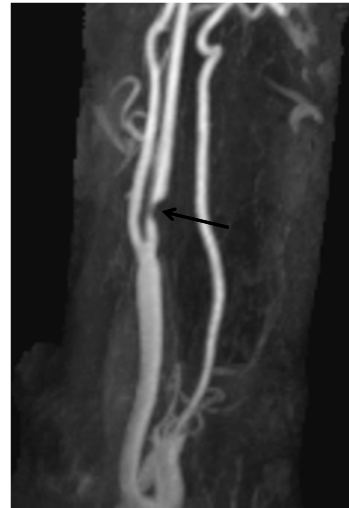Left carotid duplex indicates **<50% stenosis of internal carotid artery.**

## Video #1 MR Angiography

*WITHOUT* Gadolinium (2D TOF)



*WITH* Gadolinium (3D TOF)



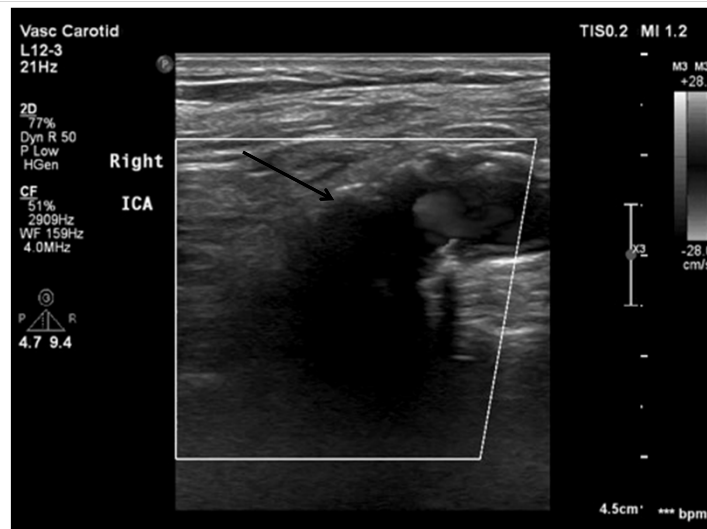
**Severe ICA stenosis, treated with carotid endarterectomy**

## CASE 2

65 y/o male with history of diabetes mellitus, hypertension, and 50 pack year smoking history. Assessment of operative risk prior to planned colectomy for mass found on colonoscopy.

- What is the best test in this case?

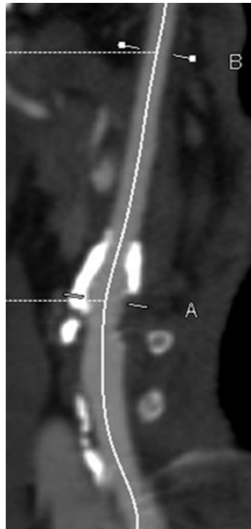### Video #2 Doppler Ultrasound



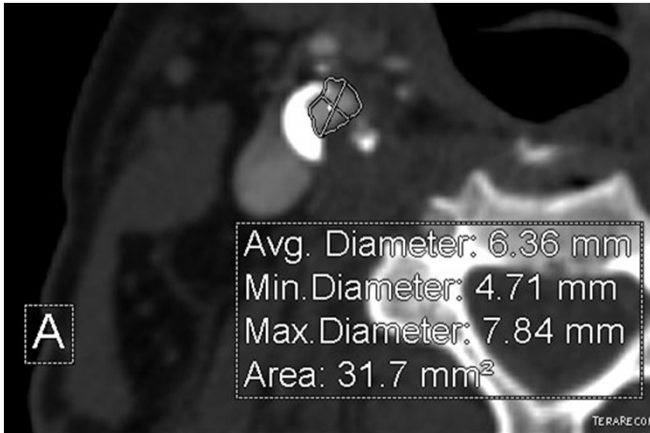
Interpretation: Right ICA appears occluded or near occluded, extreme acoustic shadowing from calcification.

## CT Angiography: Curved Planar Reformat

Patency Confirmed



Curved Planar Reformat



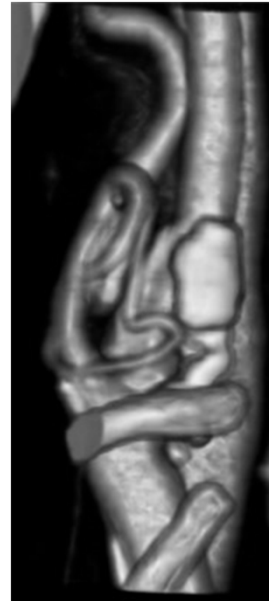True axial reconstruction  
Lumen quantification

## CT Angiography: Advanced Visualization

### Common Processing Techniques:

- 3D Volume Rendered (3D VR)
- Maximum Intensity Projection (MIP)
- Multiplanar Reformat (MPR)
- Curved Planar Reformat (CPR)

VIDEO #3



## **CASE 3**

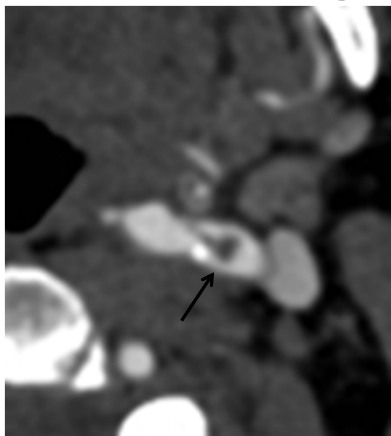
**64 y/o female with acute right-sided weakness and aphasia, presented to Emergency Department after hours**

- **No metallic implants**
- **Not claustrophobic**

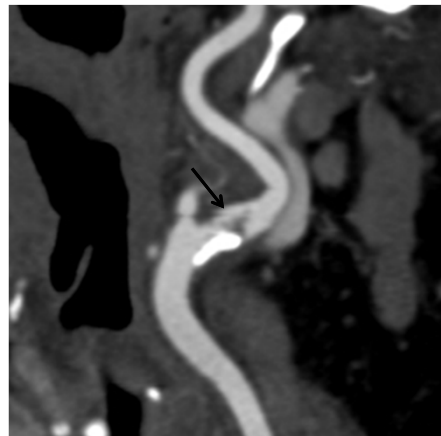
**What is the best test in this case?**

## **CT Angiography: Left Carotid Bifurcation**

**Axial source images**

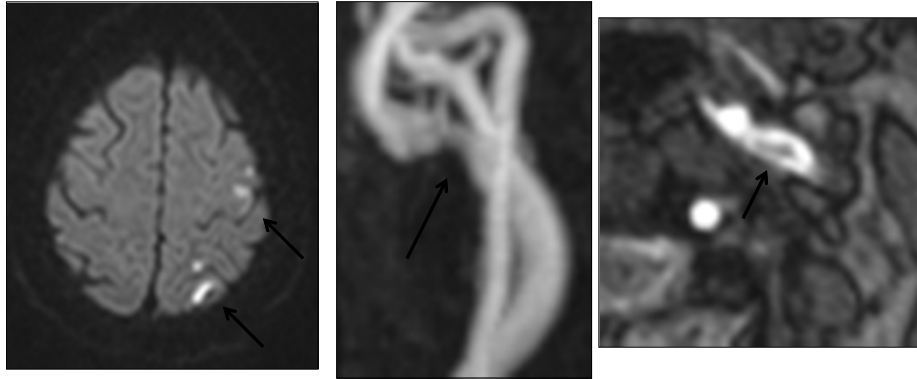


**Curved planar reformat**



**64 y/o female with acute right-sided weakness and aphasia**

## MRI and MRA

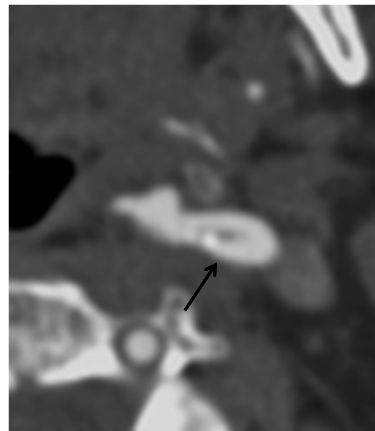
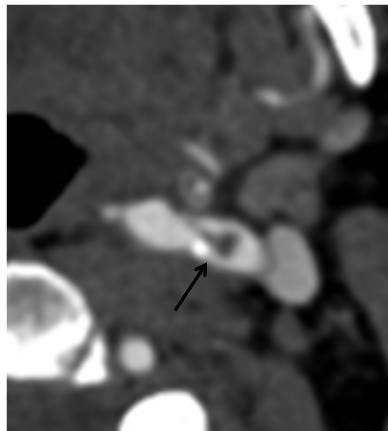


**64 y/o female with acute right-sided weakness and aphasia**

## Post-Treatment CT Angiography

**DAY 0: Presentation**

**DAY 16: post tPA, antiplatelet**



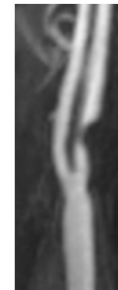
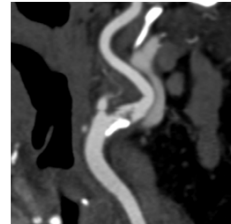
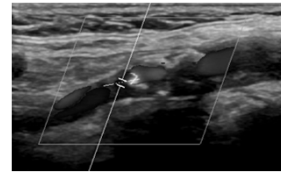
**Axial CTA Left Carotid**

**Intra-arterial thrombus resolved with medical therapy**



## Key Points

- **Stroke risk increases with:**
  - Carotid stenosis severity
  - Plaque vulnerability
- **Ultrasound: *Screening* test**
- **CTA or MRA: *Confirmatory*; *Acute* setting**
- **Advanced imaging may stratify individual risk beyond stenosis**

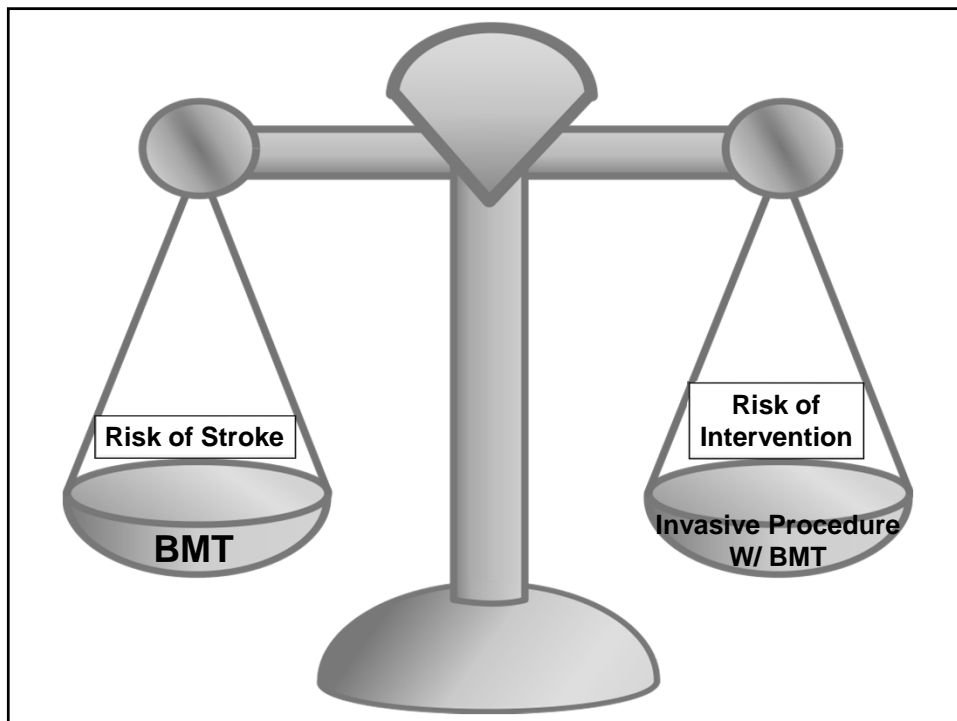


## Carotid Stenosis: Diagnosis and Management

**Mounir J. Haurani, MD**  
Assistant Professor – Clinical  
Division of Vascular Diseases and Surgery  
Department of Surgery  
The Ohio State University Wexner Medical Center

# Treatment of Carotid Artery Disease

- Even patients undergoing interventions for carotid artery disease need best medical therapy (BMT)



## Best Medical Therapy

- **Blood Pressure Control**
  - **Asymptomatic extracranial carotid or vertebral atherosclerosis, below 140/90 mm Hg**
  - **For Symptomatic treatment is probably indicated but specific target has not been established**
    - **risk of exacerbating cerebral ischemia in acute stroke**
  - **Multiple Meta analysis, epidemiologic studies, and randomized trials have demonstrated 20-40% reduction in stroke with antihypertensive treatment**

## Best Medical Therapy

- **Smoking Cessation**
  - **Smoking increases relative risk of ischemic stroke by 25% -50%**
  - **Stroke risk decreases within 5 years of quitting compared with continuing smokers**



[https://upload.wikimedia.org/wikipedia/commons/thumb/1/11/No\\_smoking\\_symbol.svg/600px-No\\_smoking\\_symbol.svg.png](https://upload.wikimedia.org/wikipedia/commons/thumb/1/11/No_smoking_symbol.svg/600px-No_smoking_symbol.svg.png)

## Best Medical Therapy

- Treatment with a statin medication is recommended for all patients with extracranial carotid or vertebral atherosclerosis
  - Low-density lipoprotein (LDL) cholesterol below 100 mg/dL for asymptomatic
  - Near or below 70 mg/dL in those who sustain ischemic stroke, or diabetics
  - Add bile acid sequestrants medications or niacin for patients who do not tolerate statins or can't achieve above levels.

## Best Medical Therapy

- Meta-analysis of 26 trials (90 000 patients )
  - statins reduced the risk of all strokes by approximately 21% (Amarenco P, et al, Stroke. 2004;35:2902–9)
- Another meta-analysis of 9 trials(>65 000 patients)
  - 22% reduction in ischemic stroke per 1-mmol/L (40-mg/ dL) reduction in serum LDL cholesterol (Baigent C, et al, Lancet. 2005;366: 1267–78.)
- A randomized trial, SPARCL (Stroke Prevention by Aggressive Reduction in Cholesterol Levels)
  - atorvastatin (80 mg daily) vs placebo on the risk of stroke among patients with recent stroke or TIA (Amarenco P, et al, N Engl J Med. 2006;355: 549–59. )
    - reduced the absolute risk of stroke at 5 years by 2.2%
    - RR of ischemic stroke by 22%.

## **Best Medical Therapy**

- **Patients with DM and extracranial carotid or vertebral artery atherosclerosis.**
  - **Diet, exercise, and glucose-lowering drugs**
  - **Stroke prevention benefit of intensive glucose lowering therapy to a glycosylated hemoglobin A1c level less than 7.0% has not been established.**

## **Best Medical Therapy**

- **Antiplatelet therapy with aspirin (75 to 325 mg daily) is recommended for prevention of MI and other ischemic cardiovascular events**
- **Patients with ischemic stroke or TIA**
  - **aspirin alone (75 to 325 mg daily)**
  - **Clopidogrel alone (75 mg daily)**
  - **Aspirin plus extended-releasedipyridamole(25and200 mg twice daily, respectively)**
  - **Antiplatelet agents are recommended rather than oral anticoagulation for patients with or without ischemic symptoms**

# Best Medical Therapy

- Hypertention
- Hyperlipidemia,
- Smoking Cessation
- Antiplatelet




Image provided courtesy of Blair Vermilion, MD



Image provided courtesy of Blair Vermilion, MD

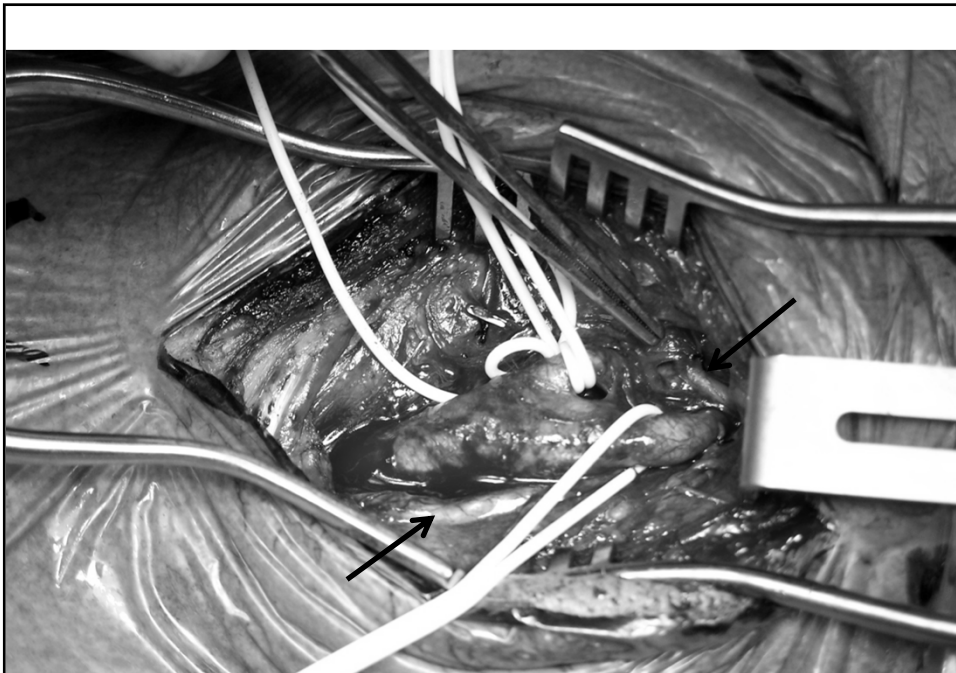
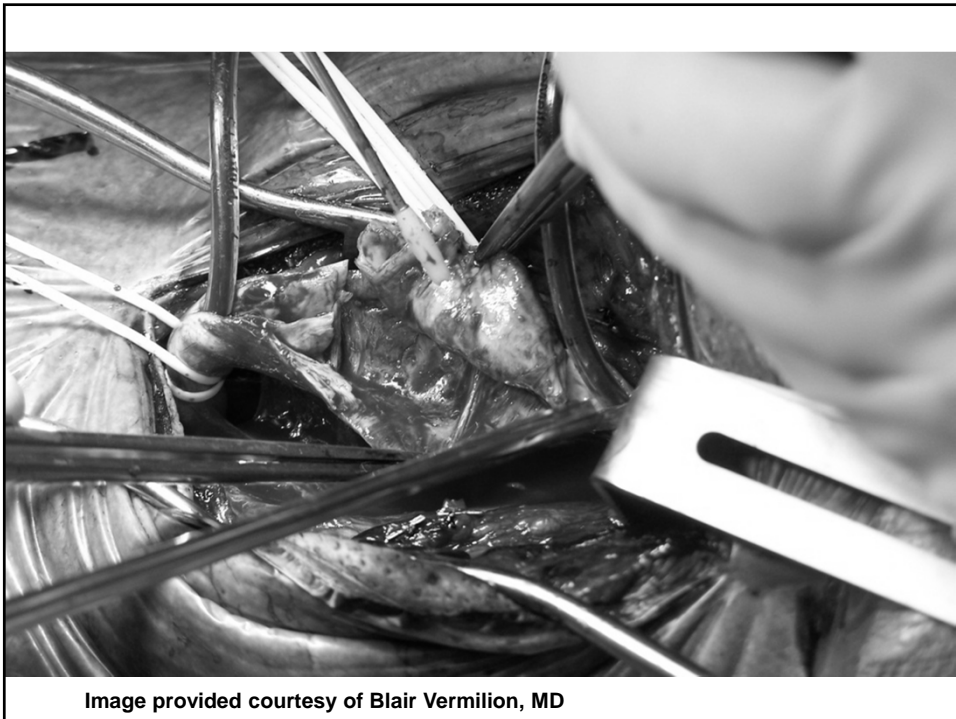

Image provided courtesy of Blair Vermilion, MD

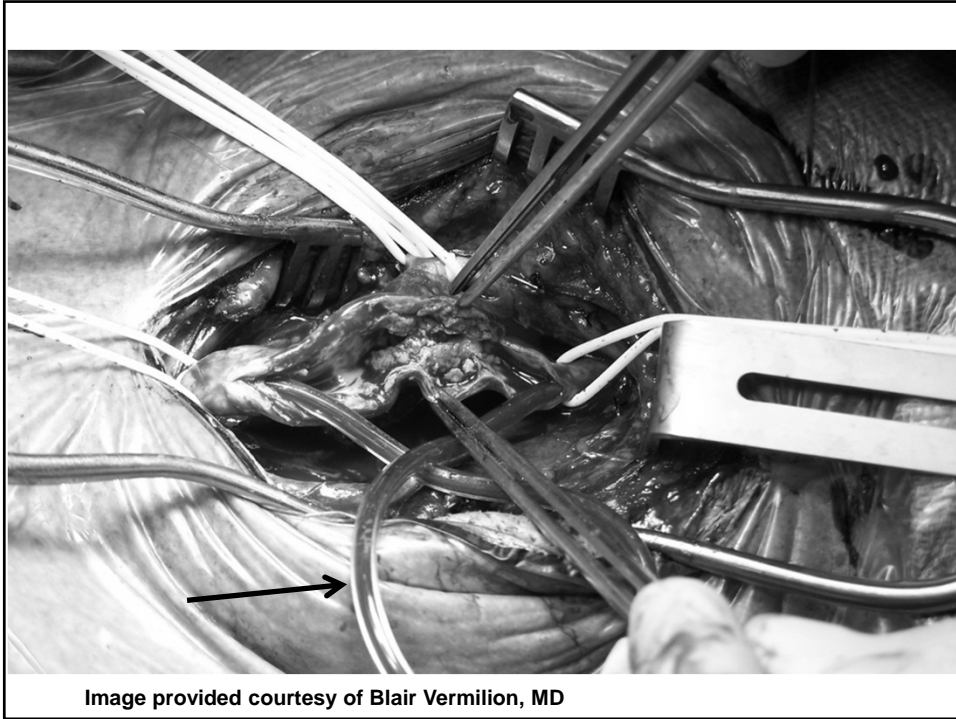
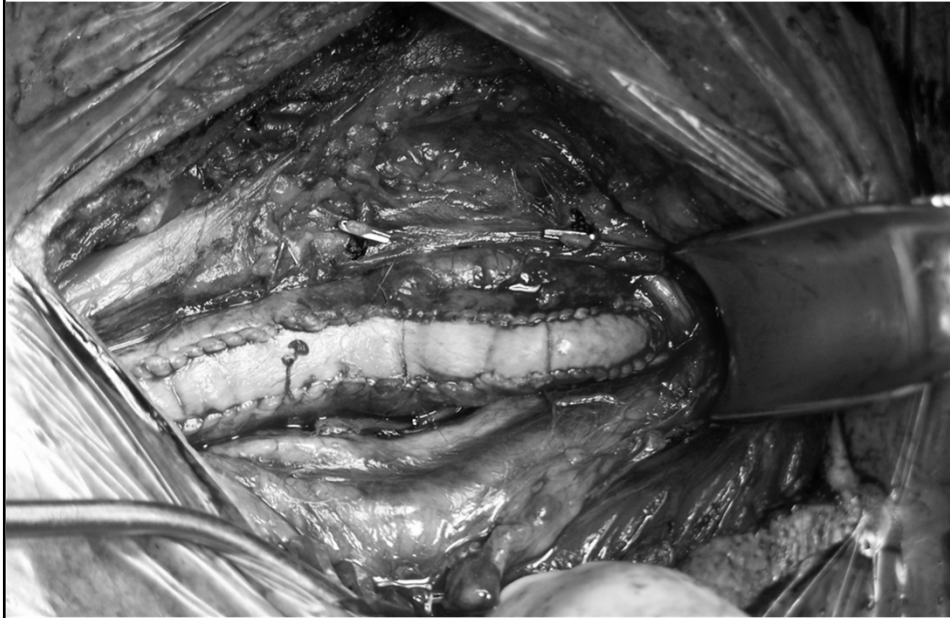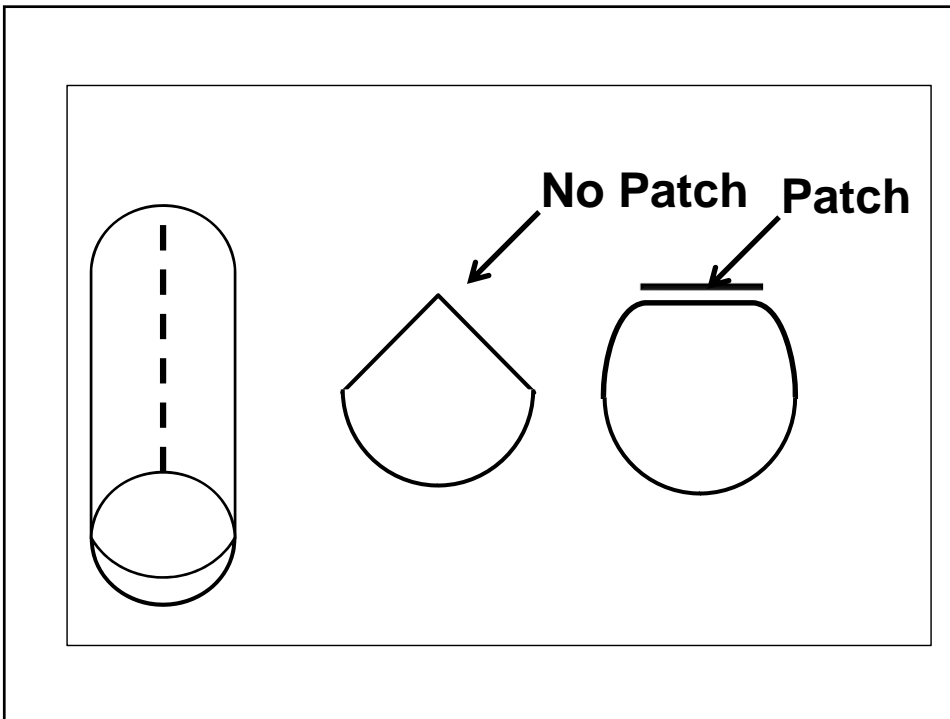
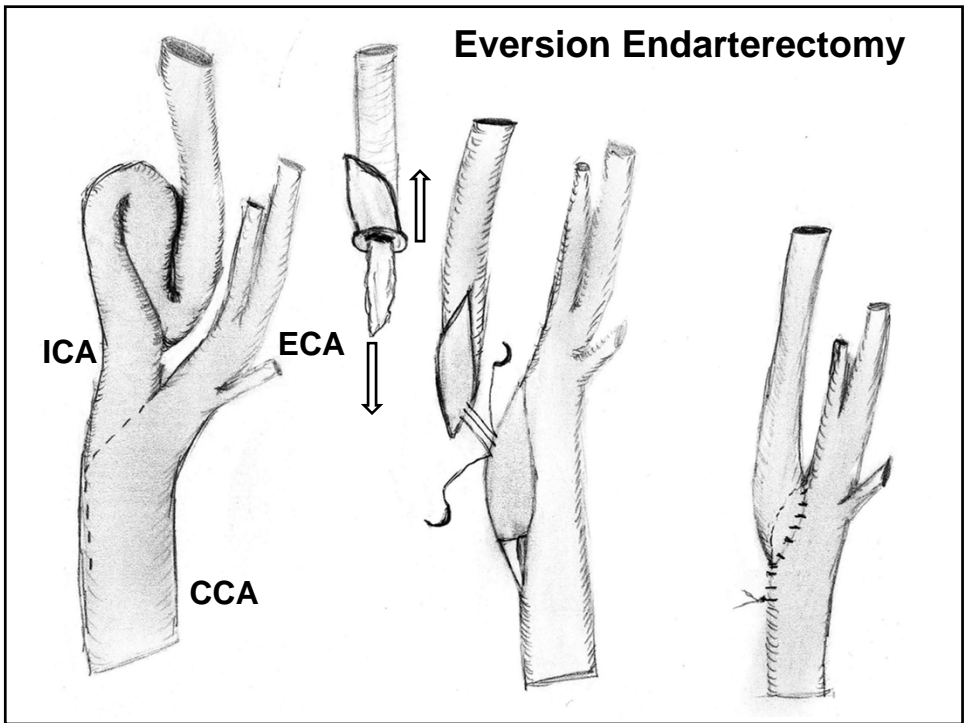


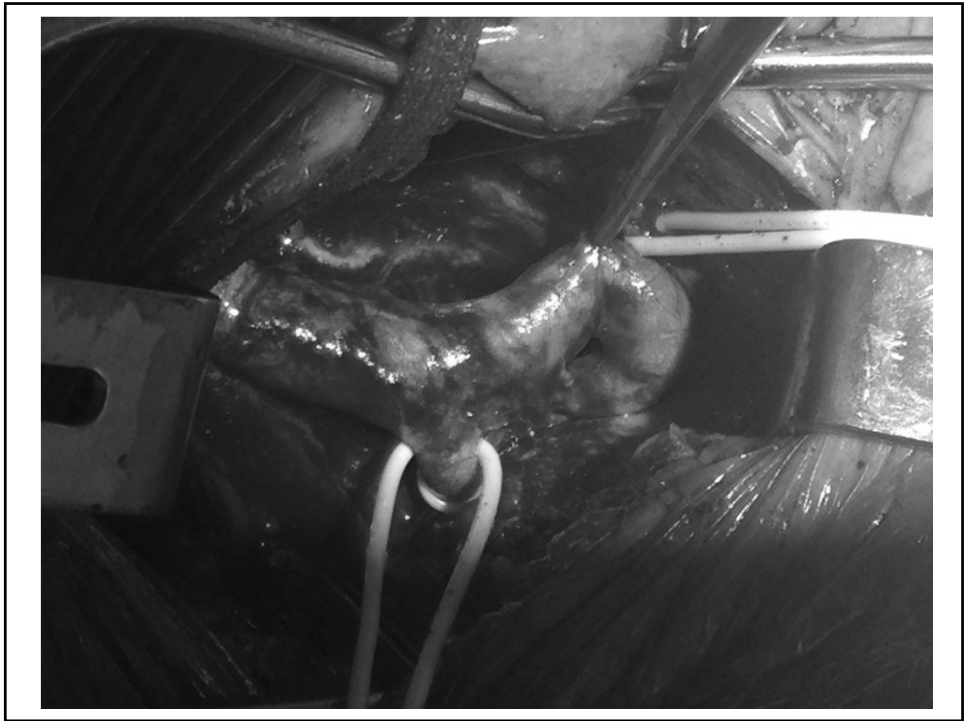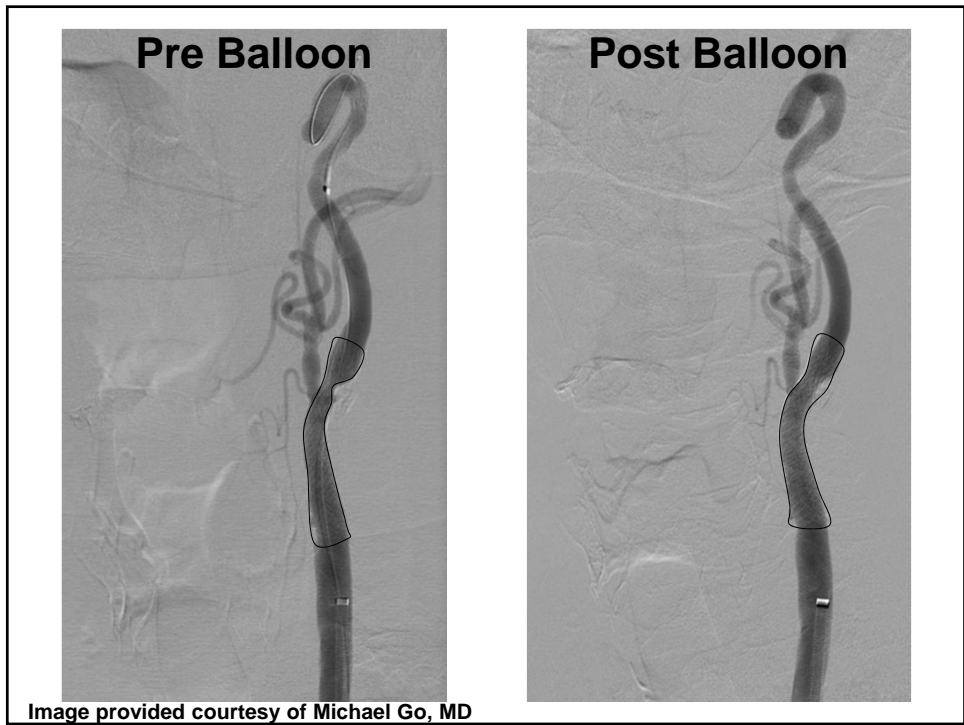
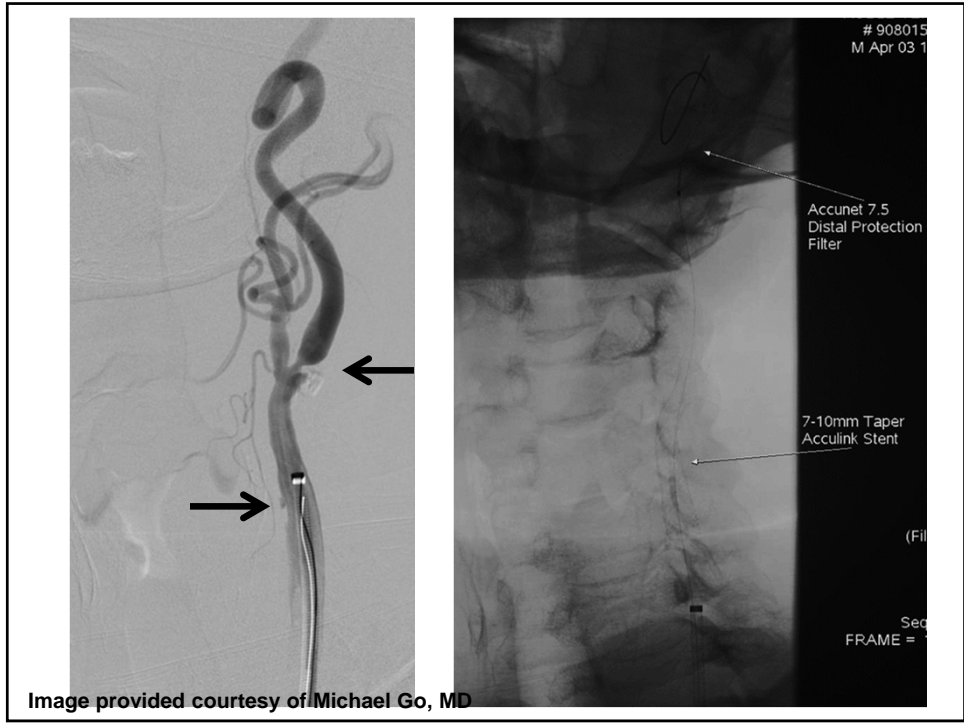




Image provided courtesy of Blair Vermilion, MD







## Is Carotid Intervention Still Needed?

### Topical Review

Section Editors: Larry B. Goldstein, MD, and  
Peter M. Rothwell, PhD, FRCP, FMedSci

### Medical (Nonsurgical) Intervention Alone Is Now Best for Prevention of Stroke Associated With Asymptomatic Severe Carotid Stenosis

Results of a Systematic Review and Analysis

Anne L. Abbott, PhD, MBBS, FRACP

**Abstract**—Significant advances in vascular disease medical intervention since large randomized trials for asymptomatic severe carotid stenosis were conducted (1983–2003) have prompted doubt over current expectations of a surgical benefit. In this systematic review and analysis of published data it was found that rates of ipsilateral and any-territory stroke (+/-TIA), with medical intervention alone, have fallen significantly since the mid-1980s, with recent estimates overlapping those of operated patients in randomized trials. However, current medical intervention alone was estimated at least 3 to 8 times more cost-effective. In conclusion, current vascular disease medical intervention alone is now best for stroke prevention associated with asymptomatic severe carotid stenosis given this new evidence, other cardiovascular benefits, and because high-risk patients who benefit from additional carotid surgery or angioplasty/stenting cannot be identified. (*Stroke*. 2009;40:e573–e583.)

**Key Words:** asymptomatic carotid stenosis ■ carotid endarterectomy ■ endovascular treatment ■ health policy  
■ stroke prevention

Full text available free online at:  
<http://stroke.ahajournals.org/content/40/10/e573.full.pdf>  
Last accessed 12/1/2015

## Asymptomatic Carotid Artery Stenosis

- **North American Symptomatic Carotid Endarterectomy Trial (NASCET)**
  - Followed the asymptomatic contralateral carotid artery for 5 years
  - 2,377 patients
    - 216 (9%) had a stenosis >60%
    - 113 (4.7%) had a stenosis of 75-99%
  - The 5-year risk of ipsilateral stroke (not TIA) in the 75-99% asymptomatic stenosis cohort was 18.5% (3.7%/yr)
  - 60%-99% cohort such that the annual stroke rate was reported as 3.2%.

The causes and risk of stroke in patients with asymptomatic internal-carotid-artery stenosis. North American Symptomatic Carotid Endarterectomy Trial Collaborators.

Inzitari D1 et. al, N Engl J Med. 2000;342:1693-1700

## **Asymptomatic Carotid Artery Stenosis**

- **The Asymptomatic Carotid Stenosis and Risk of Ipsilateral Hemispheric Ischemic Events Study (ACSRS)**
  - 1,115 patients with asymptomatic carotid stenosis >50% by duplex scanning for 6-84 months (mean 37.1)
  - Annual stroke rate in high-risk patients was 4.3% (vs. 0.7% in low-risk patients).
  - 453 patients with 70%-99% stenosis by NASCET
    - Raw stroke rate of 5.7%
    - 5-year ipsilateral event rate of about 18%.
  - If patients with 50-69% were added, the raw stroke rate decreased to 1.3%.

Severity of asymptomatic carotid stenosis and risk of ipsilateral hemispheric ischaemic events: results from the ACSRS study.

Nicolaides AN, et. Al., Eur J Vasc Endovasc Surg. 2005 Sep;30(3):275-84.

## **Asymptomatic Carotid Artery Stenosis**

- **The Asymptomatic Stenosis Embolus Detection (ASED)**
  - Prospective trial, transcranial Doppler embolic signal detection would identify increased risk of ipsilateral neurologic events
  - 240 arteries studied, 115 (48%) had a stenosis of 70%-99%
    - Average ipsilateral carotid event rate was 3.1%/yr with a 1% stroke/ yr.

Embolic signals and prediction of ipsilateral stroke or transient ischemic attack in asymptomatic carotid stenosis: a multicenter prospective cohort study.

Abbott AL, et. al. Stroke. 2005 Jun;36(6):1128-33. Epub 2005 May 5.

## **Asymptomatic Carotid Artery Stenosis**

- **Randomized prospective trials such as the asymptomatic carotid artery stenosis (ACAS), and Asymptomatic carotid surgery trial (ACST)**
  - **Similar annual stroke risk of 2% for patients treated with medical therapy**
  - **10-year follow-up data in the ACST trial demonstrated a sustained benefit for endarterectomy over optimal medical therapy.**
  - **Nearly 80% of patients were on optimal medical therapy (aspirin plus statin agents) in the later years of the trial.**
  - **10-year data showed protective effect of endarterectomy was higher in non statin group (5.8% in patients taking a statin and 6.2% in those who were not)**
  - **BUT protective effect of endarterectomy over optimal medical therapy was statistically significant (P=0.002).**

## **Symptomatic Disease**

- **70 – 99%**
- **NASCET 2 year follow up**
  - **26% stroke risk in medical arm**
  - **9% stroke risk in surgical arm**

## **Symptomatic Disease**

- **50 – 69%**
- **NASCET 5 year follow up**
  - **22.7% stroke risk in medical arm**
  - **15.7% stroke risk in surgical arm**

## **Symptomatic Disease**

- **Symptoms within 120 days**
- **Increased risk reduction with greater degrees of stenosis**
- **Especially benefits males > 75**
- **There is benefit for women, but not as dramatic**

## Carotid Artery Stenting Outcomes

- Randomized trials plagued by
  - bias
  - operator inexperience
  - aberrant CEA outcomes
  - angioplasty without stent

## Stenting Outcomes

Trial	CEA stroke/death	CAS stroke/death	CEA restenosis	CAS restenosis
CAVATAS 2001	9.9%	10%	10.5%	30.7%
SAPPHIRE 2004	20.1%	12.2%		
EVA-3S 2006	3.9%	9.6%		
SPACE 2006	6.3%	6.8%	4.6%	10.7%



# CREST

- **The most rigorous credentialing effort of any clinical trial (2,502 lead-in patients)**
- **Operators screened based on pre-trial outcomes and experience**
- **Then proctored**
- **Then subject to review after up to 20 cases performed during the lead-in phase**

Stenting versus Endarterectomy for Treatment of Carotid-Artery Stenosis. Brott, Thomas G., et al. N Engl J Med 363(1), 11-23.

## CREST Lead-In

- **CAS**
  - **4.4% stroke/death**
  - **13.2% stroke/death > 80**
  - **13% restenosis**

Stenting versus Endarterectomy for Treatment of Carotid-Artery Stenosis. Brott, Thomas G., et al. N Engl J Med 363(1), 11-23.

# CREST

- CEA stroke/MI/death 6.8%
- CAS stroke/MI/death 7.2%
  
- CEA MI 2.3%
- CAS MI 1.1%
  
- CEA stroke 2.3%
- CAS stroke 4.1%

Stenting versus Endarterectomy for Treatment of Carotid-Artery Stenosis. Brott, Thomas G., et al. N Engl J Med 363(1), 11-23.

# CREST

- Better outcomes with CAS < 70
- Better outcomes with CEA > 70
- Symptomatic patients have lower stroke/death rates with CEA
- Stroke had greater QoL impact than MI

Stenting versus Endarterectomy for Treatment of Carotid-Artery Stenosis. Brott, Thomas G., et al. N Engl J Med 363(1), 11-23.

## **Recommendation Asymptomatic Disease**

- 1. Patients with stenosis <60%**
  - Optimal medical therapy
- 2. CEA is preferred to CAS for reduction of all-cause stroke and periprocedural death**
  - CREST suggest that patients aged <70 years may be better treated by CAS, but these data need further confirmation.
- 3. >60% diameter stenosis**
  - Considered CEA for reduction of long-term risk of stroke
  - 3- to 5-year life expectancy
  - Perioperative stroke/death rates can be <3%

Updated Society for Vascular Surgery guidelines for management of extracranial carotid disease. John J. Ricotta, MD, et al. JOURNAL OF VASCULAR SURGERY, Volume 54, Number 3

## **Recommendation Asymptomatic Disease**

- 4. CEA is preferred over CAS in patients aged >70 years of age**
  - with long (>15-mm) lesions
  - preocclusive stenosis
  - lipid-rich plaques that can be completely removed safely
- 5. Patients deemed “high risk” for CEA >3% perioperative morbidity / mortality**
  - CAS only as part of an ongoing clinical trial
- 6. Insufficient data to recommend CAS as primary therapy for 70% to 99% diameter stenosis**
  - CREST showed CAS is equivalent to CEA in the hands of experienced interventionalists.

Updated Society for Vascular Surgery guidelines for management of extracranial carotid disease. John J. Ricotta, MD, et al. JOURNAL OF VASCULAR SURGERY, Volume 54, Number 3

## **Recommendation Symptomatic Disease**

- 1. Patients with stenosis <50%**
  - **Optimal medical therapy**
- 2. CEA is preferred to CAS for reduction of all-cause stroke and periprocedural death**
- 3. CAS is preferred over CEA with >50% stenosis and**
  - **tracheal stoma**
  - **local tissues are scarred and fibrotic**
  - **prior cranial nerve injury**
  - **lesions that extend proximal to the clavicle or distal to the C2**

Updated Society for Vascular Surgery guidelines for management of extracranial carotid disease. John J. Ricotta, MD, et al. JOURNAL OF VASCULAR SURGERY, Volume 54, Number 3

## **Recommendation Symptomatic Disease**

- 4. CAS is preferred over CEA with >50% stenosis and**
  - **severe uncorrectable CAD**
  - **congestive heart failure**
  - **chronic obstructive pulmonary disease**
  - **May be potential increased role of optimal medical management as primary therapy in this high- risk group.**

Updated Society for Vascular Surgery guidelines for management of extracranial carotid disease. John J. Ricotta, MD, et al. JOURNAL OF VASCULAR SURGERY, Volume 54, Number 3