

Nutrition Care for the General Practitioner

Adeeti Chiplunker, MD, MMS
*Assistant Professor of Medicine
Medical Director of Nutrition Services
Inflammatory Bowel Disease Center
Division of Gastroenterology, Hepatology, and Nutrition
The Ohio State University Wexner Medical Center*

MedNet21
Center for Continuing Medical Education

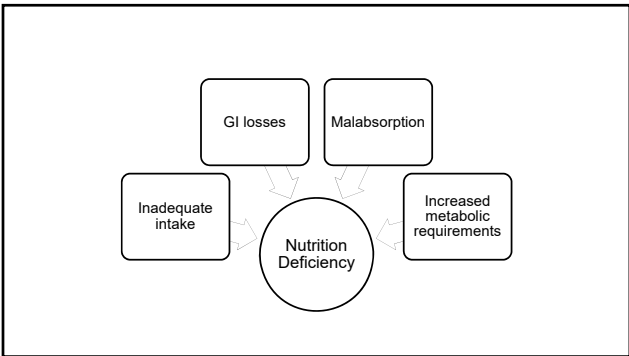
THE OHIO STATE UNIVERSITY
WEXNER MEDICAL CENTER

Disclosures

- Advisory Board: Janssen Biotech

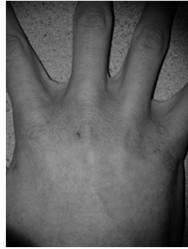Objectives

- What vitamin and mineral deficiencies are associated with specific GI disorders?
- What are some physical manifestations of common vitamin and mineral deficiencies?
- What is the best way to replete specific vitamin and mineral deficiencies?
- How do you define malnutrition?
- What is the best way to evaluate your patient for malnutrition?



Case 1

- A 34 year old woman comes to clinic to establish care for a new diagnosis of Crohn's disease involving the terminal ileum and colon.
- Prior to her diagnosis, she had diarrhea, abdominal pain, and weight loss for the past 6 months.
- In the course of her evaluation, she complains of scaly patches on her hands and legs. The patches are flaky and appear like dry skin but have not improved despite liberal use of emollients.
- What vitamin deficiency is this finding associated with?



Zinc Deficiency

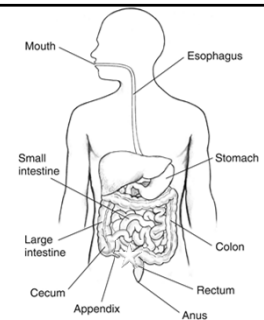
- Zinc is essential for the function of multiple enzymes involved in protein, fat and carbohydrate metabolism as well as DNA binding and transcription factors.
- Chronic diarrhea causes excessive loss of zinc in the stool.
- Also causes of zinc deficiency: low intake (eg: plant based diets), malabsorption (history of bariatric surgery), or chronic renal/liver disease
- Patients may also complain of altered taste sensation (dysgeusia)

Case 2

- A 67 year old man with a history of small bowel neuroendocrine cancer which necessitated the resection of 50cm of ileum presents with complaints of progressive numbness and tingling in the hands and feet. He feels unsteady on his feet and notes progressive fatigue.
- His complete blood count is notable for mean corpuscular volume (MCV) of 102.
- What vitamin is most likely to be deficient?
- What labs would you check to verify your suspicion?

Vitamin B12

- Vitamin B12 absorption is a multi-step process
- Stomach and Terminal ileum are the most important players
 - Stomach:
 - Gastric acid and intrinsic factor
 - Terminal Ileum:
 - Only part of the intestine that can absorb B12 (active transport)



Source: National Institute of Diabetes and Digestive and Kidney Diseases, National Institutes of Health - CC BY-NC 2.0 DEED

Vitamin B12 Deficiency

- Symptoms:
 - Peripheral or optic neuropathy
 - Myelopathy/Myeloneuropathy
 - Macrocytic anemia
- Risk Factors:
 - Low gastric acid (pernicious anemia, gastric bypass)
 - Low intake (vegan diet)
 - Decreased absorption (ileal resection)
- B12 may be falsely elevated in inflamed states (acute phase reactant)
 - Always check methylmalonic acid with B12 levels
 - Folate deficiency may co-exist

Case 3

- A 64 year old woman with a history of mesenteric ischemia secondary to superior mesenteric artery thrombosis at age 58. At that time, she underwent an exploratory laparotomy with resection of an extensive amount of small bowel. She has only 130cm of small bowel remaining which is continuity with her remaining colon, giving her a diagnosis of short bowel syndrome. She has been able to remain off TPN since her surgery and eats well but struggles with seeing at night while driving, difficulty looking up at traffic lights, easy bruising/bleeding, and has had a wrist fracture due to osteoporosis.
- What vitamins are most likely to be deficient?

Fat Soluble Vitamins

- Fat soluble vitamins are absorbed in the small intestine via micelles
- Causes
 - Fat malabsorption (pancreatic insufficiency, short bowel syndrome, gastric bypass)
 - Inadequate intake (total parenteral nutrition without any oral intake)
- Symptoms:
 - Vitamin A: dry scaly skin, night blindness
 - Vitamin D: muscle weakness/pain, osteopenia/osteoporosis
 - Vitamin E: peripheral neuropathy, ophthalmoplegia, hemolytic anemia
 - Vitamin K: easy bruising/bleeding

Case 4

- A 37 year old man with a history of a roux-en-y gastric bypass for obesity at age 23 comes to establish care. He has not followed up with his bariatric surgeon in many years. He has struggled with chronic iron deficiency without overt bleeding and has ongoing microcytic anemia despite IV iron infusions. He also notes muscle weakness and neuropathic pain in his legs. He notes hair loss and fatigue. He and his partner have been trying to conceive and he has been told his sperm count is low.
- What minerals is he likely to be deficient in?

Copper & Selenium (& Iron)

- These minerals rely on the stomach and duodenum for absorption
 - Altered foregut anatomy (eg: gastric bypass surgery) impacts absorption over time
- Symptoms:

Copper	Selenium	Iron
<ul style="list-style-type: none"> • Neuropathy/ataxia • Myelopathy/myeloneuropathy • Microcytic anemia • Neutropenia • Osteopenia • Skin depigmentation 	<ul style="list-style-type: none"> • Myalgias • Weakness • Anemia • Infertility in males (low sperm count, low sperm motility, abnormal sperm morphology) 	<ul style="list-style-type: none"> • Hair loss • Fatigue • Anemia • Restless legs

Repletion of Deficiencies

	Route	Dose	Frequency
B vitamins (except B12)	Oral	Varies (based on formulation)	Daily
Vitamin B12	IM/SL/intranasal	1000mcg	Monthly
Vitamin D	Oral	Ergocalciferol 50,000 IU Cholecalciferol (3000 – 5000 IU)	Weekly x 8-12 weeks Daily
Vitamin A	Oral IM (severe and/or ocular symptoms)	10,000 IU 10,000 IU	Daily x 3 months Daily x 3 days
Vitamin E	Oral	400 IU	Daily
Zinc	Oral IV	50mg	Daily
Copper	PO (gluconate) IV (chloride)		Daily Varies
Selenium	PO IV		Daily
Magnesium	PO (magnesium lactate) IV	84mcg Varies	TID Varies

Adapted from Kushner, R et al. Up to date: Bariatric Surgery – Postoperative nutritional management

Iron Repletion

- Iron:
 - Oral or IV
 - IBD:
 - If inactive, oral
 - IV if active or intolerant of oral
 - Dose and frequency depend on formulation
 - Gastric Bypass:
 - Prenatal vitamin with iron
 - IV if severe or no improvement with oral
 - Take oral with vitamin C to improve absorption
 - May cause constipation, greenish-black stools

Supplement Recommendations

- Inflammatory Bowel Disease
 - Vitamin D, calcium
 - No role for multivitamin unless other deficiencies
- Short Bowel Syndrome
 - Vitamin D, calcium
 - Chewable multi-vitamin with minerals
- Gastric Bypass
 - Vitamin D, calcium
 - Chewable multi-vitamin with minerals
- Vegan/Vegetarian Diet
 - Vitamin D, calcium
 - Vitamin B12

Summary of Deficiencies

	Zinc	Vitamin B12	Iron	Vitamin D	Vitamins A/E/K	Copper	Selenium	Others
Inflammatory Bowel Disease	✓	✓	✓	✓	Rare			B6 Folate Magnesium
Celiac Disease	✓	✓	✓	✓				
Pancreatic Disease ¹	✓			✓	✓			
Short Bowel Syndrome	✓	✓	✓	✓	✓	✓	✓	Chromium Magnesium
Chronic Liver Disease ²	✓			✓	✓			Thiamine B6 Folate
Gastric/Bariatric Surgery	✓	✓	✓	✓	✓	✓	✓	

¹ Min M. et al. *Pancreas* 2018; 47(8): 1015-1019
² Kobayashi M. et al. *Nutr Clin Pract*. 2020;35(1): 59-62

Definitions of Malnutrition

Criteria* Need at least 2 for diagnosis	Moderate Protein-Calorie Malnutrition (ICD-10: E44.0)	Severe Protein-Calorie Malnutrition (ICD 10: E43.0)
Energy Intake	<75% of requirement for ≥ 1 month	<75% of requirement for ≥ 1 month
Weight loss (%)	5% in 1 week 7.5% in 1 month 10% in 6 months 20% in 1 year	>5% in 1 week >7.5% in 1 month >10% in 6 months >20% in 1 year
Subcutaneous body fat loss (orbital, triceps, ribs)	Mild	Severe
Muscle Wasting (temporal, clavicles, shoulders, thighs, calves)	Mild to moderate	Severe
Fluid accumulation	Mild	Severe
Grip Strength	Normal	Reduced

Note: BMI is NOT included

*Adapted from: WHO et al. *J PERIMED NURS*. 2012; 26:271-276

Evaluating for Malnutrition Malnutrition Screening Tool

Have you lost weight without trying?		Have you been eating poorly because of decreased appetite?	
No	0 points	No	0 points
Unsure	2 points	Yes	1 point
Yes			
• 2-13 lbs	1 point		
• 14-23 lbs	2 points		
• 24-33 lbs	3 points		
• 34+ lbs	4 points		
• Unsure	2 points		

MST Score of 2 or more → At risk

Adapted from: Ferguson, M et al. *Nutrition* 1999 15:458-464

- ### Nutrition Focused Physical Exam
- Can be easily observed in the course of the clinical encounter
 - Evaluate several key areas:
 - Face/head: Temporal wasting, loss of the periorbital fat pads
 - Supraclavicular areas: Loss of muscle mass, increased prominence of clavicles with hollowing
 - Arms: Loss of muscle mass in the triceps/biceps areas, muscle wasting of the hand (hollowing of the space between index/thumb)
 - Legs: loss of quadriceps muscle mass (hollowing of the thigh just proximal to the knee), edema
 - Recognition and documentation is key
 - Sarcopenia is a valid diagnosis (ICD 10: M62.84)
 - BMI does not correlate with nutrition status!

Malnutrition Quality Improvement Initiative

- <https://malnutritionquality.org/resource-repository/>

- Under Resources for Implementing Quality Improvement
 - Malnutrition Recognition Guide
 - ASPEN Criteria
 - Nutrition Focus Physical Exam (with pictures!)
 - Clinical Care Workflow